

FOURIER ANALYSIS OF FACIAL SOFT TISSUE IN FRONTAL AND LATERAL VIEWS IN CLASS II MALOCCLUSION PATIENTS

Naseh R,¹ Ansari M,² Padisar P,³ Ghorbani S⁴

1. Associate Professor, Department of Orthodontics, Dental Caries Prevention Research Center, Qazvin University of Medical Sciences, Qazvin, IRAN.

2. Post Graduate Student, Department of Endodontics, Faculty of Dentistry, Qazvin University of Medical Sciences, Qazvin, IRAN.

3. Associate Professor, Department of Orthodontics, Dental Caries Prevention Research Center, Qazvin University of Medical Sciences, Qazvin, IRAN.

4. Post Graduate Student, Department of Radiology, Faculty of Medicine, Zanjan University of Medical Sciences, Zanjan, IRAN.

ABSTRACT

Aim: Orthodontic treatments are mainly performed to improve esthetics. This study aimed to assess sexual dimorphism in the frontal and lateral views of class II patients. Also, the facial soft tissue templates of the frontal and lateral views were drawn for each group.

Materials & Method: Using stereophotogrammetry, photographs were taken of the frontal and lateral views of 40 patients with class II div I and 30 patients with class II div II malocclusion in natural head position. Landmarks were identified on the face using visual and tactile sense and marked using fluorescent markers. A software was used for Fourier analysis. Size was standardized and the overall facial shape was evaluated. Templates were obtained using curves. Data were analyzed using SPSS version 22.

Results: The correlation coefficients of some Fourier series were correlated. The correlation of the original and reconstructed curves was 99% ($p < 0.05$). The mean coefficients for the frontal view was not equal in males and females ($p > 0.05$) while they were similar for the lateral view ($p < 0.05$). The mean coefficients were the same between class II div I and class II div II patients for the frontal view ($p < 0.05$) but were different for the lateral view ($p > 0.05$).

Conclusion: Sexual dimorphism was noted in facial frontal view but was not noted in their lateral view. No difference was noted in the frontal view of deviations while was significant for their lateral view.

Keywords: Class II Malocclusion, Facial Soft Tissue, Fourier Analysis, Stereophotogrammetry.

Introduction

Physical appearance affects social acceptance, mental health and self-confidence of individuals. Definition of beauty may vary according to race and ethnicity and is partly a subjective matter.^{1,2} Demand for an esthetic appearance has increased in the recent years, and orthodontic treatments, orthognathic surgeries and dental prosthetic treatments are extensively performed to improve esthetics.³ Improving facial esthetics is an important goal in orthodontic treatment for both patients and orthodontists.^{4,5}

In the early 20th century, orthodontic treatment plans were mainly based on extraction and non-extraction treatments aiming to obtain efficient and stable dental occlusion, and less attention was paid to correction of soft tissue in lateral and frontal views.⁶ Introduction of orthognathic surgeries highlighted the significance of facial symmetry.⁷ Dental clinicians and particularly orthodontists must be well acquainted with the principles of facial esthetics in order to be able to offer a treatment plan with special emphasis on soft tissue esthetics.³

Conventionally, the facial lateral view is often used to assess facial esthetics.^{6,9} However, attractiveness also relates to other factors not related to the facial profile such as hair style and form and color of the eyes.⁹ Success of orthodontic treatment highly depends on the improvement of facial esthetics after treatment. Thus, assessment of facial profile before and after orthodontic treatment is mandatory.

Facial skeleton and the overlying soft tissue are in harmony in shape and function. Facial soft tissue analysis according to photographic findings provides some information about facial morphology and its relation to the underlying skeletal structures.¹⁰

Soft tissue parameters are used in cephalometric analysis and several soft tissue analyses have been described based on photographic findings. First, a filter was used for soft tissue visualization; then, photographic records were used for soft tissue analysis and later the natural head position was employed for lateral and frontal analyses of the face.³

The correlation of hard and soft tissue is an interesting topic in orthodontics. In the recent years, more emphasis has been placed on the soft tissue for diagnosis and treatment planning since orthodontic treatment is mainly performed to improve esthetics and not only for the sake of establishing a correct relationship between the hard and soft tissues.^[10] Thus, soft tissue relations and the respective normal values should be determined. Soft tissue analysis of the facial lateral and frontal views and its relation to the underlying hard tissue comprises an important part of diagnosis and treatment planning in clinical orthodontics and orthognathic surgery. Several cephalometric analyses for the facial soft tissue in lateral and frontal views have been developed.^{11,12} Fourier analysis has been used for analysis of facial profile in some previous studies with respect to age, race and facial symmetry.¹³⁻²⁰ Also, Fourier analysis has been used in studies on

twins to find the effect of genetics and environment on facial morphology.^{19,20}

The available studies on facial lateral and frontal views are mainly based on two-dimensional (2D) photographs and cephalograms, which have limitations in landmark identification and accuracy of analyses. Also, the frontal and lateral facial views play a significant role in facial esthetics.

Fourier analysis is used for three-dimensional landmark identification using stereo photography and application of mathematical metric methods for facial lateral and frontal view soft tissue analyses. This method does not have the risks of radiation exposure, and enables fast analysis of photographs. Mathematical methods enable accurate analysis of facial changes.

This study aimed to identify landmarks three-dimensionally using stereo photography to analyze the facial soft tissue in lateral and frontal views in adult patients with class II malocclusion using Fourier analysis

Materials and Methods

This descriptive, cross-sectional study was conducted on 70 patients including 35 females and 35 males with class II malocclusion (40 patients with class II division I and 30 patients with class II division II). Photographs showing frontal and lateral views of patients were evaluated.

Of patients presenting to Qazvin Dental School, 40 patients with class II div I and 30 with class II div II were randomly selected such that there were 20 males and 20 females with class II div I and 15 males and 15 females with class II div II in the age range of 18 to 25 years. The inclusion criteria were as follows:

1. Adult patients with class II skeletal malocclusion with $ANB > 4^\circ$. Classification of patients into division 1 and 2 was based on the inclination of maxillary anterior teeth and the amount of overjet.
2. Absence of anterior or posterior cross-bite
3. No history of trauma or surgery in the craniofacial region
4. No history of previous orthodontic treatment
5. Absence of any craniofacial disorder

We used three digital cameras (A4-Tech, Shuttle) for this study. Since digital cameras cannot video tape simultaneously, a software was used for this purpose. In this software, photograph size was adjustable and adjusted to be 640 x 480 pixels.

Stereophotogrammetry was used in this study.^[21] The cameras were glued to a rail. The central camera was round in shape and the other two were rectangular. To determine the exact distance between the cameras, the

center of the lens of each camera was marked on the body of camera using a marker (Owner). A paper pointer was glued to the body of camera pointing to the rail and center of camera lens.

The body of metal rail was marked by a marker at 1 cm intervals. The rail length was 30 cm. The cameras could roll on the rail but they were fixed after determining their exact location. The distance between the lenses of each two cameras was determined to be 5 cm. The central camera was in line with the midline of the chair and tripod in the frontal view and in line with the N'/Pog' line in the lateral view. The two side cameras were also parallel to the central camera. The cameras were then fixed to prevent their superior-inferior movement.

The height of camera was adjusted based on the facial height. The distance between the posterior leg of the stool and posterior leg of the tripod was 127 cm. A full length mirror measuring 100x70 cm² was placed in front of the patient. The midline of the mirror was in line with the midline of the chair and tripod. Two blue cardboards were placed against the wall to serve as the background. [Figure 1]

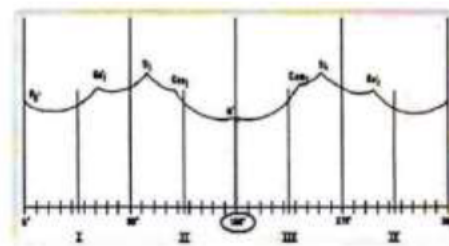


Figure 1. Open contour of the face obtained by connecting the landmarks; the x axis indicates the angle of vector and the y axis indicates the modulus of the vector or the distance from the center of gravity. In this figure, N' is the closest and Tr' is the farthest landmark from the center of gravity.

After identification of landmarks by visual and tactile examination with 0.1 mm accuracy, they were marked on the face with a black crayon pencil.^[3,9] Some fluorescent markers were then adhered to the center of each landmark for better visualization on photographs. These markers were florescent red and had a reflective property. They were available in two sizes: (A) round markers with 8 mm diameter for N' and Pog' used in the frontal view and (B) rectangular markers measuring 5 x 20 mm² for Go' and Tr' in the frontal view and N', Pog', ULA, LLA and B' in the lateral view. Rectangular markers were cut in L-shaped form such that the short arm of L was 5 mm and the long arm of L was 15 mm. A round marker was placed on the short arm for the purpose of standardization with the dimensions of the round markers. Since the location of

Canth' in the frontal view could be visually identified, this landmark was not marked by any marker.

Soft tissue landmarks were used in this study, which included N', Pog', Tr', Go' and Canth' for the frontal view and N', Pog', ULA, LLA and B' for the lateral view according to the following definitions.^{22,23}

N: The most prominent/anterior spot over the soft tissue covering the frontonasal suture; Pog': the most anterior spot on the soft tissue covering the menton on midsagittal plane; Tr': a cartilaginous prominence anterior to the external auditory meatus and Canth': the corner of the eye where upper and lower eyelids meet.

Before taking the photographs, the patient was requested to take a short walk and then sit upright on the chair with his soles on the ground. The vertebral column had to be completely upright. The patient was asked to gaze at his/her own pupils in the mirror measuring 100 x 70 cm² located at 2.5 m distance. All photographs were taken in natural head position, which has high reproducibility.

Fourier's analysis

The entire analysis was performed by the computer software. In the frontal view, first all landmarks were connected with lines to obtain a closed contour. Photographs were then standardized by use of identical pixel areas. The center of gravity of each photograph was identified and adapted to the center of x-y axes. Next, a total of 360 vectors were drawn from the center of gravity in counterclockwise fashion to reconstruct the face. [Figure 2]

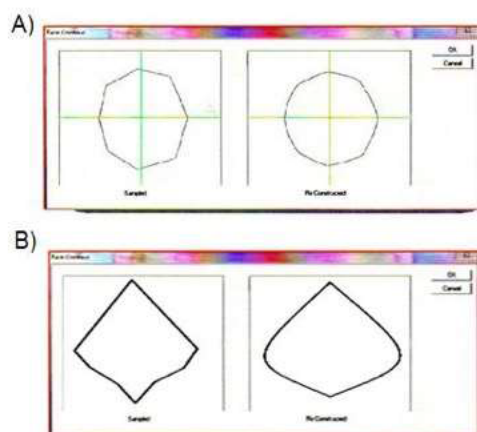


Figure 2. Facial shape contour: (A) frontal view (B) lateral view

Each vector was defined by its length and angle. The coordinates of steep and length of each vector with respect to the horizontal axis formed a curve on Cartesian scale $f(x, y)$ in which x and y indicated the length (modulus) and steep of each vector. [Figure 3]

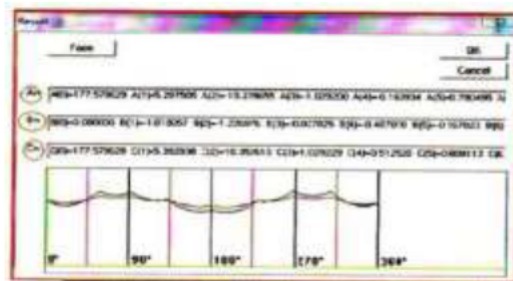


Figure 3: Results

The software performed Fourier analysis with $r=360$. The mathematical description of Fourier series was as follows. The formula was extended to the first 20 series and the succeeding series were disregarded due to high decimals. The sine (b_n), cosine (a_n) and domain (c_n) coefficients for the first 20 series of Fourier series were calculated for each photograph and the face shapes were reconstructed. [Figure 4]

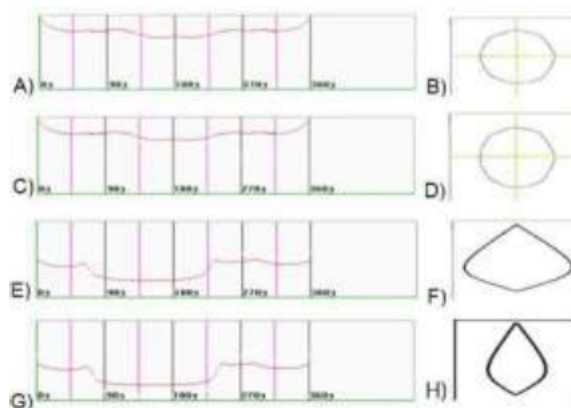


Figure 4: (A) Reconstructed and (B) closed curves for the frontal view template in class II div I patients (C) Reconstructed and (D) closed curves for the frontal view template in class II div II patients (E) Reconstructed and (F) closed curves for the lateral view template in class II div I patients (G) Reconstructed and (H) closed curves for the lateral view template in class II div II patients according to the mean length and steep of reconstructed vectors

$$f(x) = a_{0/2} + \sum_{n=1}^{20} (a_n \cos \theta_n x + b_n \sin \theta_n x)$$

N: Harmonic

a_n : Cosine coefficient of n^{th} harmonic.

b_n : Sine coefficient of n^{th} harmonic.

$$\theta : 2 \frac{\pi}{t}$$

t : Normalized lateral length.

$$f(x) = a_{0/2} + \sum_{n=1}^{20} (c_n \cos(\theta_n x + \phi_n))$$

$c_n = \sqrt{a_n^2 + b_n^2}$ Amplitude of the n^{th} harmonic

$\phi_n = \arctan(b_n/a_n)$ Phase of the n^{th} harmonic

Soft tissue Fourier analysis software

The x and y axes were drawn on photographs. The x axis on frontal view photographs passed the N'-Pog' line. Also, the y axis passed the external canthus of the eyes. The x axis on lateral view photographs passed the Pog'-N' line. The y axis passed the line connecting ULA and its corresponding point. The coordinates of each landmark were then determined by the computer.

Obtaining the lateral view and frontal view of facial soft tissue

The mean length and angle of the reconstructed vectors on the frontal and lateral views in both groups of class II div I and class II div II patients were determined and templates were obtained accordingly.

Data were analyzed using SPSS version 22 (SPSS Inc., IL, USA). Kolmogorov-Smirnov test was used to assess normal distribution of data. Data were analyzed using t-test and correlation regression.

Results

Kolmogorov-Smirnov test showed that the data were not normally distributed. T-test revealed that the correlation between the original and reconstructed curves in both the frontal and lateral views of patients with class II div I and class II div II malocclusion was 99% and this correlation was significant ($p < 0.05$). The difference in the mean of original and reconstructed curves was also significant ($p < 0.001$). In other words, the original and reconstructed curves were different and this difference was due to different sizes of the two curves.

View	Coefficient	Males		Females		p-value
		Mean	Standard Deviation	Mean	Standard Deviation	
Frontal	Mean a_n	13.133	1.068	12.553	0.511	0.038*
	Mean b_n	0.773	0.38	0.381	0.11	0.228
	Mean c_n	13.21	0.46	12.787	0.33	0.00*
Lateral	Mean a_n	6.28	1.871	6.66	0.70	0.86
	Mean b_n	-0.581	0.98	-0.533	0.33	0.883
	Mean c_n	11.185	2.37	8.78	1.804	0.265

*Statistically Significant

Table 1: Mean and standard deviation of Fourier coefficients for males and females with class II div I malocclusion in frontal and lateral views ($n=20$)

The mean of a and c coefficients in the frontal view of class II div I patients was significantly different between males and females [$p < 0.05$, Table 1]. This difference between males and females was not significant in the lateral view of class II div I patients [$p > 0.05$, Table 1]

The mean of b and c coefficients in the frontal view of class II div II malocclusion patients was significantly different between males and females [$p < 0.05$, Table 2] but this difference was not significant in their lateral view. [$p > 0.05$, Table 2]

View	Coefficient	Males		Females		p-value
		Mean	Standard Deviation	Mean	Standard Deviation	
Frontal	Mean a_n	11.964	0.87	12.274	0.94	0.081
	Mean b_n	0.021	0.21	0.145	0.12	0.011*
	Mean c_n	12.714	0.11	12.82	0.28	0.016*
Lateral	Mean a_n	6.677	3.802	6.79	4.74	0.87
	Mean b_n	-0.436	0.68	-0.507	1.24	0.25
	Mean c_n	8.96	4.6	9.144	4.537	0.683

*Statistically Significant

Table 2: Mean and standard deviation of Fourier coefficients for males and females with class II div II malocclusion in frontal and lateral views ($n=15$)

Correlation of curves in patients with class II div I and class II div II malocclusion

The mean of coefficients in the frontal view was not significantly different between class II div I and class II div II patients [$p > 0.05$, Table 3] but the mean of a and c coefficients was significantly different in the lateral view of class II div I and class II div II patients. [$p < 0.05$, Table 3]

View	Coefficient	Class II div I		Class II div II		p value
		Mean	Standard Deviation	Mean	Standard Deviation	
Frontal	Mean a_n	6.50	3.38	6.68	2.88	0.506
	Mean b_n	-0.551	1.706	-0.503	2.026	0.386
	Mean c_n	8.88	6.37	8.96	3.614	0.767
Lateral	Mean a_n	12.67	0.522	12.263	0.422	0.003*
	Mean b_n	0.04	0.148	0.062	0.104	0.52
	Mean c_n	12.99	0.308	12.714	0.215	0.00*

* Statistically Significant

Table 3: Mean and standard deviation of Fourier coefficients in the lateral and frontal views of class II div I and class II div II patients ($n=40$ for class II div I and $n=30$ for class II div II patients)

Soft tissue template

Figures 6-9 show the reconstructed and closed curves for the frontal and lateral view templates of class II div I and class II div II patients according to the mean length and steep of reconstructed vectors.

Discussion

This study aimed to introduce a new method for reconstruction of facial soft tissue contour using the Fourier series. This method was similar to those described by Lu,²⁴ Lestrel *et al.*,²⁵ and Ferrario *et al.*,^{14,26-28} with the difference that our method was computerized. We also assessed the effect of gender on facial soft tissue closed contour and the difference in this regard in the frontal and lateral views of patients with class II div I and class II div II malocclusion.

Our results showed that the correlation between the original and reconstructed curves in the frontal and lateral views was 99% in class II div I and class II div II patients, which was similar to the findings of Ferrario *et al.*,¹⁴ Siddik *et al.*,⁷ and Fernandez-Riveiro *et al.*³ According to Lu,²⁴ the minimum acceptable correlation coefficient is 0.6. In our study, the correlation coefficient between the reconstructed and original curves in the frontal and lateral views in class II malocclusion patients was 0.9, which, according to Lu,²⁴ is acceptable.

One advantage of the classic Fourier series is the geometric definition of the coefficients of harmony. The numerical difference in the Fourier coefficients is due to the presence of actual difference in morphology¹⁴ such that the cosine coefficient of a_0 indicates the size of one form. In the current study, the size was standardized so it was the same in all patients. The first sentence is a circle shifted towards the maximal surface area such that it only shows the overall shape of the face with no details. As sentences are further added, more details are added to the picture and it better resembles the original shape of the face.²⁴ Size is a confounding factor in morphological analyses. However, most analyses are carried out in patients with significant differences in size.¹⁴ In case of presence of differences in size, the existing differences in shape cannot be revealed. Using Fourier analysis, differences in size can be fixed and the independent role of shape and size in determination of the final morphology can be determined. Since the conventional metric methods cannot independently determine the role of shape and size, ranging is used to control for the differences in size. However, this method is not useful and interpretation of results is difficult.¹⁴ To determine the difference in form, some measures (such as width/length ratio) are used, which can be a combination of different measurement methods.¹⁴ The

Fourier analysis indicates the overall morphology of the contour of a shape and since normalized coefficients of Fourier series are constant in terms of direction, size and location, the shape is analyzed in actual form.¹⁴ In the current study, the size was standardized by dividing all coefficients by a constant value (25,000 pixels), which was in line with the studies by Ferrario *et al.*,¹⁴ Siddik *et al.*,⁷ and Fernandez-Riveiro *et al.*,³ with the difference that, the constant value used in their studies was different from ours due to the difference in type of imaging.^{3,7} In the current study, in the frontal view, the x axis was vertical and in line with the mid-sagittal plane, which was in agreement with the studies by Ferrario *et al.*,¹⁴ and Lu.²⁴ In this method, a number of landmarks can be used. The higher the number of landmarks, the more accurate the outline of the form would be. But, calculations are independent of the number of landmarks. The only existing limitations are biological limitations such as significance and exclusive definition of landmarks.^{14,24} According to Lu,²⁴ the minimum acceptable correlation coefficient between the reconstructed and original curves is 0.6; accordingly, our results showed 99% correlation. Thus, number of selected landmarks was sufficient in our study. This finding was in accord with that of Ferrario *et al.*,¹⁴ Siddik *et al.*,⁷ and Fernandez-Riveiro *et al.*,³ in terms of the number of chosen landmarks and presence of 99% agreement between the two curves.

In patients chosen for our study, the facial soft tissue shape in the frontal view was significantly different between males and females, which was similar to the results of Halazonetis.^{10,26,27} Moreover, these findings were in accordance with the sexual dimorphism reported in other studies using 2D conventional analysis.^{7,10,14,22,29-30}

In patients chosen for our study, the facial soft tissue shape in the lateral view was not significantly different between males and females, which was in agreement with the results of Siddik *et al.*⁷ This result was in contrast to the sexual dimorphism reported in other studies using 2D conventional analysis.^{7,10,14,22,29-30}

Difference between our results and those of previous 2D studies regarding the lateral view may be attributed to three reasons; first, in the current study, we did not consider a landmark for the nose due to the high frequency of rhinoplasty in our patients. Difference between males and females in previous studies was mainly due to the difference in nasal angles. The second reason is that previous studies used conventional measurement methods and thirdly, they did not perform comprehensive statistical analysis.^{7,14,22,29-30}

The results of our study using Fourier analysis can be different from those of studies using 2D lateral and

posterior-anterior photographs and radiographs due to two types of errors:¹⁴ errors during photography and errors in identification of landmarks. The 2D studies in the frontal and lateral planes were conducted without using actual landmarks. They did not pay attention to the change in head direction of patients and identified landmarks on 2D photographs. To overcome this problem in the current study, we identified landmarks on the face of patients, similar to what was done by Ferrario *et al.*¹⁴

In general, results of 2D and 3D studies cannot be directly compared even if similar landmarks are used under the same conditions. In our study, no significant difference was noted between class II div I and class II div II patients; while in the lateral view, a significant difference was noted between class II div I and class II div II patients in this respect; these findings can be explained by the difference between class II div I and class II div II malocclusions in overjet and angulation of maxillary central incisors relative to the Frankfurt plane and angle of mandibular central incisors relative to the mandibular plane. However, difference between class II div I and class II div II malocclusions has not been evaluated in previous studies.

Since significant correlations were noted between a_n and b_n in class II malocclusion patients, these correlations can be used in future studies for the comparison of different malocclusions. Also, Fourier analysis can be used for evaluation of gender distribution in patients with a specific type of malocclusion or skeletal or esthetic problems. Future studies are required to use Fourier analysis for class I and class III patients. Also, further studies are required to offer general templates for the shape of the face in the frontal and lateral views in patients with different types of malocclusions.

Conclusion

Within the limitations of this study, the results showed sexual dimorphism in the frontal view of class II malocclusion patients in their soft tissue closed contour. No sexual dimorphism was noted in soft tissue closed contour of the lateral view of class II malocclusion patients. No significant difference was noted in frontal view of class II div I and div II patients while this difference was significant in their lateral view.

Reference

1. Haskell BS, Segal ES. Ethnic and ethical challenges in treatment planning: dealing with diversity in the 21st century. *Angle Orthod* 2014;84(2):380-2.
2. de Carvalho Barbosa PB, Santos PL, De Carli JP, Luiz de Freitas PH, Pithon MM, Paranhos LR.

- Aesthetic facial perception and need for intervention in laterognathism in women of different ethnicities. *J Craniomaxillofac Surg* 2017;45(10):1600-6.
3. Fernández-Riveiro P, Smyth-Chamosa E, Suárez-Quintanilla D, Suárez-Cunqueiro M. Angular photogrammetric analysis of the soft tissue facial profile. *Eur J Orthod* 2003;25(4):393-9.
4. Kallidass P, Srinivas S, Charles A, Davis D, Sushil Charravarthi NC. Smile characteristics in orthodontics: A concept review. *Int J Orofac Res* 2017;2(1):1-4.
5. Turley PK. Evolution of esthetic considerations in orthodontics. *Am J Orthod Dentofacial Orthop* 2015;148(3):374-9.
6. Milutinovic J, Zelic K, Nedeljkovic N. Evaluation of facial beauty using anthropometric proportions. *ScientificWorld Journal* 2014;2014:428250.
7. Malkoç S, Demir A, Uysal T, Canbuldu N. Angular photogrammetric analysis of the soft tissue facial profile of Turkish adults. *Eur J Orthod* 2009;31(2):174-9.
8. Manevska I, Pavlic A, Katic V, Trinajstić Zrinski M, Drevensek M, Spalj S. Satisfaction with facial profile aesthetics: are norms overrated? *Int J Oral Maxillofac Surg* 2018;47(1):72-8.
9. Tole N, Lajnert V, Kovacevic Pavicic D, Spalj S. Gender, age, and psychosocial context of the perception of facial esthetics. *J Esthet Restor Dent* 2014;26(2):119-30.
10. Halazonetis DJ. Morphometric evaluation of soft-tissue profile shape. *Am J Orthod Dentofacial Orthop* 2007;131(4):481-9.
11. Choi JW, Lee JY, Oh TS, Kwon SM, Yang SJ, Koh KS. Frontal soft tissue analysis using a 3 dimensional camera following two-jaw rotational orthognathic surgery in skeletal class III patients. *J Craniomaxillofac Surg* 2014;42(3):220-6.
12. Gage CC, Elo JA, Sun HH, McClendon GD, Azevedo B, Henson BS. Comparison of facial morphometric analysis using CBCT volumetric rendering and digital photography. *J Oral Maxillofac Surg Med Pathol* 2016;28(3):210-4.
13. Ferrario VF, Sforza C, Miani A, Poggio CE, Schmitz J. Harmonic analysis and clustering of facial profiles. *Int J Adult Orthodon Orthognath Surg* 1992;7(3):171-9.
14. Ferrario VF, Sforza C, Schmitz JH, Miani A Jr, Taroni G. Fourier analysis of human soft tissue facial shape: sex differences in normal adults. *J Anat* 1995;187(Pt 3):593-602.
15. Ferrario VF, Sforza C, Guazzi M, Montorsi F, Taroni A. Effect of growth and development on human soft tissue facial shape: a Fourier analysis. *Int J Adult Orthodon Orthognath Surg* 1996;11(2):155-63.

16. Ismaniati N. Lateral facial profile assessment: a comparison of Fourier analysis with traditional cephalometric methods. *Aust Orthod J* 1999;15:11.
17. Kapur KK, Lestrel PE, Garrett NR, Chauncey HH. Use of Fourier analysis to determine age-related changes in the facial profile. *Int J Prosthodont* 1990;3(3):266-73.
18. Sheridan CS, Thomas CD, Clement JG. Quantification of ethnic differences in facial profile. *Aust Orthod J* 1997;14(2):218-24.
19. Tangchaitrong K, Messer LB, Thomas CD, Townsend GC. Fourier analysis of facial profiles of young twins. *Am J Phys Anthropol* 2000;113(3):369-79.
20. Vanco C, Kasai K, Sergi R, Richards LC, Townsend GC. Genetic and environmental influences on facial profile. *Aust Dent J* 1995;40(2):104-9.
21. Vossoghi M, Padisar P, Vosooghi M, Vossoghi M, Mohammadi Z. Fourier analysis of soft tissue facial shape in subjects with class I malocclusion using a new software. *IOSR-J Dent Med Sci* 2016;15(6):85-90.
22. Magnani MB, Nouer DF, Nouer PR, Pereira Neto JS, Garbui IU, Böeck EM. Assessment of the nasolabial angle in young Brazilian black subjects with normal occlusion. *Braz Oral Res* 2004;18(3):233-7.
23. Emre IE, Aksoy E, Ünal OF. Angiolymphoid hyperplasia with eosinophilia of the maxillary sinus and orbit. *Eur J Gen Med* 2017;14(4):116–118
24. Oncel-Acir N, Solmaz H, Cetinkaya S, Savas C, Dadaci Z, Borazan M. Herpes zoster infection after an uncomplicated cataract surgery: A case report. *Eur J Gen Med* 2017;14(4):114–115
25. Lestrel PE, Kimbel WH, Prior FW, Fleischmann ML. Size and shape of the hominoid distal femur: fourier analysis. *Am J Phys Anthropol* 1977;46(2):281-90.
26. Leung CS, Yang Y, Wong RW, Hägg U, Lo J, McGrath C. Angular photogrammetric analysis of the soft tissue profile in 12-year-old southern Chinese. *Head Face Med* 2014;10:56.
27. Ajami S, Zarif Najafi H, Mahdavi S. Angular Photogrammetric Analysis of the Soft Tissue Facial Profile of Iranian Young Adults. *Iran J Ortho* 2015;10(2):e4981.
28. Reddy M, Ahuja NK, Raghav P, Kundu V, Mishra V. A computer – assisted angular photogrammetric analysis of the soft tissue facial profile of north indian adults. *J Indian Orthod Soc* 2011;45(3):119-23.
29. Coskun A, Ozkan F, Ozbay S, Okur OM, Kayipmaz AE, Gulunay B, Eren SH, Ucar A, Kavalci C. Cyanide ingestion. *Eur J Gen Med* 2017;14(4):111–113.
30. Dimaggio FR, Ciusa V, Sforza C, Ferrario VF. Photographic soft-tissue profile analysis in children at 6 years of age. *Am J Orthod Dentofacial Orthop* 2007;132(4):475-80.

Corresponding Author

Mohamadreza Ansari

Post Graduate Student,

Faculty of Dentistry,

Department of Endodontics,

Qazvin University of Medical Sciences,

Qazvin, Iran.

Email: drmra1365@gmail.com