

# MALIGNANT PERIPHERAL NERVE SHEATH TUMOR OF MANDIBLE IN A YOUNG FEMALE – A CASE REPORT

Masood Hasan Khan,<sup>1</sup> Kausar J Khwaja,<sup>2</sup> Nasir Ahmed Salati,<sup>3</sup> Minhaj Anwar<sup>4</sup>

<sup>1</sup> & <sup>3</sup> Assistant Professor, Department of Oral Pathology & Oral Medicine, Dr. Z.A. Dental College, Aligarh, Uttar Pradesh

<sup>2</sup> Associate Professor, Department of Oral Pathology & Oral Medicine, Dr. Z.A. Dental College, Aligarh, Uttar Pradesh

<sup>4</sup> Tutor, Department of Oral Pathology & Oral Medicine, Dr. Z.A. Dental College, Aligarh, Uttar Pradesh

## Abstract

Malignant Peripheral Nerve Sheath Tumor (MPNST) as per the WHO definition corresponds to malignant transformation of Schwann cell, perineural fibroblast or endoneural fibroblast. These tumors are common in neurofibromatosis, however may uncommonly arise denovo. Common sites includes extremities and trunk, uncommonly involves head and neck area (10-12%). Involvement of maxilla or mandible is rare. These tumors need to be differentiated from other sarcomas because foci of differentiation of other mesenchymal elements is a common finding in both.

**Key words:** Neurofibromatosis, Malignant Peripheral Nerve Sheath Tumor, World Health Organization.

## Introduction

Malignant peripheral nerve sheath tumor is a sarcoma arising from Schwann cell, perineural fibroblast or endoneural fibroblast of nerves or nerve trunks, usually extremities and trunk. Involvement of head and neck region varies 10-12% to 10-15% according to literature<sup>1,2,3</sup>. Most cases of MPNST in head and neck region arise in Von Recling Hausen disease<sup>4,5,6</sup>. Involvement of bone of head and neck region is rare. Very few cases of MPNST of mandible unassociated with NF have been reported<sup>2</sup>. Histopathologically this tumor shows sweeping fascicles of cells with indistinct cytoplasmic borders and several mitotic figures, occasionally anaplastic cells may be seen. Divergent differentiation in the form of other mesenchymal element has also be reported, thus necessitating differentiation from other sarcomas.<sup>3,6,7,8,9</sup>

We report the clinical representation and brief management of a young female with MPNST of mandible.

## Case report

A sixteen year Muslim female presented with diffuse swelling of mandible, associated with pain for the past six months. There was no history of radiation, previous surgery or neurofibromatosis. (Figure 1)

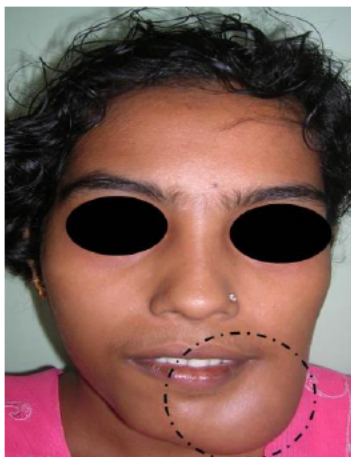


Figure 1: Showing diffuse swelling and obvious facial asymmetry.

On local examination gross facial asymmetry was seen, with a firm to hard diffuse swelling measuring 7 x 6 x 5 cm, tender, extending from the left mandible to right side of symphysis menti. (Figure 2)

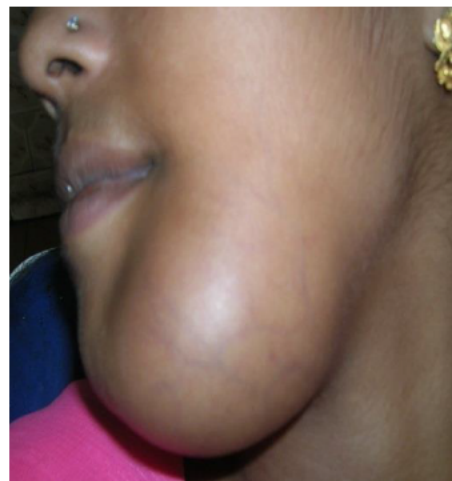

Figure 2: Localized firm swelling extending from left mandible to right symphysis menti

Intra oral examination reveals significant expansion of buccal cortical plates and a carious first molar. (Figure 3)

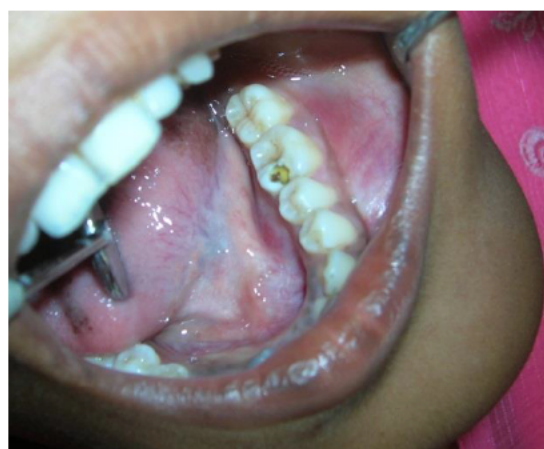

Figure 3: Reveals expansion of buccal cortical plates.

On general examination there were no sign and symptoms of neurofibromatosis.

X-ray (OPG) revealed an extensive lytic lesion leading to expansion and destruction of buccal and lingual cortex extending to parasymphyseal region with regional tooth resorption and loss of inferior border of mandible. (Figure 4)

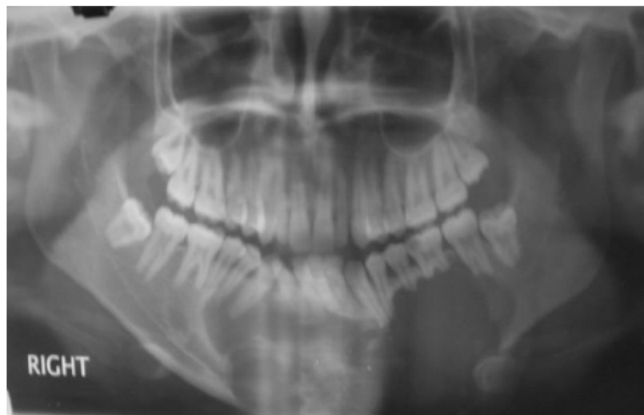

Figure 4: OPG revealed an extensive lytic lesion with destruction of buccal and lingual cortical plates and loss of inferior border of mandible

#### Histopathology

Trucut biopsy was suggestive of sarcoma, operated specimen measured 9.5 x 8 x 7 cm irregular, nodular growth infiltrating and destroying the mandible. Resected margins were clear.

Microscopy revealed fusiform spindle cells arranged in fascicles, with indistinct cytoplasmic borders and several mitotic figures (8 -10/10hpf). (Figure 5)

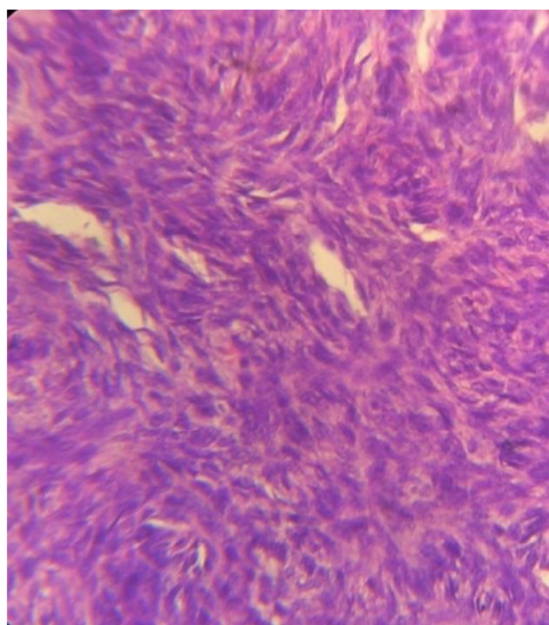


Figure 5: Microscopy reveals fusiform spindle cells arranged in fascicles, with indistinct cytoplasmic borders and several mitotic figures (8 -10/10hpf)

Foci of necrosis were also present. Other mesenchymal components, like cartilage, were not seen. Immunohistochemistry was positive for s-100 (Figure 6), vimetin, however cytokeratin panel was negative. Thus with the above histopathological description a diagnosis of MPNST was confirmed.

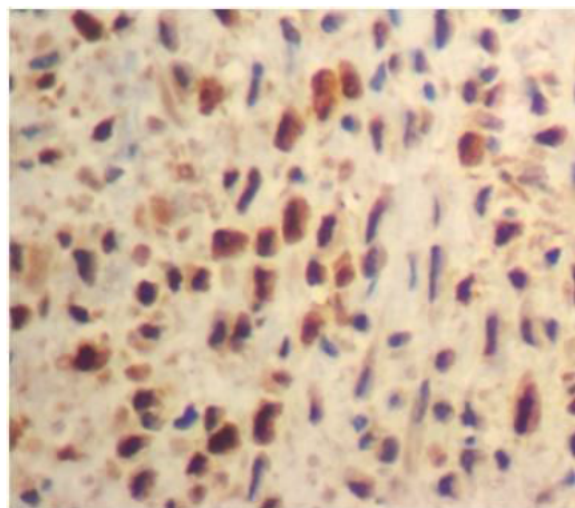


Figure 6: Immunohistochemistry panel was positive for s-100

Surgical segmental resection and fibular grafting was followed by post operative radiation owing to large size and brisk mitotic rate. MPNSTs as documented by the World Health Organization are a type of soft tissue sarcomas arising from a peripheral nerve or depicting a nerve sheath differentiation, with the exception of tumors originating from the epineurium or the peripheral nerve vasculature. It can arise de-novo or simply from dedifferentiation within a preexisting neurofibroma in patients with neurofibromatosis type 1 (NF-1).<sup>6</sup> In around 10% of the cases MPNST can arise due to radiation at that site.<sup>10</sup> Most of MPNSTs are seen between 20 and 50 years of age and in equal frequency in both the gender.<sup>11</sup> MPNST mostly are seen originating from major nerve trunks like the sciatic nerve, brachial plexus and sacral plexus.<sup>8</sup> That's why the most common locations are the extremities and the trunk; head and neck involvement is seen in only 10- 15% of cases.<sup>2</sup> In head and neck area it occur mainly in the parotid gland or the infratemporal fossa.<sup>11</sup> MPNST arising in the mandible is very uncommon, and fewer than 50 cases of a mandibular involvement have been reported in the literature.<sup>11</sup> Magnetic resonance imaging is the investigation of choice as it can reveal the origin of the nerve and its position in relation to adjacent structures.<sup>11</sup> Contrast enhanced CT is inferior to MRI in revealing the origin from the nerve but can show the erosion of the mandible and enlargement of the mandibular canal.

The main problem in a head and neck MPNST is to attain adequate negative margins with surgery. The overall treatment approach is the same as that of other soft tissue sarcomas. Adjuvant radiotherapy is indicated because of

the high incidence of local recurrence and also depending upon the grade and size of tumor.

#### References

1. Enzinger FM, Weiss SW. Malignant Tumors Of Peripheral Nerves. In: Enzinger FM, Weiss SW, Editors. Soft tissue tumors. St. Louis: Mosby-year book; 1995. p. 889-928
2. Patil K, Mahima VG, Ambika L. Malignant peripheral nerve sheath tumour: an elusive diagnosis. *Indian J Dent Res* 2007;18(1):19-22.
3. Shyma PS, Gangothri S, Reddy KS, Basu D, Ramkumar A. Malignant peripheral nerve sheath tumor of mandible: A case report and review of literature. *J Neurol Res* 2011;1(5):219-222.
4. Colmenero C, Rivers T, Patron M, Sierra I, Gamallo C. Maxillofacial malignant peripheral nerve sheath tumors. *J Craniomaxillofac Surg*. 1991;19(1):40-60.
5. Kar M, Deo SV, Shukla NK, Malik A, Datta Gupta S, Mohanti BK et al. Malignant peripheral nerve sheath tumors (MNSPT)- clinicopathological study and treatment outcome of twenty-four cases. *World J Surg Oncol* 2006;4:55.
6. Ducatman BS, Scheithauer BW, Piepgras DG, Reiman HM, Ilstrup DM. Malignant peripheral nerve sheath tumors. A clinicopathologic study of 120 cases. *Cancer* 1986;57(10):2006-2021.
7. Ferner RE, Gutmann DH. International consensus statement on malignant peripheral nerve sheath tumors in neurofibromatosis. *Cancer Res*. 2002;62(5):1573-1577.
8. Ghosh BC, Ghosh L, Huvos AG, Fortner JG. Malignant Schwannoma. A clinicopathologic study. *Cancer* 1973;31(1):184-190.
9. Weiss SW, Langloss JM, Enzinger FM. Value of s-100 protein in diagnosis of soft tissue tumors with particular reference to benign and malignant Schwann cell tumors. *Lab Invest* 1983;49(3):299-308.
10. Ducatman BS, Scheithauer BW. Postirradiation neurofibrosarcoma. *Cancer* 1983;51(6):1028-1033.
11. Chhabra A, Soldatos T, Durand DJ, Carrino JA, McCarthy EF, Belzberg AJ. The role of magnetic resonance imaging in the diagnostic evaluation of malignant peripheral nerve sheath tumors. *Indian J Cancer* 2011;48(3):328-334.

#### Corresponding Author

Dr. Masood Hasan Khan  
Assistant Professor  
Department of Oral Pathology & Oral Medicine  
Dr. Z.A. Dental College,  
Aligarh Muslim University, Aligarh  
Uttar Pradesh, INDIA  
Email: - masood9903869359@gmail.com