

## An Interdisciplinary Approach in the Management of Endodontic – Periodontal Lesion: Report of 2 Cases

Saras Mediratta,<sup>1</sup> Deepa D<sup>2</sup>

### Abstract

The term endodontic-periodontal lesions have been used to describe lesions due to inflammatory products found in varying degrees in both pulp and periodontal tissues. These tissues share common embryonic derivation, vasculatures, lymphatic, neural pathways and microflora. As the tooth matures and the root is formed, three main avenues are created between pulp and periodontal ligament, i.e. dentinal tubules, lateral and accessory canals, and apical foramen. These are the pathways that may provide a means by which pathological agents pass between the pulp and periodontium, thereby creating the endo-perio lesion. Lateral canals play an important role in the spread of microbial products from pulp to periodontium. This paper reports two cases with a primary endodontic lesion with secondary periodontal involvement and their management by an interdisciplinary approach.

**Key Words:** - Endo-Perio Lesion, Accessory Canals, Pulpal Pathology

### Introduction

Pulpal and periodontal problems are responsible for more than 50% of tooth mortality.<sup>1</sup> It has been hypothesized that irritants may be transmitted between the pulpal and the periodontal structure. The juxtaposition of these tissues creates an intimate relationship. The apical foramen is the most important but by no means the only location where these tissues meet. Lateral and accessory canals, mainly in the apical area and in the furcation of molars, also connect the dental pulp with the periodontal ligament. In addition, a great number of dentinal tubules extend from the pulp to the cementum. Pashley DH (1988) suggested that development of cytotoxic changes in the dental pulp is due to permeability of dentin and it interacts in different ways with a variety of solutes as they diffuse across dentine.<sup>2</sup>

The various etiologic factors for the progression of disease are bacteria, fungi, viruses as well as trauma, root resorption and dental malformations.<sup>3</sup>

The most commonly followed classification of the endodontic-periodontal lesions is the one given by Simon and Colleagues<sup>4</sup> in the year 1972.

Accurate diagnosis and proper treatment plays a very crucial role for the success of the treatment. In our cases the diagnosis was primary endodontic lesion with secondary periodontal involvement. The treatment plan consisted of endodontic treatment first. The treatment results were evaluated for one month and then the periodontal flap surgery was performed.

### Case Report

#### CASE 1:

A 45 year old male patient reported to the department of periodontics with the chief complaint of pain in the lower left back tooth region since 2 months. On intraoral examination the tooth 36 was found to be carious and tender on percussion. There was a sudden drop of periodontal probe indicating a deep periodontal pocket of 10mm (Figure 1a). On radiographic examination there was evidence of bone loss on the distal root and the furcation area (Figure 1b). Thus a diagnosis of primary endodontic

lesion with secondary periodontal involvement was established.

Local anaesthesia was achieved by inferior alveolar nerve block of lidocaine HCl 2% with epinephrine 1:80,000. Access was achieved using a round diamond bur. The pulp chamber was opened, the canal was located and working length determined radiographically. Cleaning and shaping was initiated using the crown-down technique using hand pro-tapers (Dentsply-Maillefer, Ballaigues, Switzerland). Inter-appointment dressing of calcium hydroxide was given. In the second appointment, as the subjective symptoms were relieved all canals were obturated using gutta-percha (Figure 1c).

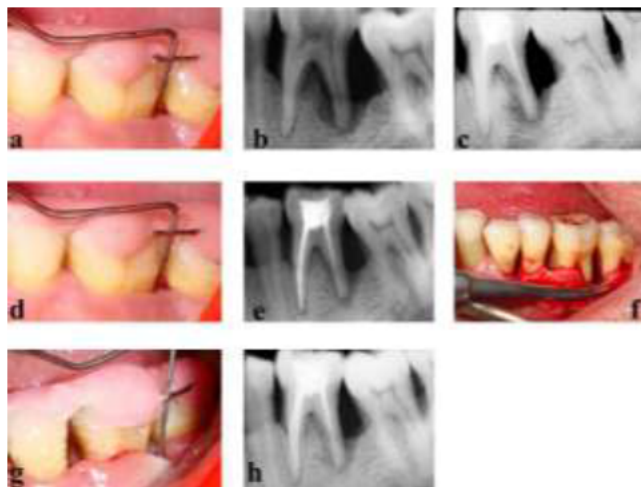


Figure 1: - Pictorial Description of Case 1

The post RCT follow-up after 1 month revealed no change in the probing depth (Figure 1d) although the radiographic changes of resolution of the lesion were evident (Figure 1e). At this stage the periodontal flap surgery was done. After injecting local anaesthesia (Xylocaine Hydrochloride 2% with 1:80,000 adrenaline), at the site of surgery, sulcular incisions were made and mucoperiosteal flap raised to retain sufficient tissue and to obtain primary closure. The defects were thoroughly debrided and root planed with hand and ultrasonic scalers and flap was

repositioned using non-resorbable black silk 3-0 sutures using interrupted suturing technique (Figure 1f).

Amoxicillin 500 mg three times daily for 5 days and ibuprofen 400 mg three times daily for 5 days were prescribed to the patient and he was recalled after 3 months. On this recall visit substantial reduction in probing depth was noticed. The probing depth was 6mm on the distal root surface (Figure 1g) with appreciable amount of bone formation (Figure 1h).

#### **CASE 2:**

A 38 year old female patient reported to the department of periodontics with the chief complaint of pain in the lower left back tooth region since 15 days. On intraoral examination the tooth 36 was found to be carious and tender on percussion. Grade I mobility was detected in this particular tooth and a periodontal pocket of 9 mm on the distal surface was noted (Figure 2a). On radiographic examination there was evidence of bone loss on the distal root surface (Figure 2b). Thus a diagnosis of primary endodontic lesion with secondary periodontal involvement was established.

The same procedure for root canal therapy was followed as with the case 1 (Figure 2c).

The post RCT follow up after 1 month revealed a change in the probing depth to 7mm (Figure 2d) and the radiographic changes of resolution of the lesion were evident (Figure 2e). At this stage the periodontal flap surgery was done. After injecting local anaesthesia (Xylocaine Hydrochloride 2% with 1:80,000 adrenaline), at the site of surgery, sulcular incisions were given and full thickness flaps were raised to retain sufficient tissue and to obtain primary closure. The defects were thoroughly debrided and root planed with hand and ultrasonic scalers and flap was repositioned using non-resorbable black silk 3-0 sutures using interrupted suturing technique (Figure 2f). Amoxicillin 500 mg three times daily for 5 days and ibuprofen 400 mg three times daily for 5 days were prescribed to the patient and he was recalled after 3 months. On this recall visit substantial reduction in probing depth was noticed. The probing depth was 2mm on the distal root surface (Figure 2g) with appreciable amount of bone formation (Figure 2h).

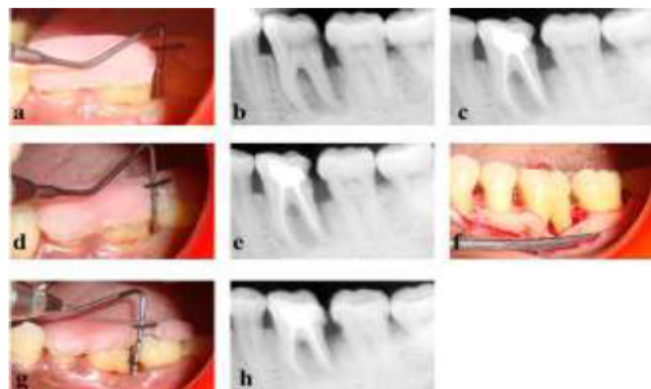


Figure 2: - Pictorial Description of Case 2

#### **Discussion**

The cases of primary endodontic lesion with a secondary involvement of periodontal tissue were treated with an interdisciplinary approach. In both the cases the tooth was carious involving the pulp. Conventional radiographs showed radiolucency in the distal root as well as in the furcation area involving the periapical region. Hence scaling was performed and endodontic treatment was completed. Then the patient was recalled after 1 month for re-evaluation. During this evaluation period of case 1 and case 2, there was a persistent pocket of 10mm and 7mm respectively in mesial aspect of 36, even after root canal treatment. This confirmed the secondary periodontal involvement along with primary endodontic component.

The lateral canals play an important role in spread of the infection from pulp to periodontal tissues. There are many studies where they have shown that accessory canals in root are more common in molars. Bender and Seltzer in 1972 confirmed the presence of more number of lateral and accessory canals in the bifurcation and trifurcation region of molars.<sup>5</sup> DeDeus in 1975 found that 17% of teeth had lateral canals in the apical third of the root, about 9% in the middle third, and less than 2% in the coronal third. However, it seems that the prevalence of periodontal disease associated with lateral canals is relatively low.<sup>6</sup> Since there was a persistent pocket at 1 month recall visit, periodontal flap surgery was done in both the cases.

At four month visit of patients there were no symptoms of any pain or discomfort noticed. On examination the pocket was reduced from 10mm to 6mm in case 1 and from 9 mm to 2mm in case 2 and on radiographs an appreciable amount of bone fill was detected. In primary endodontic disease with secondary periodontal involvement management should begin with endodontic therapy. Treatment results should be evaluated in 1-2 months and only then should periodontal treatment be considered. This sequence of treatment allows sufficient time for initial tissue healing and better assessment of the periodontal condition.<sup>7</sup> In this case we observed a reduction in probing depth from 10mm to 6mm in case 1 and from 9 mm to 2 mm in case 2 in four months with a significant radiographic bone fill.

#### **Conclusion**

These case reports demonstrate the nature of periodontal lesion as a secondary involvement to an originally endodontic lesion and their successful management by interdisciplinary approach. Further, it demonstrates emphasis on the significance of early diagnosis of endo-perio lesions.

#### **References**

1. Hiatt WH. Pulpal periodontal disease. *J Periodontol* 1977; 48:598-609.
2. Pashley DH. Consideration of dentine permeability in cytotoxicity testing. *Int Endod J* 1988; 21:143-154.

3. Rotstein I, Simon JHS. Diagnosis, prognosis and decision-making in the treatment of combined periodontal-endodontic lesions. *Periodontol* 2000 2004; 34:165-203
4. Simon JHS, Glick DH, Frank AL. The relationship of endodontic-periodontic lesions. *J Periodontol* 1972; 43:202-8.
5. Bender IB, Seltzer S. The effect of periodontal disease on the pulp. *Oral Surg Oral Med Oral Pathol* 1972; 33:458-474.
6. De Deus QD. Frequency, location and direction of the lateral, secondary, and accessory canals. *J Endod* 1975; 1: 361–366.
7. Paul BF and Hutter JW. The endodontic-periodontal continuum revisited: new insights into etiology, diagnosis and treatment. *J Am Dent Assoc* 1997; 128:1541-1548.

**Corresponding Author**

Dr. Saras Mediratta

E-mail: [drsaras1984@gmail.com](mailto:drsaras1984@gmail.com)