

# MANAGEMENT OF PEDIATRIC MANDIBULAR PARASYMPHYSEAL FRACTURE WITH ACRYLIC CLOSED CAP SPLINT: A CASE REPORT

Jain P,<sup>1</sup> Yeluri R,<sup>2</sup> Gupta S,<sup>3</sup> Lumbini P<sup>4</sup>

1. Post Graduate Student, Department of Pedodontics & Preventive Dentistry, TMDCRC, Moradabad, UP
2. Professor & Head, Department of Pedodontics & Preventive Dentistry, TMDCRC, Moradabad, UP
3. Senior Lecturer, Department of Pedodontics & Preventive Dentistry, TMDCRC, Moradabad, UP
4. Senior Lecturer, Department of Pedodontics & Preventive Dentistry, TMDCRC, Moradabad, UP

## Abstract

Dental trauma in children constitutes a major and serious dental public health problem. Fractures in the mandibular region can be detected through palpation, or by observing functional alterations. Bruises and swellings in the soft tissue region also can indicate the presence of a fracture. The diagnosis should be confirmed by panoramic radiographs, by posteroanterior mandible radiographs and by localized radiographs of the affected region.

A 8 year old boy reported injury to oral and perioral region. Child had swelling on the right parasymphiseal region and deviation of face towards right side with limited mouth opening difficulty in mastication and speaking with sublingual hematoma and step deformity and spacing is present in between 83 and 84. Timely treatment was done with acrylic closed cap splint appliance.

Mandibular fractures in children most commonly occur in condylar region, followed by parasymphysis and angle. The fractures tend to be minimally displaced and in majority of cases can be treated conservatively. Cap splints for treatment of pediatric mandibular parasymphysis reliable fixation techniques

**Key words:** Cap-splint, Fracture, Parasymphysis

## Introduction

Dental trauma in children constitutes a major and serious dental public health problem.<sup>1</sup> There is no single dental disturbance that has greater psychological impact on both parents and child than the child's facial esthetic.<sup>2</sup> Trauma in primary teeth can result in pain and affect the development of the permanent dentition. The most common effects on the permanent successors are defects in mineralization or tooth morphology, changes in colouration and enamel defects.<sup>3</sup>

While facial fractures in the pediatric population comprise less than 15% of overall facial fractures in the general population, mandibular fractures are among the most common in pediatric patients. The incidence of mandibular fracture in children ranges from 0.6% to 1.2%. The most typical causes of fracture in children were fall (64%), traffic incidents (22%), and sports-related accidents (9%).<sup>4</sup>

Fractures in the mandibular region can be detected through palpation, or by observing functional alterations (occlusion, extent and symmetry of the jaw movements). Bruises and swellings in the soft tissue region also can indicate the presence of a fracture. The diagnosis should be confirmed by panoramic radiographs, by posteroanterior mandible radiographs and by localized radiographs of the affected region.<sup>5</sup> Fractures occurring in children present problems in achieving and maintaining stability that are quite different from those in adults. As such, the treatment modality differs in children due to the anatomic complexity of the developing mandible, presence of tooth buds, and eruption of primary and permanent teeth. The most common treatment includes cap splints with circum-mandibular wiring, cap splint cemented onto the arch, and Erich arch-bar fixation.<sup>4,6,7</sup>

The purpose of this article is to provide an insight on maxillofacial injuries in pediatric patient and to assist the clinician in the management of Mandibular parasymphysis fracture in children with acrylic closed cap splint, a definitive treatment modality.

## Case Report

An 8 year old boy reported to the department of Pedodontics and Preventive Dentistry with an injury to oral and perioral region because of fall from first floor of the building while playing, then he notice mobility and pain in the front region of jaw. There was no history of loss of consciousness or no history of bleeding from nose ears or injury to head. The patient was taken to some local dentist where he had been prescribed medication and emergency treatment was given to patient. Then the local dentist referred the patient to the Department of Pedodontics, TMDCRC, Moradabad.

On extraoral examination child had swelling on the right parasymphiseal region and deviation of face towards right side with limited mouth opening difficulty in mastication and speaking. The patient showed spontaneous pain, which intensified when touched, in the right chin and in the masseteric and right articular region. There was no discerepitation when the temporomandibular joint was examined. Intraorally sublingual hematoma, step deformity and spacing is present in between 83 and 84.

Orthopantomograph revealed a radiolucent line between mandibular right primary canine and first primary molar upto inferior border of mandible with minimal (2mm) displacement of the fractured segments. (figure 1)

Informed consent was obtained from parents prior to the beginning of treatment. Maxillary and mandibular

impressions were obtained using alginate impression material. Casts were fabricated using dental stone.

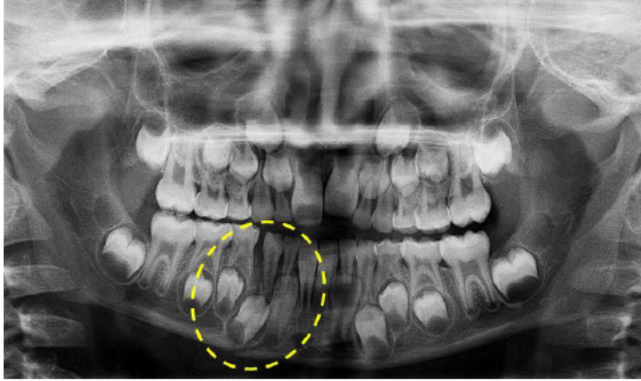


Figure 1: - Preoperative Orthopantomograph

The fractured site was marked on the mandibular cast and split into two segments using an electric saw (i.e. mock surgery was performed).

After mock surgery, the casts were held in their reduced positions and proper occlusion with the opposing maxillary cast was confirmed with the help of sticky wax. (figure 2)

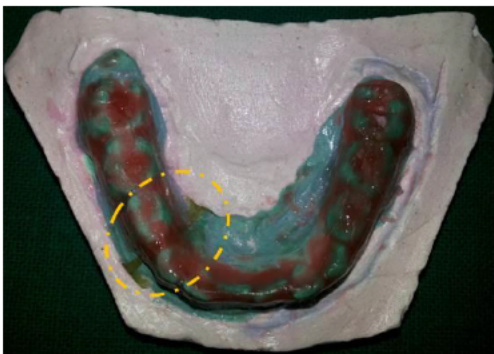

Figure 2: - Wax-spacer to blockout under cut

Both the upper and lower casts were stabilized and mounted onto an articulator. 19- gauge orthodontic wire was used for the adaptation of U shaped wire on buccal and lingual surface to reinforce the splint.

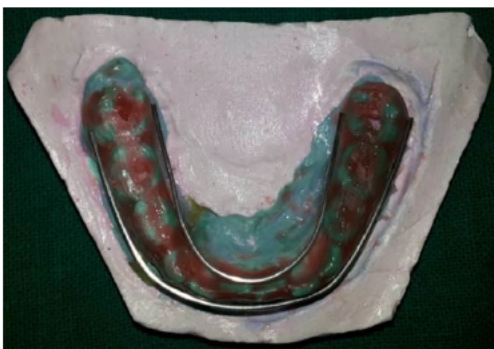

Figure 3: - U-shaped wiring

The occlusal surfaces of all the mandibular teeth and all the undercuts were blocked using modelling wax. Closed cap splint was fabricated with self-cure acrylic. The cap splint was then finished, polished and tried in the patient's mouth.

The required adjustments were done after checking the occlusion of the patient, intraorally using articulating paper. Then the closed cap splint was cemented on the teeth using Type I Glass ionomer cement. (figure 4)

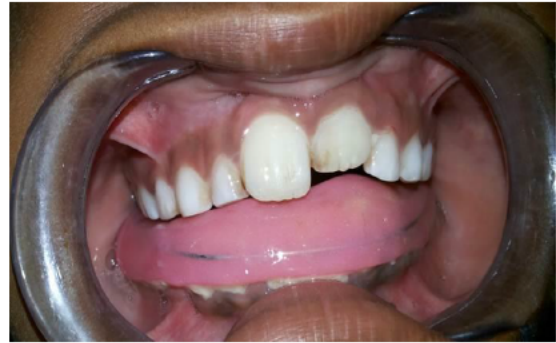

Figure 4: - Cementation of acrylic cap splint

The patient was prescribed antibiotics and analgesics for a week. Patient was instructed to take soft diet till removal of splint and patient is asked to do proper cleaning of oral cavity. Patient was followed up at regular intervals. The splint was removed by the end of seven weeks. On clinical examination, the occlusion was stable, no spacing is present between 83 and 84 with no mobility of the fractured fragment was observed.

Orthopantomograph revealed continuity of the lower border and healing of mandible. (figure 5)

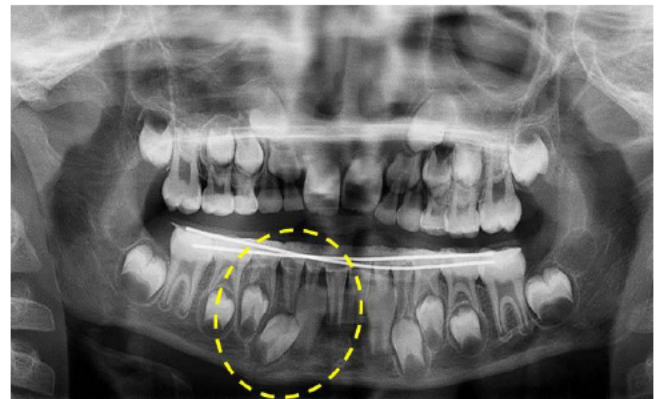


Figure 5: - Orthopantomograph after 7 weeks

### Discussion

The pediatric facial trauma patient provides several considerations that are not present in the adult. The pediatric patient has the advantage of fast ability to heal in a short duration with few complications, aided by the well vascularized tissues and blood supply of the face. Also through the assistance of growth and an inherent ability to adapt, recovery of damaged orofacial tissues and function is much better than in the adult.<sup>8,9</sup> Maxillofacial injuries in children are uncommon. The prevalence of different sites of mandibular fracture, including the condyle, alveolus, body, symphysis, parasymphysis, angle, ramus, and coronoid, is given by Haug and Foss.<sup>6</sup>

Approximately 40% of paediatric fractures involve the mandible. Management of mandibular fractures in children differs somewhat from that in adult because of several considerations, including anatomic variation, rapidity of healing, degree of patient cooperation, and the potential for changes in mandibular growth. The treatment modality of fractures in the pediatric mandible depends on the patient's age and stage of tooth development.<sup>10</sup> It is more difficult to make use of the teeth in paediatric patient for fixation, because deciduous teeth may be either insufficient in number or their roots may be resorbed and mainly due to incomplete eruption of permanent teeth.<sup>9</sup>

Minimally displaced fractures can be treated by soft diet, analgesic use, and antibiotic prophylaxis. However, in very young children, healing might be prolonged because of insufficient cooperation in following postoperative instructions. In such cases, fabrication of a splint and cementing onto the arch can be used to overcome this hindrance.<sup>4</sup>

There are various techniques which were frequently utilized in management of pediatric jaw fractures which are Tape Muzzles, Circumferential wiring, acrylic Splint, percutaneous skeletal fixation, open reduction, resorbable plates, orthodontic resin, modified orthodontic brackets, rubber elastics in combination with orthodontics brackets, nickel titanium staples.<sup>11</sup> In severely displaced fracture the treatment option can vary from intermaxillary fixation, cap splints to plating with mini plates or resorbable plates. Miniplates need caution so as not to injure the tooth buds of the permanent teeth and may need to be removed after osteosynthesis in growing children. A resorbable plate eliminates the need for the second surgical procedure for the removal but the risk of damage to tooth buds does exist.

In this case report, a modified closed cap splint is used for the closed reduction in a minimally displaced parasymphysis fracture. The modified closed cap splint provides adequate stability of fractured fragments and avoid intermaxillary fixation. It is easy to fabricate, simple and reliable method for reduction of minimally displaced fractures. The clinical outcome in the present case indicates that closed cap splint is best method for the reduction of the minimally displaced fracture. Closed cap splint is an effective and more reliable method than open reduction or intermaxillary fixation in terms of ease of application and removal, less time consumption, cost-effectiveness, good stability during healing period and minimal trauma to surrounding tissues. Therefore, we strongly recommend the use of the modified closed cap splint in paediatric patients with mandibular fractures as a method of closed reduction.

### Conclusion

Mandibular fractures in children most commonly occur in condylar region, followed by parasymphysis and angle. The fractures tend to be minimally displaced and in majority of cases can be treated conservatively. Cap splints for treatment of pediatric mandibular parasymphysis reliable fixation techniques with regard to occlusion guided fracture

reduction, maximum stability during healing period, ease of application and removal, reduced operation time, minimal trauma for adjacent anatomic structures, wide age group safe usage, ease of maintenance of oral hygiene, and comfort for young patients.

### References

1. Andreasen JO, Andreasen FM, Andersson L. Text book and color atlas of traumatic injuries to the teeth. 4 ed. Oxford: Blackwell Munksgaard; 2007. 770 p.
2. Mc Donald, Avery, Dean. Text book of dentistry for child and Adolescent. 8th ed. Elsevier publication. 2008.16p
3. Jorge KO, Moyses SJ, Ferreira e Ferreira E, Ramos-Jorge ML, de Araujo Zarzar PM. Prevalence and factors associated to dental trauma in infants 1–3 years of age. *Dent Traumatol* 2009;25(2):185–189.
4. Agrawal RM, Yeluri R, Singh C, Chaudhry K, Munshi AK. Management of Pediatric Mandibular Fracture: A Case Series. *Compend Contin Educ Dent* 2014;35(8):578-82.
5. Abdelnur JP, da Rosa Gotze G, Barreira AK, Maia LC. Parasymphyseal fracture associated with fracture of a maxillary primary molar in a child: case report. *Dent Traumatol* 2009;25(2):e21–e24.
6. Haug RH, Foss J. Maxillofacial injuries in the pediatric patient. *Oral Surg Oral Med Oral Pathol Oral Radiol Endod* 2000;90(2):126-134.
7. Eggensperger Wymann NM, Holzle A, Zachariou Z, Iizuka T. Pediatric craniofacial trauma. *J Oral Maxillofac Surg* 2008;66(1):58-64.
8. Eppley BL. Use of resorbable plates and screws in Pediatric Facial Fractures. *J Oral Maxillofac Surg.* 2005;63(3):385-391.
9. Mohan MC, Bhat S, Karaikal A, Gupta N. Reinforced open cap splint: A novel therapeutic technique in paediatric mandibular fracture. *Heal Talk* 2012;5(1):32-33.
10. Kaban LB. Facial trauma I: midface fractures. In: Kaban LB, ed. *Pediatric Oral and Maxillofacial Surgery*. Philadelphia, PA: W.B. Saunders; 1990:209-232.
11. Madan N, Bajaj N. Conservative treatment of pediatric mandibular fracture with removable acrylic splint. *Indian J Dent Sci* 2010;2(4):22-24.

### Corresponding Author

Dr. Pranjil Jain  
Postgraduate student,  
Department of Pedodontics & Preventive Dentistry,  
Teerthanker Mahaveer Dental College and Research  
Centre, Moradabad, Uttar Pradesh.  
Email- pranjil.jain1986@gmail.com