

AMELOBLASTIC CARCINOMA OF MANDIBLE- A CASE REPORT

Masood Hasan Khan,¹ Parikshit Sharma,² Asif Nafis Khan,³ Arnab Mukherjee⁴

1. Senior Lecturer, Department of Oral Pathology & Microbiology, Teerthanker Mahaveer Dental College & Research Center, Moradabad, Uttar Pradesh.

2. Senior Lecturer, Department of Oral Pathology & Microbiology, King George's Dental College, Lucknow, Uttar Pradesh.

3. Technical Assistant, Department of Radiology, J.N. Medical College, Aligarh, Uttar Pradesh.

4. Post Graduate Student, Department of Oral Pathology & Microbiology, R. Ahmed Dental College, Kolkata

Abstract

Ameloblastic carcinoma is a rare and potential malignant ulcerative lesion with typical histologic properties that advocates a different and aggressive surgical treatment in comparison to the techniques employed in the treatment of simple ameloblastoma. Due to its rarity and the lesser description of well documented cases its biological nature is not available in the medical literature. Its most common location is the mandible with a wide range of age distribution and without any particular sex and ethnicity. Its presentation are varied ranging from cystic and benign features to large and asymmetric growth of tissue mass with indurated ulcers, bony destruction and mobile tooth. The features that suggest ameloblastic carcinoma should be clear and well recognized by the practicing dentists. The tumour bear close resemblance to cells in ameloblastoma but with a difference that they exhibit cellular and cytological atypia. The other finding that demarcates them from simple ameloblastoma is that they lack the typical arrangement seen in ameloblastoma. Lymph node involvement along with direct extension and metastasis to other parts of the body, most commonly the lung are mostly reported in the literature. We present a case of ameloblastic carcinoma of the mandible with a clinical course of typical aggressiveness and extensive local destruction in a 60 year old male patient.

Key Words: - Ameloblastoma, Odontogenic Cyst, Odontogenic Tumours

Introduction

Ameloblastic carcinoma (AC) is a rare, malignant epithelial odontogenic tumor aggressive by nature and with a poor prognosis. Almost 60 % of the tumors are found in mandible while rest of the 30 % arises in maxilla.¹

The common presentation is a rapidly growing painful swelling. The most widely used treatment modality is the wide surgical excision with or without concomitant radiotherapy.²

The malignant nature of ameloblastoma is a matter of controversy and debate for last so many years. There can be little argument that an ameloblastoma that metastasizes is malignant, even if the tumour shows benign histological features. In other cases, the ameloblastoma which shows very aggressive clinical progression without showing metastasis are generally considered as malignant. These microscopic pictures in these lesions often show atypical histopathological features.³ Carcinomas developing from ameloblastoma have been named by a wide array of terms, which includes malignant ameloblastoma, ameloblastic carcinoma, metastatic ameloblastoma and primary intra-alveolar epidermoid carcinoma. In 1971, the World Health Organization (WHO) proposed its classification of carcinomas having odontogenic origin recognizing the following subtypes: Malignant ameloblastoma & Primary intra-osseous carcinoma. Other malignancies include those arising from cysts of odontogenic nature.

In this classification, "malignant ameloblastoma" refers to a neoplasm in which typical histological features of ameloblastoma are seen in the primary tumour located in the jaw as well as in any associated metastatic deposits.

"Primary intraosseous carcinoma" (PIOC) refers to a primary carcinoma of the jaw not having features of ameloblastoma and not arising from an odontogenic cyst. The "other carcinomas" includes those which develop from

odontogenic cysts. In 1982, Elzay⁴ proposes that the WHO classification does not categorize the tumours that are histologically similar to classic ameloblastoma and metastasize from ameloblastoma-like lesions that are histologically malignant before metastasizing. He suggested a modification of the classification in which all primary intra-osseous carcinomas that do not involve the salivary glands would be classified as PIOC, which would then be sub classified as follows:

- Type 1: arising from an odontogenic cyst
- Type 2: arising from an ameloblastoma
 - a. Well differentiated (malignant ameloblastoma)
 - b. Poorly differentiated (ameloblastic carcinoma)
- Type 3: arising de novo
 - a. Non-keratinizing
 - b. Keratinizing

In 1984, Slootweg and Müller⁵ further stressed that the ameloblastoma may exhibit malignant features other than metastasis and suggested a modified classification system for malignant tumours with features of ameloblastoma, based on characteristics of malignancy:

- Type 1: PIOC ex odontogenic cyst
- Type 2:
 - a. Malignant ameloblastoma
 - b. Ameloblastic carcinoma, arising de novo, ex ameloblastoma or ex odontogenic cyst
- Type 3: PIOC arising de novo
 - a. Non-keratinizing
 - b. Keratinizing

Elzay⁴ and Slootweg and Müller⁵ use the term ameloblastic carcinoma to convey the presence of cytologic features of malignancy. The extent of differentiation in epithelial tumours is usually taken into account to be significant in predicting biologic behaviour of metastasis. The main difference between Elzay's and Slootweg and Müller's classification relates to the pattern of histogenesis.

According to them, the term ameloblastic carcinoma should be used to demarcate lesions that show histologic features of ameloblastoma and carcinoma together. The tumour may metastasize and histologic features of malignancy may be found in the primary tumour, the metastases or both.⁵⁻⁷ The term malignant ameloblastoma should be localized to the ameloblastoma that metastasize with an apparently normal benign histology in both the primary and the metastatic lesions^{6, 8}. The incidence of ameloblastic carcinoma is more than that of malignant ameloblastoma by a 2:1 ratio.³

Case Report

A 60 year old male patient presented to the OPD of the Department of Oral Pathology and Microbiology, Teerthankar Mahaveer Dental College and Research Centre with a chief complaint of the massive swelling and pain over the right lower third of the face since 9 month (Figure. 1).



Figure 1: - Extra oral picture of the patient showing gross deformity of the face.

The patient did not give any history of trauma or any kind of dental problem in the same region. Patient noticed a rapidly progressing swelling in the same region 9 months back, associated with pin and needle sensation of the lower lip.

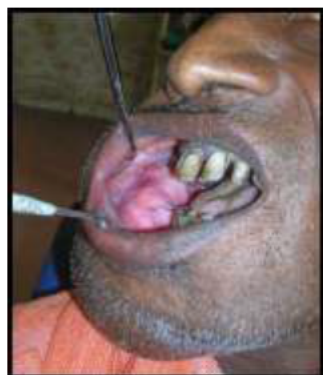

Figure 2: - Intra oral picture of the patient showing the involvement of the body of the mandible and the massive swelling of the alveolar ridge, buccal mucosa and the mandible.

Following which he developed pain sudden in onset, dull in nature, continuous, non-radiating, and relieved partially with analgesics. Patient also had complaint of dysphagia,

trismus, dysphonia fever, chills or loss of weight and his past medical history was not contributory. Clinical examination revealed a diffuse swelling over the right body of the mandible approximately 8 X 3 cm in size, surface smooth and overlying skin appeared stretched. On palpation, the swelling was uniformly bony hard and tender with no local rise in temperature. Paresthesia of the lower lip was noted. Right submandibular lymph node was palpable. On the basis of clinical picture and intra oral examination, provisional diagnosis of ameloblastoma right mandible was given. Differential diagnosis included odontogenic keratocyst, odontogenic myxoma and ameloblastic carcinoma. Patient was subjected to routine radiographic investigation. The orthopantomography (OPG) showed well defined radiolucent lesion in the right angle, body of the mandible, crossing the midline to involve the left side of mandible with thinning and destruction of the lower border of mandible. OPG reveals destruction of the body of the right side mandible, and absence of first molar premolars and canine of the involved side (Figure. 3).

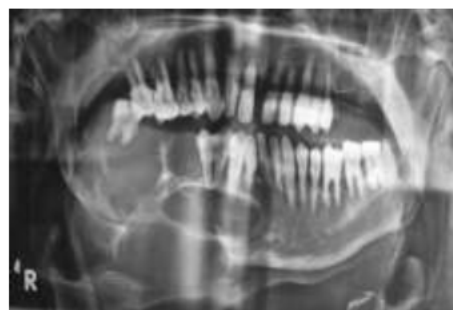

Figure 3: - Ortho-pantomogram. OPG reveals the extent of the bone destruction of the body of the mandible extending to the ramus and angle region of the mandible

Incisional biopsy taken from two sites, showed follicles of odontogenic epithelium lined peripherally by tall columnar cells and central stellate reticulum like cells within a scanty connective stroma. Follicles showed varying histologic features like nuclear polymorphism, basal cell hyperplasia, and squamous metaplasia with dyskeratosis, necrosis and cystic degeneration.

The surface showed parakeratinized stratified squamous epithelium of gingiva, features suggestive of ameloblastic carcinoma (Figure 4, figure 5 and figure 6).

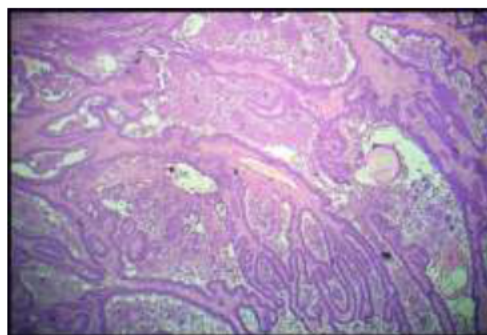


Figure 4: - Photomicrograph 4X showing tumor cells arranged in follicles and sheaths proliferating in mature stroma

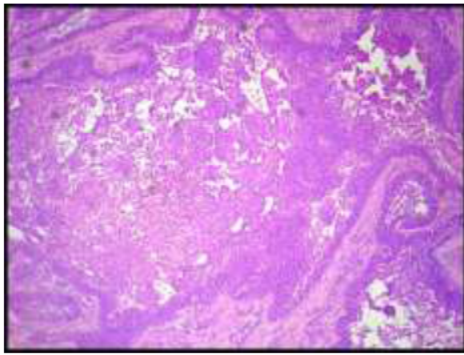


Figure 5: - Photomicrograph 10 X showing Tumor island showing peripheral palisading cells with hyperplasia (hematoxylin-eosin; original magnification X10).The tumor cells have ameloblastic configuration bounding stellate reticulum-like cells along with cystic degeneration

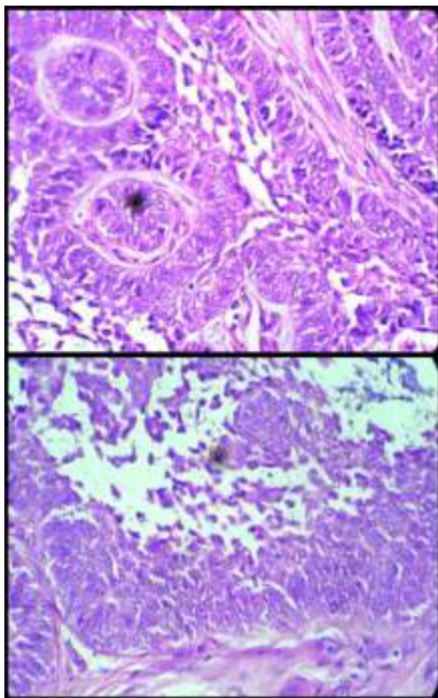


Figure 6: - Photomicrograph showing Island of tumor cells with individual cell displaying dysplastic features such as hyperchromatism, pleomorphism, and mitosis

Discussion

Shafer for the first time in 1983 introduced ameloblastic carcinoma to be a pathological entity in which histological malignant transformation takes place. The age and gender predilection is not very specific as it occurs in a wide range of age groups. The mean age being in the third decades almost similar to typical ameloblastoma. There is also no specific sexual predilection seen in ameloblastic carcinoma. Most common location is posterior part of the mandible. The common presenting symptoms include swelling, pain, rapidly growing, restricted mouth opening and dysphonia⁷. Maxilla involvement is less documented as compared to mandible by ameloblastic carcinoma.⁹⁻¹² Histologically, it is

a benign tumour that grows from the odontogenic apparatus and includes only 1% of tumours and cysts in the jaw. The malignant type of ameloblastoma is in controversy for many years. The term “malignant ameloblastoma” specifies that these tumours metastasize despite their benign features. The term “ameloblastic carcinoma” is limited to a type of ameloblastoma that has a typical malignant appearance, irrespective of the presence or absence of metastasis.

Ameloblastic carcinomas are very rare malignant neoplasms of odontogenic nature and may arise de novo or from a pre-existing odontogenic lesion.¹³

In our case study, the radiographic appearance of the lesion was consistent with that of an ameloblastoma except aspiration on fluid, with the histological finding suggestive of ameloblastic carcinomas.

These histologic and radiologic features are different and not generally seen in conventional ameloblastoma. Clinically, these carcinomas are aggressive than the typical ameloblastoma. Perforation of the cortical plate, direct growth in the surrounding tissues, recurrence of the lesions and metastasis, usually to cervical lymph nodes, can be associated with ameloblastic carcinomas.⁶

The characterization of carcinoma arising centrally within the mandible and the maxilla is an uncommon but complex problem. The staging process includes the exclusion of metastasis and invasion of bone from adjacent soft tissues. The origin of the neoplasm can be from odontogenic derivatives like odontogenic cysts ameloblastoma etc. entrapped salivary gland epithelium and sometimes by epithelium entrapped along embryonic sites.

The diagnosis of ameloblastic carcinomas should always be ascertained by ruling out the secondary metastasis from primary locations such as the lung, breast and the gastrointestinal tract.^{6,14} The differential diagnosis of ameloblastic carcinoma includes. Primary intra-alveolar epidermoid carcinoma developing within bone, and most probably have its origin from odontogenic epithelial remnants.⁶ The other pathological entities that come closer in differential diagnosis are the two types of ameloblastoma. These include the acanthomatous ameloblastoma which exhibits squamous metaplasia and varying degrees of keratinization of the stellate reticulum portion of the tumour islands; although, peripheral palisading is well maintained and no atypical cytologic features of malignancy are found. The other type includes the kerato-ameloblastoma which is quite a rare variant of ameloblastoma characterized by prominent keratinizing cysts that may confuse and distracts the otherwise diagnosis of ameloblastomatous feature.^{6,14}

The other picture which can mimic ameloblastoma carcinoma is the development of oral squamous cell carcinoma in the lining of the odontogenic cyst.¹⁵ Thus, the term ameloblastic carcinoma can be applied to this case, which implies focal histologic proof of malignant disease including cytologic atypia and mitoses with indisputable

features of classic ameloblastoma. It is reasonable to assume that this case illustrates the malignant portion in the spectrum of ameloblastoma. It is possible that ameloblastoma exhibits a wide array of histologic and biologic behaviours from benign features to frank malignancy. All cases of ameloblastoma must be studied carefully, considering the histologic pattern and biologic behaviour to detect subtle differences in histology which may affect the outcome of aggressive behaviour.

The treatment of ameloblastic carcinoma is not standardised owing to the controversy surrounding its management and treatment, although the recommended surgical treatment advocates the jaw resection with 2- to 3-cm bony margins with or without neck dissection, both prophylactic and therapeutic. Follow-up is important because recurrence and metastasis in the lung and regional lymph nodes have been reported. Pre-surgical radiation therapy has been suggested to decrease tumour size, but chemotherapy is generally not useful.

References

1. Lolachi CM, Madan SK, Jacobs JR. Ameloblastic carcinoma of the maxilla. *J Laryngol Otol*. 1995;109:1019-22
2. Dhir K, Sciubba J, Tufano RP. Ameloblastic carcinoma of the maxilla. *Oral Oncol*. 2003;39:736-41
3. Regezi JA, Kerr DA, Courtney RM. Odontogenic tumors: analysis of 706 cases. *J Oral Surg*. 1978; 36:771-8.
4. Elzay RP. Primary intraosseous carcinoma of the jaws. Review and update of odontogenic carcinomas. *Oral Surg Oral Med Oral Pathol*. 1982; 54:299-303.
5. Sloomweg PJ, Müller H. Malignant ameloblastoma or ameloblastic carcinoma. *Oral Surg Oral Med Oral Pathol*. 1984; 57:168-76.
6. Corio LR, Goldblatt LI, Edwards PA, Hartman KS. Ameloblastic carcinoma: a clinicopathologic study and assessment of eight cases.
7. Lau SK, Tideman H, Wu PC. Ameloblastic carcinoma of the jaws. A report of two cases. *Oral Surg Oral Med Oral Pathol Oral Radiol Endod*. 1998; 85:78-81.
8. Nagai N, Takeshita N, Nagatsuka H, Inoue M, Nishijima K, Nojima T, et al. Ameloblastic carcinoma: case report and review. *J Oral Pathol Med*. 1991; 20:460-3.
9. Lee L, Maxymiw WG, Wood RE. Ameloblastic carcinoma of the maxilla metastatic to the mandible. Case report. *J Craniomaxillofac Surg*. 1990; 18:247-50.
10. McClatchey KD, Sullivan MJ, Paugh DR. Peripheral ameloblastic carcinoma: a case report of a rare neoplasm. *J Otolaryngol*. 1989;18:109-11.
11. Andersen E, Bang G. Ameloblastic carcinoma of the maxilla. A case report. *J Maxillofac Surg*. 1986; 14:338-40.
12. Daramola JO, Abioye AA, Ajagbe HA, Aghadiuno PU. Maxillary malignant ameloblastoma with intraorbital extension: report of case. *J Oral Surg*. 1980; 38:203-6.
13. Cizmecý O, Aslan A, Onel D, Demiryont M. Ameloblastic carcinoma ex ameloblastoma of the mandible: case report. *Otolaryngol Head Neck Surg*. 2004;130:633-4.
14. Gandy SR, Keller EE, Unni KK. Ameloblastic carcinoma: report of two cases. *J Oral Maxillofac Surg*. 1992; 50:1097-102.
15. Gardner AF. The odontogenic cyst as a potential carcinoma: A clinicopathologic appraisal. *J Am Dent Assoc*. 1969; 78:746-55.

Corresponding Author

Dr. Masood Khan
Department of Oral Pathology & Microbiology,
Teerthanker Mahaveer Dental College & Research
Center, Moradabad
E-mail: masood9903869359@gmail.com