

# AN IN-VITRO COMPARISON BETWEEN HAND WRIST OSSIFICATION AND MANDIBULAR SECOND MOLAR CALCIFICATION AS A MATURITY INDICATOR

Pradeep Raghav,<sup>1</sup> Akshi Rathee,<sup>2</sup> Vaibhav Misra,<sup>3</sup> Mumish Reddy C,<sup>4</sup> Shishir Singh,<sup>5</sup> Ajay Yadav<sup>6</sup>

<sup>1</sup> Professor & Head, Department of Orthodontics, Subharti Dental Sciences & Hospital, Meerut, Uttar Pradesh

<sup>2</sup> & <sup>6</sup> Post Graduate Student, Department of Orthodontics, Subharti Dental Sciences & Hospital, Meerut, Uttar Pradesh

<sup>3</sup> & <sup>5</sup> Reader, Department of Orthodontics, Subharti Dental Sciences & Hospital, Meerut, Uttar Pradesh

<sup>4</sup> Professor, Department of Orthodontics, Subharti Dental Sciences & Hospital, Meerut, Uttar Pradesh

## ABSTRACT

**Objective:** To compare the mandibular second molar calcification stages with hand wrist maturity indicator and to evaluate the reliability of mandibular second molar as a skeletal maturity indicator.

**Materials and Method:** The sample consisted of orthopantomograms and hand wrist radiographs of 100 children (50 girls and 50 boys) of north indian population aged from 9 to 15 years. Dental age estimation was done according to Demirjian method on panoramic radiographs and the fishman's skeletal maturation assessment was evaluated on hand wrist radiographs and compared between each other.

**Results:** A significant correlation was seen between demirjian mandibular second molar calcification stages and fishman's skeletal maturation assessment. For both sexes, DI stage E showed the highest percent distribution at stage 3 of SMA. Stages F and G corresponded to SMA stages 4, 5, and 6. Fishman's skeletal maturity indicator and the fusion of the epiphysis and diaphysis of the radius (which signifies the end of growth) corresponds to Stage H. DI stage H suggests insignificant/no remaining adolescent growth.

**Conclusion:** A significant association exists between Demirjian's second molar calcification stages and fishman's skeletal maturation assessment. Mandibular second molar stages can be used as a reliable indicators of skeletal maturity.

**KEY WORDS:** Demirjian Index, Hand wrist radiograph, Panoramic radiograph, Skeletal maturity indicator.

## Introduction

Knowledge regarding growth and development of children and adolescents is considered important for a wide range of dental professionals for age prediction. Variation seen in the development of a child of same chronological age as compared to his/ her peer has led to the concept of biologic or physiologic age. Physiologic age is the estimation of the actual rate of skeletal and somatic growth.<sup>1</sup> In the field of orthodontics, physiological age is determined by the degree of maturation of different body parts, which is known to vary between populations and can alter treatment planning.

Somatic maturity is recognized by the annual growth increments seen in height or weight with time. The changes of secondary sex characteristics like voice changes in boys and menarche in girls, are characterized as sexual maturity. The usefulness of these indicators is very limited for the immediate clinical judgment of a patient's maturity because these indicators can be applied only after the serial recording of height or attainment of puberty.

Skeletal maturation staging from radiographic analysis is a widely used approach to predict timing of pubertal growth and to estimate the proportion of growth remaining. Skeletal maturation can be determined by using stages in the ossification of bones of the hand and wrist;<sup>2</sup> cervical vertebrae, frontal sinus have also been reported as methods of skeletal growth prediction.<sup>3</sup>

Developmental stages of the hand and wrist have been shown to be closely associated with the pubertal growth spurt and has been used as a method for the assessment of somatic maturity stage. However, the routine use of hand

wrist radiographs has lately been questioned from the radiation hygiene, safety point of view.<sup>4</sup>

Dental maturity can be determined by staging tooth eruption or by the stages of tooth formation. Many researchers have found that tooth formation is a reliable method for determining dental maturation. The ease of recognition of developmental stages, together with the availability of periapical or panoramic radiographs in most orthodontic practices are practical reasons for attempting to assess the physiologic maturity without resorting to hand-wrist radiographs.<sup>5</sup>

Many authors<sup>6,7</sup> have used tooth calcification stages of mandibular canines and third molars as maturity indicators with variable results due to inconsistency in development of third molars and timing of development of canines. Whereas the rate and timing of development of the mandibular second molars is much consistent and coincident with the phases of growth of a child. Garn *et al*<sup>8</sup> showed only weak correlations between third molar and skeletal development; Engstrom *et al*<sup>6</sup> reported stronger relationships. Relationships between the stages of tooth mineralization of the mandibular canine appear to correlate better with ossification stages than do the other teeth. Racial variations in the relationship have also been suggested. Mappes *et al*<sup>3</sup> concluded that the predominant ethnic origin of the population, climate, nutrition, socio-economic levels and urbanization are common factors of these racial variations.

The ability to assess skeletal maturity by the stages of mandibular second molar calcification through the examination of a panoramic radiograph (which is a routine

diagnostic radiograph for dental/ orthodontic treatment) would offer an advantage over the conventional hand-wrist radiographic method; since no additional exposure to radiation occurs if assessment of skeletal maturity is performed through routine radiographs, as keeping in mind the ALARA (As Low as Reasonably Achievable) principle. Therefore the present study was designed to compare the demirjian's second molar calcification stages with fishman's skeletal maturation assessment for determining skeletal maturity and to assess the reliability of mandibular second molar as a growth maturity indicator.

**Material and Method**

A cross- sectional study was designed with samples obtained from orthopantomograms and hand wrist radiographs of 100 north Indian subjects (50 male and 50 female) from the pre- treatment records along with the informed consent of the patients in the OPD for orthodontic treatment. The inclusion criteria was:

- Chronological age ranging from 9 to 15 years
- No serious illness or systemic disease
- Normal overall growth and development
- Absence of previous history of trauma or disease to the face and neck
- Absence of orthodontic treatment
- No permanent teeth extracted

A single radiologist exposed and developed all radiographs. The evaluation of the radiograph was done on the same day.

*Evaluation of Dental Maturity on Panoramic Radiograph*

In this study, the mandibular second molar was used as a sample for estimation of dental maturity on orthopantomograms. Tooth calcification was rated according to the index described by Demirjian et al<sup>5</sup>. (Demirjian Index [DI]), in which one of eight stages of calcification (A to H) was assigned to the tooth.

*Evaluation of Hand wrist stages on hand wrist radiographs*

The system developed by Fishman et al<sup>2</sup> (Skeletal maturation assessment [SMA]) was used to determine skeletal maturation by hand wrist radiograph. This system uses four stages of bone maturation, found at six anatomical sites located on the thumb, third finger, fifth finger and radius leading to eleven discrete adolescent skeletal maturational indicators.

**Statistics**

Statistical tabulation using the Microsoft Office Excel 2013 and analysis using SPSS software (version 21, SPSS Inc, Chicago, Ill) was performed. Descriptive statistics by determining the means and standard deviations of the chronological ages for the eleven stages of hand wrist was done.

The Pearson chi-square test (x<sup>2</sup>) value was estimated to determine the relationships between DI and SMA.

**Result**

Table-1 shows the number of subjects along with the age ranging from 9-15 years with a mean age 12.17 ± 1.93 of the sample.

Table 1: Distribution of sample

	N	Minimum	Maximum	Mean	SD
Age	100	9.0	15.0	12.17	1.93

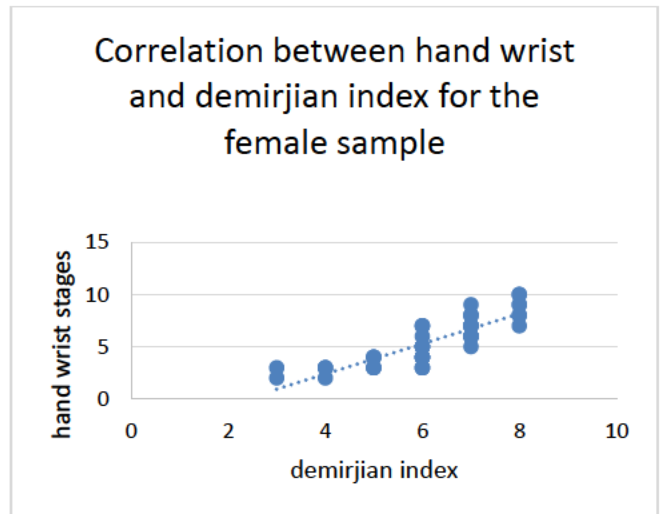
Table 2: Correlation between age, demirjian index and hand wrist stages for whole sample

		Age	Demirjian Index	Skeletal Maturity Indicator
Age	Pearson Correlation	1	.902**	.929**
	Sig. (2-Tailed)		.000	.000
	N	100	100	100
DI	Pearson Correlation	.902**	1	.861**
	Sig. (2-tailed)	.000		.000
	N	100	100	100
SMI	Pearson Correlation	.929**	.861**	1
	Sig. (2-tailed)	.000	.000	
	N	100	100	100

\*\* Correlation is significant at the 0.01 level (2-tailed).

In Table-2, Pearson Correlation shows that there exists a correlation in both males and females between chronological age and demirjian's mandibular second molar calcification staging; fishman's skeletal maturation assessment and chronological age; demirjian's mandibular second molar calcification staging and fishman's skeletal maturation assessment.

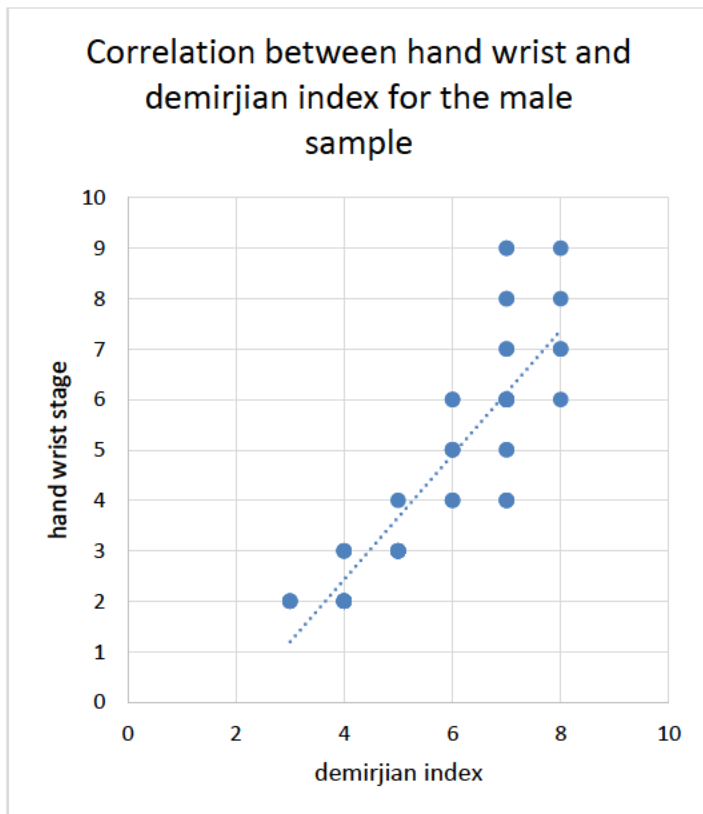
Graph 1: Association between DI and hand wrist stages for females



Pearson correlation; Correlation coefficient = 0.844, P<.001 (significant)

Graph 1 shows the distribution and association among female subjects between hand wrist and DI. The value for pearson coefficient was highly significant at 0.844. From this graph, it is found that higher the DI stage, the higher the SMA stage. Stage C and D were associated with a distribution at stage 2 of SMA. Stage E distributed at stage 3 and 4 of the SMA. Stage F was distributed for hand wrist stages 4, 5. DI stage G also was included with hand wrist stage 6 and 7. Stage H displayed a distribution with stage 8, 9

Graph- 2 Association between DI and hand wrist stages for males



Graph- 2 shows the distribution and association among male subjects between hand wrist and DI. The value for pearson coefficient was highly significant at 0.861. This graph also reveals that higher the DI stage, the higher the SMA. Stage C and D were associated with a distribution at stage 2 and 3 of hand wrist. Stage E distributed at stage 3 and 4 of the hand wrist. Stage F was distributed for hand wrist stages 4, 5. DI stage G also was included with hand wrist stage 5, 6 and 7. Stage H displayed a distribution with stage 8, 9.

### Discussion

Dental maturity has an advantage of easy evaluation during routine dental treatment. Dental maturity assessment offers the advantage of being a simple procedure that can be carried out on panoramic and intraoral radiographs that provide minimal irradiation to the patient and easy determination of the calcification stages of teeth. On this basis, many researchers have proposed dental maturation to

be a clinically useful diagnostic aid for the identification of individual skeletal maturation stages<sup>7,9,10,11</sup>.

Several methods have been proposed for assessing dental age according to degree of calcification but the most widely used method is given by demirjian<sup>5,12</sup> based on a large number of Canadian children. Demirjian index was used to assess orthopantomograms and assign second molar calcification stages.

Demirjian<sup>5</sup> gave the method for estimating dental maturity or dental age by referencing to the radiological appearances of teeth. Each tooth was rated according to developmental criteria. 8 stages i.e. A to H were defined from the first appearance of calcified points to the closure of the apex. The summed scores on teeth gave a dental maturity score which can be converted directly into a dental age.

Fishman<sup>2,13</sup> developed a system of skeletal maturation assessment (SMA) using four stages of bone maturation at six anatomic sites on the hand and wrist and gave 11 SMA on hand and wrist radiograph that occurs serially from the onset to the termination of adolescence. Fishman skeletal maturation assessment method has been used since it is preferred over the other methods as the stages are well defined and the sequence of occurrence of the eleven indicators is stable.<sup>2,14</sup> The ossification of the hand is putatively considered to represent the maturation of the entire skeletal system.

In the present study demirjian's developmental stages of mandibular second molar has been investigated to assess its reliability as an indicator of maturity by comparing it with Fishman's skeletal maturation assessment method. This tooth offers an advantage over other teeth because its development tends to continue over a longer period and until a later age.<sup>15</sup> Apex closure generally extends up to the age of 16 years in normal children.

Due to the presence of calcified structures that superimpose on the maxillary teeth, the mandibular teeth have been reported as being the best for identification of the maturity stages based on panoramic radiographs.<sup>15</sup>

In the present study, (Table 2) a positive correlation between chronological age and Skeletal maturation assessment with correlation coefficient = 0.929 ( $p < 0.001$ ) was seen. A statistically significant positive correlation was also observed between chronological age and Demirjian's index with correlation coefficient = 0.902 ( $p < 0.001$ ).

Green *et al*<sup>16</sup> used greulich and pyle method as skeletal maturation assessment method; comparing it with nolla's dental age assessment and found that there was a positive correlation between chronological age and Skeletal maturation assessment with correlation coefficient = 0.785 as well as a significant positive correlation was also observed between chronological age and dental age with correlation coefficient = 0.677 which is in accordance with the results seen in our study. A similar positive correlation was also seen in the studies conducted by Engstrom<sup>6</sup> and

Sierra *et al*<sup>10</sup> which used Tanner and whitehouse method and grave and brown method for skeletal maturation assessment and Demirjian's method for dental maturation assessment; and concluded that there is a positive correlation which exists between chronological age and skeletal maturation assessment; between chronological age and dental maturation assessment.

In the present study, a positive correlation was also seen between Demirjian's index and Skeletal maturation assessment staging with correlation coefficient =0.861 ( $p < 0.001$ ). Perinetti<sup>17</sup> had done a study correlating the skeletal maturation and dental maturity of first and second premolars, mandibular second molar and found that there was a significant positive correlation regarding mandibular second molar with a correlation coefficient = 0.77 in comparison to other teeth. Krailassiri<sup>11</sup> conducted a study which concluded that dental maturity assessed through the calcification stages from mandibular canine, the first and second premolars, and the second molar showed a positive co-relation with skeletal maturation having a correlation coefficient = 0.63-0.68.

In contradiction to the results in this study, Green *et al*<sup>16</sup> concluded that the degree of association was closer between dental age and chronological age than between dental and skeletal age i.e. correlation coefficient = 0.461. This conclusion may be due to small sample size i.e. 56 samples or narrow age range i.e. 8-12 yrs or may be due to lack of more precise methods of evaluation of the expressions of growth and development.

A positive correlation between DI and SMA was observed for both males and females in the present study which was in accordance to a studies done by Uysal,<sup>18</sup> Sushil,<sup>15</sup> Krailassiri,<sup>11</sup> Rai.<sup>19</sup> In females, the correlation between Demirjian's mandibular second molar index and Fishman's skeletal maturation assessment staging (correlation coefficient = 0.844) was correlative with Demirjian's mandibular second molar index and Fishman's skeletal maturation assessment staging as seen in the studies conducted by Uysal<sup>18</sup> (correlation coefficient =0.826), Sushil<sup>15</sup> (correlation coefficient =0.866), Krailassiri<sup>11</sup> (correlation coefficient =0.68), Rai<sup>19</sup> (correlation coefficient =0.69).

Similarly in males, the correlation between Demirjian's mandibular second molar index and Fishman's skeletal maturation assessment staging (correlation coefficient = 0.861) was correlative with Demirjian's mandibular second molar index and Fishman's skeletal maturation assessment staging as seen in the studies conducted by uysal<sup>18</sup> (correlation coefficient = 0.706), Sushil<sup>15</sup> (correlation coefficient =0.854), Krailassiri<sup>11</sup> (correlation coefficient =0.63), Rai<sup>19</sup> (correlation coefficient =0.73).

The mean age for each skeletal maturity level indicated that female subjects mature earlier than male subjects by an average of 1.5 years which conforms with several reports<sup>20,21,22</sup>.

The relationship between skeletal maturity and peak height velocity (PHV) has been established by Bjork *et al*<sup>21</sup>; who found that capping of the epiphyses of the third middle phalanx is closely related to the age of pubertal maximum growth velocity and Hagg and Taranger *et al*<sup>22</sup>; who concluded that PHV was more closely related to the skeletal stages of the third phalanx than to the maturity stages of the radius or adductor sesamoid. For both sexes, DI stage E corresponded to stage 3 of SMA, which signifies the pre-peak of pubertal growth spurt or onset of PHV. For both male and female subjects, stages F and G was closely related to SMA stages 4, 5, and 6 which deduces that DI stages F and G represent the peak of the pubertal growth spurt. This finding supports the suggestions of previous studies done by Sushil *et al* and Krailassiri *et al*.<sup>11,15</sup> Fishman's skeletal maturity indicator<sup>13</sup> and the fusion of the epiphysis and diaphysis of the radius (which signifies the end of growth) corresponds to Stage H. DI stage H suggests that no remaining adolescent growth is left.

### Conclusion

- Each SMA stage consistently appeared earlier in female than in male subjects. A significant correlation was seen between DI and hand wrist.
- For both sexes, DI stage E showed the highest percent distribution at stage 3 of SMA, which signifies the pre-peak of pubertal growth spurt or onset of PHV. Stages F and G corresponded to SMA stages 4, 5, and 6 which infers that DI stages F and G represent the peak of the pubertal growth spurt. Fishman's skeletal maturity indicator and the fusion of the epiphysis and diaphysis of the radius (which signifies the end of growth) corresponds to Stage H. DI stage H suggests insignificant/no remaining adolescent growth.
- Mandibular second molar DI stages can be considered a reliable indicator of skeletal maturity.

### References

1. Flores-Mir C, Mauricio FR, Orellana MF, Major PW. Association between Growth Stunting with Dental Development and Skeletal Maturation Stage. *Angle Orthod* 2005;75(6):935-940
2. Fishman LS. Radiographic evaluation of skeletal maturation. A clinically oriented method based on hand-wrist films. *Angle Orthod* 1982;52(2):88-112
3. Mappes MS, Harris EF, Behrents RG. An example of regional variation in the tempos of tooth mineralization and hand wrist ossification. *Am J Orthod Dentofacial Orthop* 1992;101(2):145-151
4. Smith RJ. Misuse of hand wrist radiographs. *Am J Orthod* 1980;77(1):75-8
5. Demirjian A, Goldstein H, Tanner JM. A new system of dental age assessment. *Hum Biol* 1973;45(2):211-227
6. Engstrom C, Engstrom H, Sagne S. Lower third molar development in relation to skeletal maturity and chronological age. *Angle Orthod* 1983;53(2):97-106

7. Coutinho S, Buschang PH, Miranda F. Relationships between mandibular canine calcification stages and skeletal maturity. *Am J Orthod Dentofacial Orthop* 1993;104(3): 262–268
8. Garn SM, Lewis AB, Bonne B. Third molar formation and its development course. *Angle Orthod* 1962;32(4):270-279
9. Chertkow S, Fatti P. The relationship between tooth mineralization and early radiographic evidence of the ulnar sesamoid. *Angle Orthod* 1979;49(4):282-288
10. Sierra AM. Assessment of dental and skeletal maturity: A new approach. *Angle Orthod* 1987;57(3):194 -208
11. Krailassiri S, Anuwongnukroh N, Dechkunakorn S. Relationships between Dental Calcification Stages and Skeletal Maturity Indicators in Thai Individuals. *Angle Orthod* 2002;72(2):155–166
12. Demirjian A, Buschang PH, Tanguay R, Patterson DK. Interrelationships among measures of somatic, skeletal, dental and sexual maturity. *Am J Orthod* 1985;88(5):433-438
13. Fishman LS. Chronological versus skeletal Age, an evaluation of Craniofacial Growth. *Angle Orthod* 1979;49(3):181-189.
14. Prabhakar AR, Panda AK, Raju OS. Applicability of Demirjian's method of age assessment in children of davangere. *J Indian Soc Pedod Prev Dent* 2002;20(2):54-62
15. Kumar S, Singla A, Sharma R, Viridi MS, Anupam A, Mittal B. Skeletal maturation evaluation using mandibular second molar calcification stages. *Angle Orthod* 2012;82(3):501–506
16. Green LJ. Interrelationships among height, weight and chronological, dental and skeletal ages. *Angle Orthod* 1961;31(3):189-193
17. Perinetti G, Contardo L, Gabrieli P, Baccetti T, Di Lenarda R. Diagnostic performance of dental maturity for identification of skeletal maturation phase. *Eur J Orthod* 2012;34(4):487-92
18. Uysal T, Sari Z, Ramoglu SI, Basciftci FA. Relationships between dental and skeletal maturity in Turkish subjects. *Angle Orthod* 2004;74(5):657-664.
19. Rai B. Relationship of Dental and skeletal Radiograph: Maturity Indicator. *The Internet Journal of Biological Anthropology*. 2007; 2(1).
20. Fishman LS. Maturational patterns and prediction during adolescence. *Angle Orthod* 1987;57(3):178-193
21. Bjork A, Helm S. Prediction of age of maximum puberty growth in body height. *Angle Orthod* 1967;37(2):134-143
22. Hagg U, Taranger J. Maturation indicators and the pubertal growth spurt. *Am J Orthod* 1982;82(4):299-309.

**Corresponding Author**

Dr. Akshi Rathee  
Post Graduate Student,  
Department of Orthodontics,  
Subharti Dental College,  
Meerut, Uttar Pradesh – 560061.  
Email Id: - rathee\_kin@yahoo.co.in