

PROSTHETIC REHABILITATION OF MANDIBULAR ATROPHIED RESIDUAL ALVEOLAR RIDGE UTILIZING NEUTRAL ZONE APPROACH: A CASE REPORT

Manu Rathee¹, Amit Kumar Tamrakar², Mohaneesh Bhoria³, Priyanka Boora⁴

1. Senior Professor and Head, Department of Prosthodontics, Post Graduate Institute of Dental Sciences, Rohtak, Haryana

2. Assistant Professor, Department of Prosthodontics, Faculty of Dentistry, Jamia Milia Islamia, New Delhi

3. Demonstrator, Department of Prosthodontics, Post Graduate Institute of Dental Sciences, Rohtak, Haryana

4. Post Graduate Student, Department of Prosthodontics, Post Graduate Institute of Dental Sciences, Rohtak, Haryana

Abstract

Prosthetic management of patients with atrophic residual alveolar ridges is often challenging because of ongoing process of diminution of the denture bearing foundation with time. However, in spite of available pre-prosthetic treatment approaches, such as various pre-prosthetic surgeries, and modern treatment approach such as dental implant therapy, as a means of improving the denture bearing foundation, fabrication of complete dentures using the neutral zone approach in case of atrophied residual ridge is the most utilized technique. As one of the prime objective of complete denture prosthodontics is to fabricate a virtually undetectable prosthesis that simulate harmonious positions and relationship with the adjacent tissue. This virtually undetectable 3-dimensional positioning of prosthesis can be easily achieved with neutral zone technique. This report describes a case of atrophic mandibular ridge using the neutral zone technique.

Key words: - Mandibular Atrophied Alveolar Ridge; Complete Denture Stability; Neutral Zone

Introduction

Complete denture prosthodontics consistently aimed at providing comfort, function, esthetic, and the maintenance of patient's health to ultimately improve Quality of life of patient. Fabrication of complete denture, as a virtually undetectable prosthesis, that simulate harmonious positions and relationship of the lost natural teeth during speech, mastication, and at rest is often difficult to attain. The attainment of this virtually undetectable 3-dimensional positioning of prosthesis has been debatable topic since long time.¹

Included in this effort is the evolution of concepts of neutral zone or potential denture space. According to glossary of Prosthodontic terms (2005) neutral zone is defined as "the potential space between the lips and cheeks on one side and the tongue on the other; that area or position where the forces between the tongue and cheeks or lips are equal."²

The neutral zone is the zone in the oral cavity, where, the pressure generated by lips and cheek musculature is neutralized by pressure exerted by the tongue during the functional activity of the mouth.³

Sir Wilfred Fish (1948) concluded that complete dentures polished surfaces has role in achieving denture retention and stability. The polished surfaces which contact cheeks, lips and tongue, together determine the neutral zone. It has been reported that patients with complete dentures that were fabricated based on the neutral zone concept showed improved mastication and speech, and reduced cheek biting. Also, utilization of neutral zone concept for denture fabrication in post-mandibular resection successfully improved patient comfort and absence of cheek, lips and tongue biting.^{4,5}

This report elaborates on a 65 years old male patient with mandibular atrophic ridge treated by utilizing the neutral zone approach to fabricate a virtually undetectable 3-dimensional prosthesis.

Case Report

A 65 years old male patient presented with chief complaint of loose upper and lower complete dentures with marked discomfort while talking and eating. History revealed period of edentulism for the last 8-9 years and had worn same set of complete dentures since then.

Evaluation of previous prosthesis revealed severe loss of occlusal table of prosthetic teeth, staining of all surfaces and repaired fracture denture part. On intra oral examination revealed a severely resorbed mandibular alveolar ridge. (Figure 1)

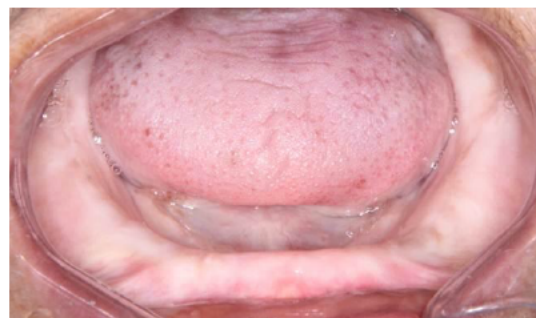

Figure 1: Intraoral view of mandibular residual ridge

It was decided that a new complete denture would be provided to the patient using the neutral zone approach so that the retention and stability of the mandibular dentures could be improved. Option of mandibular implant retained over denture remained unfeasible as the expense of the treatment was unaffordable by the patient.

Clinical Procedure

- **Impressions of atrophied residual ridges:** Preliminary impressions of arches were recorded with impression compound using metallic stock trays. Primary casts were poured and custom trays were prepared using auto-polymerizing acrylic resin. After evaluation of extensions of the custom trays in both passive and active muscle movement, border molding and wash impressions were functionally recorded. The master

casts were poured and prepared for temporary denture base fabrication using heat-cure acrylic resin.

- **Recording maxilla-mandibular relation:** After evaluation of extensions, retention and stability of the record bases intra orally occlusion rims were made. The adjustment of occlusion rims intra-orally done to permit an acceptable occlusal vertical dimension (OVD) and a 2mm of freeway space. Centric relation was attained using swallowing technique and registered using static method. The upper and lower master casts with the occlusal rims were mounted on a mean value articulators.
- **Neutral zone approach:** The mandibular occlusion rim was removed and replaced with wire loops which were then attached to the temporary denture base. The height of mandibular occlusion rim was maintained anteriorly by wire loop itself and posteriorly by two compound stopper. (Figure 2, 3)

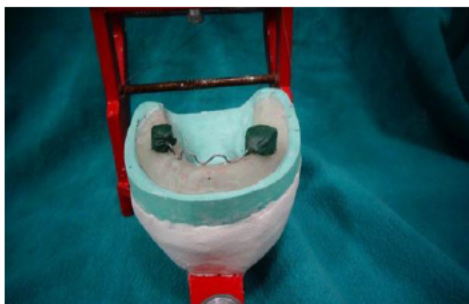

Figure 2: Mounted mandibular cast with vertical stops

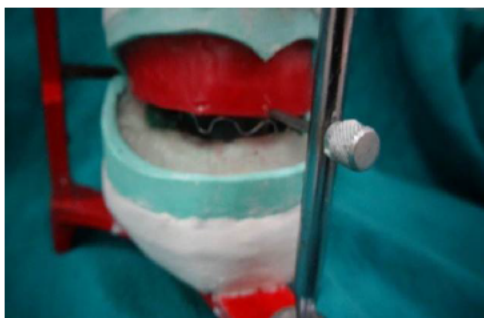


Figure 3: Mounted mandibular cast with maintained vertical dimension

- a. **Recording of the Neutral Zone Impression:** Evaluation of bucco-lingual position of the wire loops done intra-orally and the free-way space assessment was done again. Impression compound was adapted over the wire loops and then it was placed in the oral cavity of the patient. Then the patient was instructed to perform various functional oral movements of his lips, tongue and the cheek. These movements included puckering of lips, full smile and mouth opening to simulate physiological movements. (Figure 4)

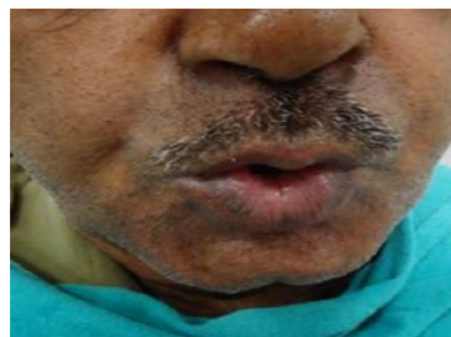

Figure 4: Patient performing functional movements

During these functional movements care was taken to ensure that the occlusal contacts between the maxillary and mandibular occlusal rims were maintained. The neutral zone in the patient's oral cavity was recorded with the help of functional moulding of the impression compound material, when the patient was instructed to perform functional movements. These movements were performed and repeated again after which the record base was removed along with the finished neutral zone impression.⁶

- b. **Putty matrix adaptation and conversion procedure:** Maxillary prosthetic teeth arrangement carried out and a multi-part silicone putty matrix adapted over recorded mandibular neutral zone impression compound template. (Figure 5) After material was set, the wire-loops along with the impression compound neutral zone templates were removed and were replaced with base plate wax using the putty matrix and mandibular prosthetic teeth arrangement was done. These were then returned chair-side so that try in could be carried out conventionally.

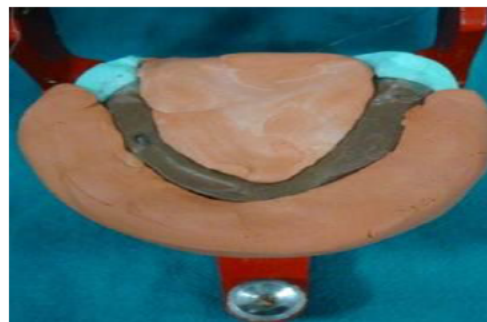

Figure 5: Neutral zone delineated by putty matrix

- **Try In:** Try in of the maxillary and mandibular denture was performed. The trial dentures showed good stability and satisfactory retention. Then the trial dentures were acrylized, finished and polished.
- **Insertion and Follow-up:** The dentures were fitted into the patient's mouth. (Figure 6) The patient was recalled for follow up regularly. The patient was pleased and reported satisfaction with his new set of dentures.

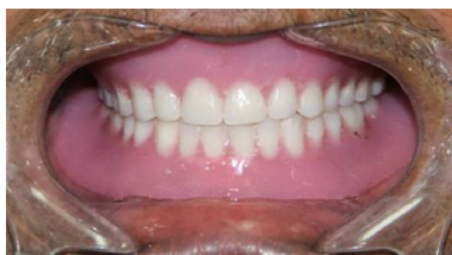

Figure 6: Maxillary and mandibular complete dentures in intercuspation

Discussion

Attainment of retention and stability in complete denture becomes a challenge especially in atrophied residual ridges. Fabrication of complete dentures using neutral zone technique can be helpful in overcoming these challenges. Rehabilitation using dental implants can also be a good option, but they also have various limitations and contraindications (systemic condition of the patient, cost of the treatment). In such cases, neutral zone technique can be a better alternative. This technique can result in more stable denture and better retention during functional movements. Also, the dentures made using neutral zone technique provide better facial support thus better esthetic results. It also helps in reducing the food entrapment beneath the dentures, and guides for positioning of the prosthetic teeth in posterior region, resulting in adequate tongue space.⁷ Fish EW in the year 1933 was the first to introduce the role of muscles on stabilizing mandibular complete dentures.⁸ Various studies have outlined the advantage of neutral zone technique to improve the stability of mandibular complete dentures.⁹⁻¹⁵ This technique is not only helpful in edentulous patients but also for patients with oral deformities.

The technique used for recording neutral zone in this case report is simple, easy and convenient to carry out. Impression compound was preferred to obtain the neutral zone. It is a high viscous material, and it facilitates multiple molding, can be soften enough, once molded maintain its shape. Also, it is tasteless, odourless and easily available, economical material. The material also has appreciable working time and all the functional movements of the oral musculature can be recorded during the muscle activities. However, the only disadvantage of the neutral zone approach is increased laboratory time as well as clinical chair-side time for recording the neutral zone.

Conclusion

Following prosthetic rehabilitation of edentulous cases, the oral cavity has to manage substantial volume of prosthesis. Application of neutral zone in rehabilitation process, to fabricate a virtually undetectable prosthesis that simulates harmonious positions and relationship to the costal anatomical entities surrounding denture peripheries, proved advantageous. Retention and stability of dentures are greatly improved, especially in the atrophic ridges.

When implant retained over-denture are economically unfeasible, the neutral zone technique provides an

alternative, time-saving, cost effective and relatively convenient way to obtain a favourable result. Considering the benefits of this technique, clinicians should adopt neutral zone approach in their routine prosthodontic management of edentulous patients.

References

1. Cagna DR, Massad JJ, Schiesser FJ. The neutral zone revisited: From historical concepts to modern application. *J Prosthet. Dent.* 2009;101(6):405-412.
2. Glossary of Prosthodontic Terms (8th ed). *J Prosthet Dent* 2005;94:10-92.
3. Beresin VE, Schiesser FJ. The neutral zone in complete and partial dentures C.V. Mosby Co., 1978. p 15.
4. Lynch CD, Allen PF. Overcoming the mandibular unstable denture: The neutral zone impression technique. *Dent Update.* 2006;33(1):21-2, 24-6.
5. Ohkubo C, Hanatani S, Hosoi T, Mizuno Y. Neutral zone approach for denture fabrication for a partial glossectomy patient: a clinical report. *J Prosthet Dent.* 2000;84(4):390-393.
6. Rashid H, Vohra FA, Haidry TZ, Karmani GD. Stabilizing mandibular complete dentures using the neutral zone impression technique. *J Pak Dent Assoc* 2013;22(2):154-159.
7. Gahan MJ, Walmsley AD. The neutral zone impression revisited. *Br Dent J* 2005;198(5):269-272.
8. Fish EW. Using the muscles to stabilize the full lower denture. *J Am Dent Assoc* 1933;20:2163-2169.
9. Beresin VE, Schiesser FJ. The neutral zone in complete dentures. *J Prosthet Dent* 1976;36(4):356-367.
10. Fahmy FM, Kharat DU. A study of the importance of the neutral zone in complete dentures. *J Prosthet Dent.* 1990;64(4):459-462.
11. Fahmy FM. The position of the neutral zone in relation to alveolar ridge. *J Prosthet Dent* 1992;67(6):805-809.
12. Murphy WM. The neutral zone and the polished surfaces of full dentures. *Dent Practit* 1996;16:244-248.
13. Makzoume JE. Morphologic comparison of two neutral zone impression techniques: A pilot study. *J Prosthet Dent* 2004;92(6):563-568.
14. Gupta KL, Agarwal S. Salvation of a severely resorbed mandibular ridge with a neutral zone technique. *Indian J Dent Res* 2011;22(6):883.
15. Rehmann P, Zengin M, Westmann B. Alternative procedure to improve the stability of mandibular complete dentures: a modified neutral zone technique. *Int J Prosthodont.* 2012;25(5):506-508.

Corresponding Author

Dr. Manu Rathee

Senior Professor and Head,
Department of Prosthodontics,
Post Graduate Institute of Dental Sciences,
Pt. B.D Sharma University of Health Sciences
Rohtak, Haryana
E-mail: ratheemanu@gmail.com