FABRICATION OF A GLOVE TYPE SILICONE FINGER PROSTHESIS: A CASE REPORT

Pulkit Jain,[1] Gurleen Arora,[2] Ajay Yadav,[3] Sumit Aggarwal,[4]

1. Post Graduate Student, Department of Prosthodontics, Subharti Dental College, Meerut, Uttar Pradesh
2 & 4. Reader, Department of Prosthodontics, Subharti Dental College, Meerut, Uttar Pradesh
3 Post Graduate Student, Department of Orthodontics, Subharti Dental College, Meerut, Uttar Pradesh

Abstract

The hand has basic functions like grasping and feeling. It is also a means of communication through body language. Finger and partial finger amputations are some of the most frequently encountered forms of partial hand loss. The most common causes of these amputations are trauma, congenital absence or malformations. All of these may present similar clinical challenges. Finger deformities affect aesthetics and function of hand severely compromising and also cause psychological disturbances. This clinical report describes the fabrication of a silicone glove type finger prosthesis for a 30 years old male patient with missing upper 2/3 rd part of the little finger of the right hand after injury at work. The glove type finger prosthesis was retained by a vaccum effect on stump. The glove type finger prosthesis offered psychological, functional and rehabilitative advantages for the patient restoring the natural appearance with the prosthesis. This prosthesis also eliminated the trauma generated by dysfunction and represented an efficient psychological therapy.

Key words: Finger amputation, Finger prosthesis, Maxillofacial prosthesis.

Introduction

Finger or partial finger amputations are the most frequently encountered forms of partial hand loss. The most common causes of these are traumatic injuries, congenital absences or malformations. Finger absence causes loss of grasp, security and marked psychological trauma to the patient.[1]

Beasley has noted that individuals who keep their hands inside pockets due to embarrassment over appearance are as functionally disabled as a forequarter amputee.[2]

Restoring the digit with a functional prosthesis with matching form, colour, and texture will enhance patients' acceptance and confidence. The most common methods of retaining a digital prosthesis are by vacuum effect on the stump, use of a ring at the junction of prosthesis and stump.[3] and the use of osseointegrated implants with customized attachments.[4, 5]

Painful hypersensitivity has been reported, especially at the end of finger remnants after amputation. It has been documented that the same can be alleviated with the use of gentle pressure exerted by silicone prosthesis.[6]

This report presents a case of rehabilitation of a finger defect following amputation after a snake bite with silicone prosthesis and describes a method of retention for the same.

Case report

A 56 year old male patient reported to the Department of Prosthodontics, Subharti Dental College, Meerut, Uttar Pradesh, for the replacement of the missing upper 2\3 rd part of the little finger of the right hand. His chief complaint was loss of grip and disagreeable appearance. History revealed that the amputation was done at the upper 2\3 rd part of little finger 3months back. Amputation had to be made following a snake bite while working in the fields as the patient was a farmer by occupation. After the incident the patient developed contractures on the effected hand. A contracture is a permanent shortening of a muscle or joint.[7] It is usually in response to prolonged hypertonic spasticity in a concentrated muscle area.

The surrounding area appeared to be normal with no signs of any inflammation . After clinical evaluation of the defect it was concluded that the amputed finger was acceptable for prosthetic rehabilitation. An informed consent was taken from the patient before starting the treatment to ensure his willingness and co-operation.

The patient was convinced for the rehabilitation of missing upper 2/3 rd part of the little finger with glove type finger prosthesis.

A single layer of modelling wax was adapted over the amputated finger (Figure 1) which would act as a spacer prior to making of the impression with addition silicone impression material (Affinis, Coltène Whaledent).

Figure 1: Wax spacer on the amputated finger

This would serve as a preliminary mold from which the wax spacer is now removed and light body silicone (Affinis, Coltène Whaledent) impression material is introduced for the surface details. Impression was then poured with ADA type IV dental stone (Kal Rock, Kala

Bhai Karson Pvt.) to create positive replica of the amputated finger. (Figure 4)

Figure 2: Putty P.V.S. impression over the wax spacer

Figure 3: Final impression with light body P.V.S. material

The model was scored by reducing the overall diameter by scraping of 0.5 mm uniformly. A ring-shaped depression of about 1mm depth and 1mm width was made with round tungsten carbide bur. The wax pattern was fabricated and tried on the patient. (Figure 4)

Figure 4: Wax try-in

Nail bed preparation was done by creating an undercut beneath the cuticle margin that would function to retain the self-cured acrylic resin nail within the wax pattern after the polymerization. Two screws were incorporated on the nail bed which would later aid in retention of the acrylic resin nail with the silicone prosthesis after polymerization (Figure 5).[8]

Figure 5: Nail bed preparation and embedded screw heads for retention

Now the pattern was transferred on the model and carefully sealed and flasked to enhance the accuracy at the stage of shade matching such that the dorsal and the palmer aspects of the finger were separable, separating medium is applied between the two pours. After dewaxing, the mould is allowed to cool. (Figure 6)

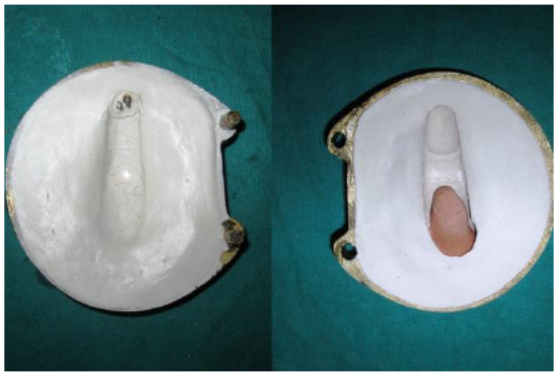

Figure 6: Mould after de-waxing

Shade matching was done using natural daylight. The best time for this procedure was between 11 am to 1 pm .The room temperature vulcanising silicone (MP SAI mumbai) was used to matched intrinsically with the dorsal and palmer surface of finger. It is essential to carry out this procedure in front of the patient so as to gain approval. The base colour of the prosthesis was matched with the ventral and dorsal surface of the hand (Figure 7).

Figure 7: Shade Matching

Petroleum jelly (Vaseline, Johnson & Johnson) was applied to the moulds and coloured silicone was then layered into the mould, and the flask was closed applying light pressure. Excess material was removed and was bench cured overnight. Once the final prosthesis was retrieved, the flash was trimmed using a sharp pair of scissors. Self-cured acrylic resin nail was fabricated, finished and polished. The fit and shade of the finger prosthesis was evaluated on the patient. For better colour/shade matching, extrinsic colouration was applied on the dorsal and ventral areas of the finger prosthesis under daylight (Figure 8), two rings welded together were used to secure the prosthesis on the little finger with the ring finger for added retention.

Homecare instructions involving the use of a soft brush, soap, and warm water irrigation were given, and the patient was instructed to come back after 2 months for a recall check-up. Recall examination revealed healthy skin at the amputation site and good retention of the prosthesis.

Figure 8: Final prosthesis secured with rings

Discussion

Loss of any finger affects esthetics and functionality, greatly impacting dexterous individuals.[9] Most cases involving distal phalangeal amputations can be restored to near normal functionality using appropriate prostheses.[10,11] Customized silicone prostheses have a wider rate of acceptance, owing to their comfort, durability, and stain resistance, which are superior than other available extraoral maxillofacial materials. Additional functional benefits of silicone prostheses include desensitization and protection of the painful hypersensitive tissue at the amputation site by constant gentle pressure exerted over the affected area. It has also been speculated that silicone gel improves the hydration of the stratum, making the scar tissue more pliable and comfortable. Various methods of retention are available (i.e., using rings over the margins of the finger prosthesis, using medical grade adhesive, or by implant-retained prosthesis). In the patient here, the positive model was rectified to create suction for retention. It is possible to ensure enhanced retention by creating grooves in the positive model, thus creating a vacuum chamber.[9]

Conclusion

The custom-made finger prosthesis is esthetically acceptable and comfortable for use in patients with amputated fingers, resulting in psychological improvement and personality. An esthetic and retentive prosthesis are the primary determinant factors in the successful prosthetic restoration of a finger. There are many methods of retention such as implant and adhesives. An alternate method using both suction and vacuum was attempted and found to be quite successful. Such restorations are successful when finger prostheses are individually sculpted and coloured in situ.

References

1. Kaira LS, Katna V. Glove Type Silicone Finger Prosthesis - A Case Report. Ind J Dent Sciences 2012;4(2):40-41.
2. Beasley RW. General consideration in managing upper limb amputations. Orthop Clin North Am 1981:12(4);743-749.
3. Scolozzi P, Jaques B. Treatment of midfacial defects using prostheses supported by ITI dental implants. Plast Reconstr Surg. 2004;114(6):1395-1404.
4. Lundborg G, Branemark PI, Rosen B. Osseointegrated thumb prostheses: a concept for fixation of digit prosthetic devices. J Hand Surg Am 1996;21(2):216-221
5. Aydin C, Karakoca S, Yilmaz H. Implant-retained digital prostheses with custom-designed attachments: a clinical report. J Prosthet Dent 2007;97(4):191-195
6. Livingstone DP. The D-Z stump protector. Am J Occup Ther 1988;42(3):185-187
7. Clavet H, Hébert PC, Fergusson D, Doucette S, Trudel G. Joint contracture following prolonged stay in the intensive care unit. CMAJ 2008;178(6):691-697.
8. Thomas KF, Prosthetic Rehabilitation (ed 1). Chicago, Quintessence, 1994.
9. Jacob PC, Shetty KH, Garg A, Pal B. Silicone finger prosthesis. A clinical report. J Prosthodont 2012;21(8):631–633.
10. Larcher S, Espen D. Post-acute management of fractures of the proximal interphalangeal joint with metal prosthesis: first experience. Handchir Mikrochir Plast Chir 2007;39(4):263-266
11. Onishi Y, Fujioka H, Doita M. Treatment of chronic posttraumatic hyperextension deformity of proximal interphalangeal joint using suture anchor: a case report. Hand Surg 2007;12(1):47-49

Corresponding Author

Dr. Pulkit Jain
Post Graduate Student,
Department of Prosthodontics,
Subharti Dental College,
Meerut, Uttar Pradesh, INDIA
Email: - drjainpulkit@gmail.com