

# A REASONABLE SMILE WITH COMPONEERS: A CASE REPORT

Chaturvedi A,<sup>1</sup> Singh A<sup>2</sup>

1. Post Graduate Student, Department of Prosthodontics, Crown Bridge and Implantology, SPPGIDMS, Lucknow, Uttar Pradesh

2. Professor & Head, Department of Prosthodontics, Crown Bridge and Implantology, SPPGIDMS, Lucknow, Uttar Pradesh

## Abstract

Smile, a person's ability to express a range of emotions with the structure and movement of the teeth and lips, can often determine how well a person can function in society. New ceramic and composite materials have increased conservative treatments of compromised anterior teeth. Veneers are a popular treatment option for several reasons. They are also used to correct uneven spaces or a diastema, chipped or worn out teeth. A 26 year old female patient- concerned about her smile reported to the out patient department. Clinical examination reveals spacing between central incisors and lateral incisors, also revealing previous incomplete orthodontics treatment. Mock preparations and wax up was done and shown to the patient. And a minimal preparation was performed. Composite Veneers were fabricated and luted in the patients mouth. Indirect composite resins were introduced to overcome the drawbacks of direct composite resins (polymerization shrinkage, loss of marginal integrity and microleakage). Additional clinical benefits include not only precise marginal integrity, wear resistance that is similar to enamel and wear compatibility with opposing natural dentition but also ideal proximal contacts, excellent anatomical morphology and optimal aesthetics.

**Key words:** Componeers, Diastema, Minimal invasive, Shrinkage.

## Introduction

A considerable number of studies have shown that people are more concerned about missing anterior teeth and their replacement than about posterior ones as esthetics seems to be more important than the function of the teeth.<sup>1</sup> Smile, a person's ability to express a range of emotions with the structure and movement of the teeth and lips, can often determine how well a person can function in society.

New ceramic and composite materials have increased conservative treatments of compromised anterior teeth.<sup>2</sup> For many years, the most predictable and durable aesthetic correction of anterior teeth has been achieved by the preparation of full crowns. However, this approach is undoubtedly most invasive with substantial removal of large amounts of sound tooth substance and possible adverse effects on adjacent pulp and periodontal tissues.<sup>3</sup> The concept of no-preparation or minimal-preparation has followed the development of appropriate enamel bonding procedures.<sup>4</sup>

A number of clinical studies have concluded that bonded laminate veneer restorations delivered good results over a period of 10 years and more.<sup>5-6</sup> The majority of the failures were observed in the form of fracture or marginal defects of the restoration.<sup>7</sup> Pure adhesive failures are rarely seen when enamel is the substrate with shear bond strength values exceeding the cohesive strength of enamel itself.<sup>8-9</sup>

Veneers are a popular treatment option for several reasons. They are generally placed on upper front teeth that are severely discoloured, poorly shaped or slightly crooked. They are also used to correct uneven spaces or a diastema, chipped or worn out teeth.<sup>10</sup>

## Diagnosis and treatment planning

A 26 year old female patient-concerned about her smile reported to the outpatient department. Clinical examinations reveal spacing between central incisors and lateral incisors. Also history reveals previous incomplete orthodontic treatment (figure 1).

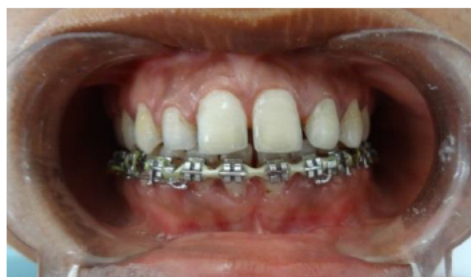

Figure 1: - Pre Operative View

During the first appointment photographic and radiological records were collected; upper and lower diagnostic impressions were taken and casts were fabricated in type III dental stone.

The preliminary mock up wax up of the maxillary centrals and laterals were done in white ivory wax according to golden proportion, checked by a golden proportion template and the mock up work was checked and approved by the patient and a written consent was taken from the patient. (figure 2)

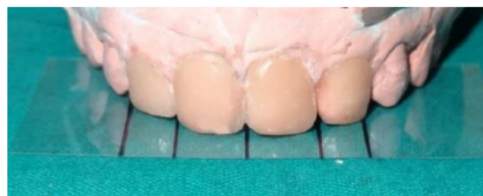

Figure 2: - Mock Wax Up and Preparation of a Template in accordance with golden proportion

## Preparation and Impression

During second visit a minimal preparation was done in maxillary central incisors and lateral incisors. A wrap around design was followed. The final preparations were finished by a fine grit bur.

Following the preparation, an impregnated retraction cord (000) was left in sulcus for 5 minutes (figure 3) and after

that putty- light body wash relin impression was made using additional silicone material.

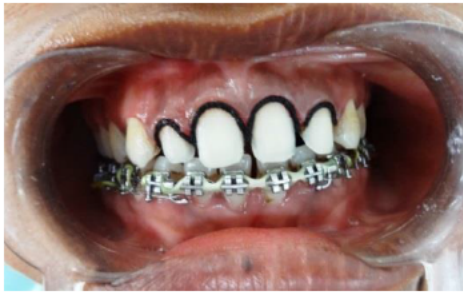

Figure 3: - Prepared and retracted teeth

### Laboratory Phase

The final impression was disinfected and casts were fabricated in Type IV die stone (Kalabhai MUMBAI). On the diagnostic wax up, putty index was made to fabricate the final prosthesis according to the approved diagnostic wax up. A light-cured hybrid composite (SOLIDEX SHOFU) was positioned at the inner surface of a silicon index and composite restorations of the four upper incisors were baked on the working model, and crowns were fabricated as per manufactures' instructions (SOLIDITE, SHOFU) (figure 4).



Figure 4: - Curing Inside Curing Chamber (Solidite Shofu)

The golden proportion template was used to check the distal boundaries of the fabricated prosthesis.

No die spacer was used on dental cast so as to achieve optimal adaptation of the restoration with minimal thickness of resin composite cement. Microtextures detailing was accomplished with rotary finishing and polishing instruments (SOLIDEX Finishing & Polishing Kit SHOFU). Composite restorations were finally refined: the adjustment of rough contours and polishing with stones (Dura-green stones, Shofu Dental GmbH, Ratingen, Germany) and disks (Sof-Lex, 3M ESPE) allowed the fabrication of life-like veneers. Definitive restorations were seated on the working model. The prosthesis was finally polished by polishing paste (DURA-POLISH and DURA-POLISH DIA SHOFU).

### Luting

On the subsequent visit placement of the final veneers and a try-in was carried out. The teeth were cleaned with pumice and dried and the marginal adaptation was checked. The

inner surface of the sectional veneers was sandblasted with 50 micron  $Al_2O_3$  for 10 seconds at 2.8 bar pressure; the indirect restorations were ultrasonically cleaned to remove any remnants of alumina particles.

Restorations were slowly seated on their respective teeth preparations; pressure was applied in order to facilitate adaptation and flow of the luting agent (RelyX™ U200, 3M. ESPE, Germany). While handling the veneers in place, excess resin cement was carefully removed using a sickle-shaped scaler (A.P.I., Germany). Glycerine gel was applied at the margins to prevent an oxygen inhibition layer at the interface. Margins were finished and polished with diamond burs, rubber points, and diamond polishing paste.

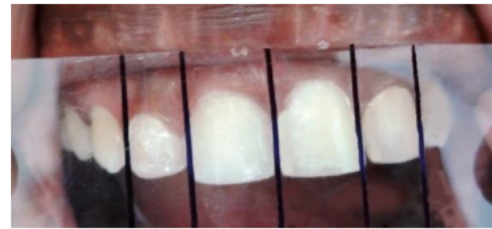


Figure 5: - Post operative with Template

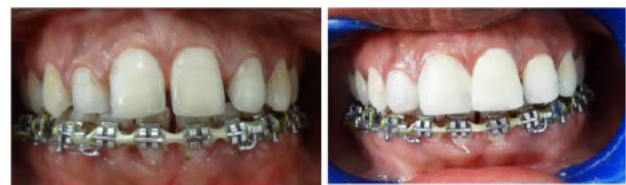

Figure 6: - Pre operative and Post-operative

### Discussion

The cosmetic improvement of the smile is possible with both direct<sup>11,12</sup> and indirect techniques<sup>13,14</sup>; the latter procedures might require more than one appointment but are preferred when multiple teeth are involved in the treatment plan and accurate tooth reshaping or colour matching is needed.<sup>13</sup>

Indirect composite resins were introduced to overcome the drawbacks of direct composite resins (Polymerization shrinkage, loss of marginal integrity, and microleakage). Additional clinical benefits include not only precise marginal integrity, wear resistance similar that is similar to enamel and wear compatibility with opposing natural dentition but also ideal proximal contacts, excellent anatomical morphology and optimal aesthetics. This is as a result of a higher degree of conversion obtained from the utilization of different polymerization procedures that involve heat, pressure, light, and vacuum or nitrogen atmosphere. The degree of conversion increases when multifunctional monomers are present, offering extra reactive sites that enlarge the polymer chains. Better mechanical properties may also be ensured through reinforcements of glass and polyethylene fibres added to indirect composite resin materials.<sup>15-17</sup>

In this case report, a composite material has been selected due to its quick and inexpensive delivering; a light-curing,



ceramic filled, micro-hybrid composite with organic particles in its structure which are impregnated with and enveloped in silanised microfillers was preferred to porcelain due to the ease of handling in the try-in and luting procedures. Fractures of resin composite materials could also be simply repaired with direct chair side techniques.<sup>18</sup>

While the scientific literature is more extensive for ceramic laminates, a recently published clinical trial (with a 3-years follow-up) has reported no significant difference in the survival rate of composite (87%) and ceramic (100%) veneers; on the other hand, some surface quality changes were more frequently observed for the resin materials (i.e., minor voids and defects and slight staining at the margins).<sup>19</sup> In addition, the survival rate and clinical performance of composite or ceramic laminate veneers were not significantly influenced when bonded onto intact elements or onto teeth with pre-existing composite restorations (when no caries or infiltration is present, of course).<sup>20,21</sup> As a final recommendation, like after the delivering of many other types of indirect restorations, the dentist should plan a careful follow-up program and give patients appropriate instructions for maintenance and preservation of the obtained success.

### Conclusion

The final prosthesis delivered to the patient was acceptable to the patient in form and function. The composite system is less expensive than porcelain. This followed the minimal preparation technique.

### References

1. Elias AC, Sheiham A. The relationship between satisfaction with mouth and number and position of teeth. *J Oral Rehabil* 1998;25(9):649–661.
2. Peumans M, Van Meerbeek B, Lambrechts P, Vanherle G. Porcelain veneers: a review of the literature. *J Dent* 2000;28(3):163–77.
3. Van Meerbeek B, Vanherle G, Lambrechts P, Braem M. Dentin- and enamel- bonding agents. *Curr Opin Dent* 1992;2:117–27.
4. Magne P, Hanna J, Magne M. The case for moderate, “guided prep” indirect porcelain veneers in the anterior dentition. The pendulum of porcelain veneer preparations: from almost no-prep to over-prep to no-prep. *Eur J Esthet Dent* 2013;8(3):376–88.
5. Layton DM, Walton TR. The up to 21-year clinical outcome and survival of feldspathic porcelain veneers: accounting for clustering. *Int J Prosthodont* 2012;25(6):604–612.
6. Layton DM, Clarke M, Walton TR. A systematic review and meta-analysis of the survival of feldspathic porcelain veneers over 5 and 10 years. *Int J Prosthodont* 2012;25(6):590–603.
7. Peumans M, De Munck J, Fieuws S, Lambrechts P, Vanherle G, Van Meerbeek B. A prospective ten-year clinical trial of porcelain veneers. *J Adhes Dent* 2004;6(1):65–76.
8. Ozturk E, Bolay S, Hickel R, Ilie N. Shear bond strength of porcelain laminate veneers to enamel, dentine and enamel-dentine complex bonded with different adhesive luting systems. *J Dent* 2013;41(2):97–105.
9. Marshall SJ, Bayne SC, Baier R, Tomsia AP, Marshall GW. A review of adhesion science. *Dent Mater* 2010;26(2):e11–e16.
10. Mangani F, Cerutti A, Putignano R, Bollero R, Madini L. Clinical approach to anterior adhesive restorations using resin composite veneers. *Eur J Esthet Dent* 2007;2(2):188–209.
11. Korkut B, Yanıkoğlu F, Günday M. Direct composite laminate veneers: Three case reports. *J Dent Res Dent Clin Dent Prospects*. 2013;7(2):105–111.
12. Zorba YO, Bayindir YZ, Barutcuğil C. Direct laminate veneers with resin composites: two case reports with five-year follow-ups. *J Contemp Dent Pract* 2010;11(4):E056–E062.
13. Mangani F, Cerutti A, Putignano A, Bollero R, Madini L. Clinical approach to anterior adhesive restorations using resin composite veneers. *Eur J Esthet Dent* 2007;2(2):188–209.
14. Horvath S, Schulz CP. Minimally invasive restoration of a maxillary central incisor with a partial veneer. *Eur J Esthet Dent* 2012;7(1):6–16.
15. Tam LE, McComb D. Shear bond strengths of resin luting cements to laboratory made composite resin veneers. *J Prosthet Dent* 1991;66(3):314–21.
16. Mandikos MN, McGivney GP, Davis E, Bush PJ, Carter JM. A comparison of the wear resistance and hardness of indirect composite resins. *J Prosthet Dent* 2001;85(4):386–95.
17. Miranda CB, Pagani C, Bottino MC, Benetti AR. A comparison of microhardness of indirect composite restorative materials. *J Appl Oral Sci* 2003;11(2):157–61.
18. Maneenut C, Sakoolnamarka R, Tyas MJ. The repair potential of resin composite materials. *Dent Mater* 2011;27(2):e20–e27.
19. Gresnigt MM, Kalk W, Özcan M. Randomized clinical trial of indirect resin composite and ceramic veneers: up to 3-year follow-up. *J Adhes Dent* 2013;15(2):181–190.
20. Gresnigt MM, Kalk W, Özcan M. Randomized controlled split-mouth clinical trial of direct laminate veneers with two micro-hybrid resin composites. *J Dent* 2012;40(9):766–775.
21. Gresnigt MM, Kalk W, Özcan M. Clinical longevity of ceramic laminate veneers bonded to teeth with and without existing composite restorations up to 40 months. *Clin Oral Investig* 2013;17(3):823–832.

### Corresponding Author

Dr. Anshuman Chaturvedi,  
B-20, J- Road,  
Mahanagar Extension,  
Lucknow. (U.P.) 226002.  
Email- dranshumanchat@gmail.com