

RECURRENT AMELOBLASTOMA OF THE MANDIBLE

Uvaraja S,¹ Thawfeek M,² Ramesh V,³ Daniel JM⁴

1. Post Graduate Student, Department of Oral Medicine & Radiology, MGPGI, Pondicherry, Puducherry.
2. Post Graduate Student, Department of Oral Pathology & Microbiology, MGPGI, Pondicherry, Puducherry.
3. Professor & Head; Dean, Department of Oral Pathology & Microbiology, MGPGI, Pondicherry, Puducherry.
4. Professor & Head; Associate Dean, Department of Oral Medicine & Radiology, MGPGI, Pondicherry, Puducherry.

Abstract

Ameloblastoma is the second most common odontogenic tumor of the oral cavity with the primary site being the mandible. The ratio of maxillomandibular involvement is 5:1 in favor of the mandible. The most common complaint is a painless swelling over the mandibular area. Despite its benign nature, ameloblastoma has a high local recurrence rate, with the most recurrences seen within 5 years after surgery. Biopsy and radiological evaluation may be helpful in differentiating the subtypes of ameloblastoma. A case of a male individual with an extensive recurrent ameloblastoma that happened to involve right and left lower mandible is being reported.

Keywords: Odontogenic tumor. Recurrent. Ameloblastoma. Mandible.

Introduction

Ameloblastoma is a unique neoplasm of the jaws arising from odontogenic epithelium presenting in a variety of clinico-radiological and histological forms. It often presents as a slow growing, painless swelling causing expansion of the cortical bone, perforation of the lingual and / or buccal plates and infiltration of soft tissue. There is often delay in the diagnosis because of its slow-growing nature.¹

Ameloblastoma represents 1 % of all tumors and cysts that involve the maxillomandibular area and about 10 % of the odontogenic tumors. The ratio of maxillomandibular involvement is 5:1 in favor of the mandible, and the most common site of occurrence is the mandibular molar region. It is primarily seen in adults in the third decade of life, with equal sex predilection.²

In this report, we aim to present a case of recurrent ameloblastoma in a male patient in the seventh decade. The tumor invaded the entire left and half of the right mandibular region. We report this case because to the best of our knowledge, there are only few cases with such extension reported in the literature.

Case report

A 70 year old male patient reported to the department of oral medicine and radiology with a chief complaint of pain and swelling in the left side lower third of face since one month.

History of the present illness, the patient was asymptomatic 13 years before, when he sustained injury to lower front jaw, in the year 1996, for which he was treated in a general hospital. During that time he was diagnosed with ameloblastoma in relation to left lower jaw which was confirmed by biopsy. Patient gave a history of surgical reconstruction in the left side mandible before 12years. Followed by that the patient remained asymptomatic for the past 12 years and a month back he developed pain and swelling. There was no relevant medical history.

Extra oral examination revealed mild facial asymmetry due to a diffuse swelling at the left side lower third of face extending anteroposteriorly from symphysis to tragus, superiorly the swelling is in line with commissure and inferiorly 2 cm beyond the inferior border of mandible. The skin overlying the swelling appeared normal with no

secondary surface changes like ulceration, sinus opening. On palpation the swelling was smooth in texture, firm to hard in consistency and tender. [Figure.1]

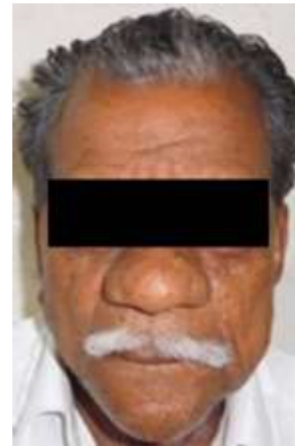

Figure 1: Extra oral examination revealed mild facial asymmetry due to a diffuse swelling at the left side lower third of face extending anteroposteriorly from symphysis to tragus.

On intra oral examination, a diffuse swelling of size approximately 7×2 cm was present extending from the mesial aspect of 44 crossing the mid-line and extending to the left retromolar region, mucosa overlying the swelling appeared normal with no evidence of ulceration, sinus opening or pus discharge. On palpation the swelling was soft to firm consistency on the labial aspect and firm to hard in the lingual aspect with evidence of buccal and lingual cortical expansion.[Figure.2]

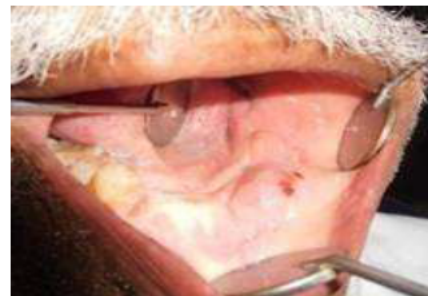

Figure 2: On intra oral examination, a diffuse swelling was present extending from the mesial aspect of 44 crossing the mid-line and extending to the left retromolar region.

Teeth 31,32,33,34,35,36,37,41,42 and 43 were clinically missing and there was grade I mobility in relation to 44,45. On the basis of history and clinical presentation a provisional diagnosis of odontogenic tumor most likely recurrent ameloblastoma was given.

The differential diagnosis included unicystic ameloblastoma, ameloblastic fibroma, odontogenic myxoma, malignant ameloblastoma and ameloblastic carcinoma.

On vitality testing all the remaining teeth showed immediate response and lesional aspiration yielded a yellowish serous aspirate.

Intraoral periapical radiograph in relation to 44, 45, 46 and 47 region showed an ill-defined radiolucency with root resorption in relation to 44. Intraoral periapical radiograph in relation to edentulous 35 and 36 region shows ill-defined multilocular radiolucency. There was evidence of radiopaque foci of intensity similar that of metallic structure suggestive of reconstruction screws.

Mandibular cross sectional occlusal radiographs revealed an ill-defined multilocular radiolucency extending from the distal aspect of 47 crossing midline and extending on the lower edentulous posterior alveolar ridge. Internal architecture revealed multiple thin sclerotic and cortical septation with entrapped normal trabeculae. There was destruction of labial cortex and expansion of lingual cortex. Buccal cortical expansion was evident in relation to 46 and 47. [Figure.3]

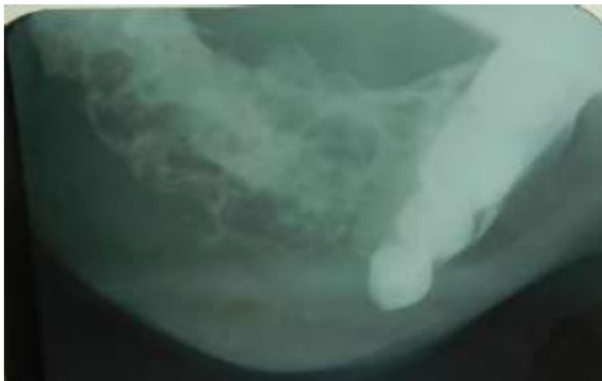


Figure 3: Mandibular cross sectional occlusal radiographs revealed an ill-defined multilocular radiolucency extending from the distal aspect of 47 crossing midline and extending to the lower edentulous posterior alveolar ridge.

Orthopantomogram revealed an ill-defined mixed radiolucent, radiopaque lesion extending from the distal aspect of 47 crossing the midline and extending up to the edentulous alveolar ridge in relation to 37. Internal architecture revealed multiple locules giving in relation to multilocular appearance. There was destruction of inferior cortical border of mandible and evidence of impacted 48. [Figure.4]

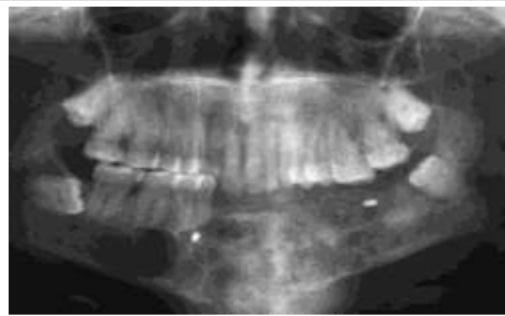

Figure 4: Orthopantomogram revealed an ill-defined mixed radiolucent, radiopaque lesion extending from the distal aspect of 47 crossing the midline and extending up to the edentulous alveolar ridge in relation to 37.

Computed tomogram axial section bone window showed mixed hypodense and hyperdense mass extending from right body of mandible to left body with evidence of labial cortical defect. There was also thinning and destruction of buccal and lingual cortex. Computed tomogram coronal section bone window showed mixed hypodense and hyperdense mass extending from right body of mandible to left body with evidence of labial cortical defect.[Figure.5]

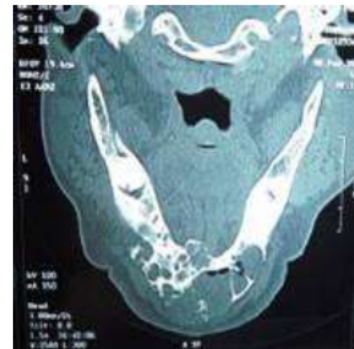


Figure 5: Computed tomogram coronal section bone window showed mixed hypodense and hyperdense mass extending from right body of mandible to left body with evidence of labial cortical defect.

Computed tomogram 3D reconstruction revealed buccal and lingual cortical plate perforation in relation to symphysis and left, right parasymphysis region. There was cortical destruction in relation to 46 47 region.[Figure.6]

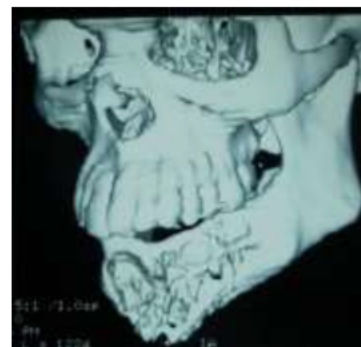

Figure 6: Computed tomogram 3D reconstruction revealed buccal and lingual cortical plate perforation in relation to symphysis and left, right parasymphysis region.

Histopathology revealed the connective tissue with homogeneous eosinophilic areas and the peripheral area shows fibrous capsule with features of infiltration by neoplastic cells and histopathology was suggestive of follicular type of ameloblastoma.[Figure.7]

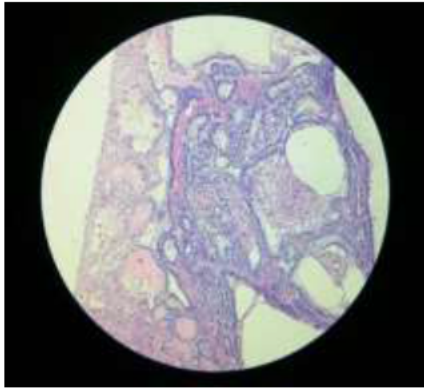


Figure 7: Histopathology revealed the connective tissue with homogeneous eosinophilic areas and the peripheral area shows fibrous capsule with features of infiltration by neoplastic cells.

Discussion

Ameloblastoma is the second most common odontogenic tumor of the jaws. It is commonly seen in adults between 30 years and 50 years without gender predilection.¹ In a study conducted by Benjamin Fomete *et al.* They observed that the age range of ameloblastoma on 14-70 year.³ This is consistent with our case where we report a case of recurrent ameloblastoma.

Ameloblastoma is a rare benign odontogenic tumor with its name derived from the early English word “amel” meaning enamel and the Greek word “blastos” meaning germ. Ameloblastoma is an odontogenic tumor of the jaws, derived from the dental embryonic remnants possibly from the epithelial lining of an odontogenic cyst, dental lamina or enamel organ, stratified squamous epithelium of the oral cavity or displaced epithelial remnants. Ameloblastoma was first described by Cusack. Malassez introduced another name “adamantinoma” that is now used to name a rare form of bone cancer.⁴

Clinically, ameloblastomas are classified as three type;

- 1) solid or multicystic,
- 2) unicystic,
- 3) extraosseous or peripheral.

Histologically, ameloblastoma shows follicular and plexiform patterns. Depending upon the differentiation, the follicular type is further divided into acanthomatous, desmoplastic, granular cell, basal cell, and clear cell and mixed variety. Reichart *et al.*, found the solid variant to be the most common (92%) while the unicystic (6%) and peripheral variants (2%) were rare. Follicular and Granular cell variants showed high recurrence rates.⁵

Mohammadinezhad *et al* reported that of ameloblastoma mainly affects adult patients between the third and seventh

decades of life frequently in the posterior region of the mandible.⁶ Waldron and El-mofty reported that 83% of case of ameloblastoma occur in mandible.³ In our case the ameloblastoma occurred in mandible which is similar to their report.

Radiographic features reveals expansile nature of the lesions along with cortical thinning in the buccal–lingual plane of dimension.. The lesions usually present as multilocular cystic with a “soap bubble” or “honeycomb” appearance. In general, radiographs of unilocular ameloblastomas, resembles dentigerous cysts or odontogenic keratocyst to a certain extent and these lesions should be ruled out to further strengthen the diagnosis of unilocular variety of ameloblastoma.⁷

Two-dimensional imaging allowed a better observation than 3D imaging of the deep structures, whereas 3D imaging was superior in visualizing the morphological changes of the compromised bones and the spatial relationship between the tumors and surrounding structures.⁸

The radiographic appearance of ameloblastoma is variable. H. M. Worth has described four patterns.

- ❖ *Unicystic type*: This appears as a unilocular radiolucency resembling a cyst. However, unlike cyst, it causes a break or discontinuity in the peripheral cortex and may even show trabeculae within the lumen.
- ❖ *Spider-web pattern*: This is the most common appearance, where the lesion is seen as a large radiolucent area with scalloped borders. From the center of the lumen coarse strands of trabeculae radiate peripherally, giving rise to a gross caricature of a spider.
- ❖ *Soap-bubble pattern*: This lesion is seen as a multilocular radiolucency with large compartments of varying sizes, giving rise to the soap-bubble appearance, or a multichambered or multi-cystic ‘bunch of grapes’ appearance.
- ❖ *Honeycomb or solid pattern*: This is also called a beehive pattern. These are tumors that have not undergone cystic degeneration. Hence, multiple small radiolucencies are seen surrounded by hexagonal or polygonal thick-walled bony cortices, giving rise to a honeycomb appearance.^{9,10}

Pietro Mainenti *et al* reported a case of recurrent ameloblastoma after 33 year of hemimandibulectomy without any reconstruction plate in 69 year old female.¹¹ In our case, the ameloblastoma recurred after 13 year in a 70 year old male which indicates that recurrence rate in ameloblastoma common in older individual.

The significance of this case report is to illustrate a rare and dramatic case of a recurrent ameloblastoma extending along the entire mandible, as a multilocular radiolucency from the distal aspect of 47 crossing the midline and extending to the lower edentulous posterior alveolar ridge. Internal

architecture revealed multiple thin sclerotic and cortical septation with entrapped normal trabeculae.

Conclusion

Ameloblastoma is the second most common benign odontogenic tumor of the oral cavity with the primary site being the mandible. Biopsy and radiological evaluation may be helpful in differentiating the subtypes of ameloblastoma. The characteristic feature of ameloblastoma is its locally aggressive behavior and its high recurrence in the oral cavity. Both of these features are consistent in this case thus proving that ameloblastoma has a high rate of local recurrence if it is not adequately removed.

References

1. Vaishampayan SS, Nair D, Patil A, Chaturvedi P. Recurrent ameloblastoma in temporal fossa: A diagnostic dilemma. *Contemp Clin Dent* 2013;4(2):220-222.
2. Basat S, Oreroglu AR, Orman C, Aksan T, Ussetin I, Akan M. Recurrent ameloblastoma in the free fibula flap: Review of literature and an unusual care report. *J Maxillofac Oral Sur* 2015;14(3):821-825.
3. Fomete B, Adebayo ET, Ogbeifun JO. Ameloblastoma: Our clinical experience with 68 cases. *J Orofac Sci* 2014;6(1):17-24.
4. Shafer textbook of oral pathology, 6th ed, 487-490.
5. Neville B, Damm D, Allen C, Bouquot J. Oral and maxillofacial Pathology; Third Ed. Saunders Elsevier, 2009.
6. Mohammadinezhad C, Aarabi AM, Zamiri B. Recurrent ameloblastoma of the mandible: Two case report. *Iranian Red Crescent Medical Journal* 2009;11(3):340-345.
7. Khan MH, Khawaja KJ, Salati NA, Zia A. Clinical and prognostic behavior of ameloblastoma after 8 years of treatment: A case report. *University J Dent Sci* 2015;1(2):28-30.
8. Gungum S, Hosgoren B. Clinical and radiologic behavior of ameloblastoma in 4 cases. *J Can Dent Assoc* 2005;71(7):481-4.
9. More C, Tailar M, Patel HJ, Asrani M, Thakkar K, Adalja C. Radiographic analysis of ameloblastoma: A retrospective study. *Indian J Dent Res* 2012;23(5):698.
10. White SC and Pharoah MJ. *Oral Radiology Principles and Interpretation*; Edition 7. St.Louis, Mo: Mosby Elsevier, 2014.
11. Mainenti P, Oliveira GS, Moraes HM, Blumer LE. Recurrent ameloblastoma after 33 years of hemimandibulectomy: Case report. *Appl Cancer Res* 2008;28(1):37-40.

Corresponding Author

Dr. Uvaraja Selvaraj
 Post Graduate Student,
 Department of Oral Medicine & Radiology,
 Mahatma Gandhi Post Graduate Institute of Dental
 Sciences, Pondicherry, Puducherry, INDIA
 Email Id: - suvraj422@gmail.com