

FACIAL ASYMMETRY AND UNILATERAL CONDYLAR HYPERPLASIA – A CASE REPORT

Gombra V,¹Mushtaq A,² Kaur M³

1. Assistant Professor, Department of Oral Medicine & Radiology, Faculty of Dentistry, Jamia Millia Islamia, New Delhi
2. Undergraduate Student, Faculty of Dentistry, Jamia Millia Islamia, New Delhi
3. Associate Professor, Department of Oral Medicine & Radiology, Faculty of Dentistry, Jamia Millia Islamia, New Delhi

Abstract

Condylar hyperplasia is a complex deformity of temporomandibular joint which involves excessive growth of condyle. Asymmetric facial deformity (AFD) is one of the consequence of condylar hyperplasia, which may often cause an alteration of the dental occlusion with unilateral crossbite or open bite. This case report demonstrates the importance of analyzing the presence of Condylar hyperplasia in cases of facial asymmetry and discusses diagnosis, investigations and various treatment modalities for the condition. Here we are presenting a case of a 44 -year-old male patient with unilateral condylar hyperplasia with review of literature.

Key words: Condylar Hyperplasia, Condyle, Facial asymmetry, Temporomandibular Joint.

Introduction

Condylar hyperplasia (CH) of mandible is the overdevelopment of condyle, unilaterally or bilaterally, leading to facial asymmetry, mandibular deviation, malocclusion and articular dysfunction. It was first reported by Adams, in 1836.¹ CH shows an acceleration of growth in young patients at the time of physiologic condylar growth or as growth spurt in adults.²

CH has an unknown etiology and is characterized by a progressive and independent growth.³

Suggested theories for etiology include neoplasia, trauma, response to infection, abnormal loading, partial hemihypertrophy, arthrosis, osteochondromatosis, local circulatory disturbances, and neurotrophic disturbances.⁴

CH is observed more frequently in women than men. Association between sexual hormones and condylar growth could be the reason for women predilection.^{3,5} Young adults as well as subjects over 50 years can exhibit CH in progress.⁷ The severity of the asymmetry was also associated with age and gender of the patient; the type of condylar deformity may present as horizontal in 53%, vertical in 31% and combined in 16% of cases.³ Histological examination reveals overactivity in articular cartilage, increased thickness of proliferative zone and hypertrophic fibrocartilagenous zone. Endochondral bone formation occurs with intact articular zone.⁶

CH can be classified based on occurrence rates and type of pathology as: CH type 1 is an accelerated and prolonged growth aberration of the “normal” mandibular condyle, causing horizontal growth vector, resulting in prognathism which may occur bilaterally (CH type 1A) or unilaterally (CH type 1B). CH type 2 is enlargement of the mandibular condyle caused by an osteochondroma, resulting in unilateral vertical overgrowth and elongation of the mandible and face. Type 2A depicts vertical growth vector and condylar enlargement, whereas TYPE 2 B grows vertically but develops horizontal exophytic tumor growth off of the condyle. CH type 3 includes other rare, benign tumors and CH type 4 includes malignant conditions of mandibular condyle. CH type 1A is the most commonly occurring and CH type 4 is the rarest form.⁷

Case Report

A 44year old male patient reported with complaint of uncomfortable bite and facial asymmetry since 25 years. On examination, there was facial asymmetry with fullness of lower third of face on the right side and depression in mid-third of the face on right side, deviation of chin towards the left side, clicking on right side, and mandibular prognathism. (Figure 1)

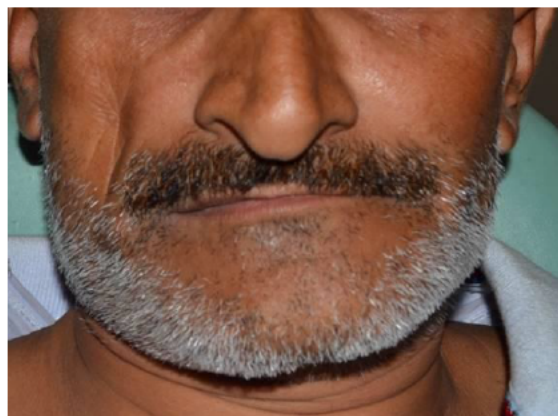

Figure 1: - Extraoral view showing facial asymmetry with deviated chin

Intraorally open bite was observed on the right side, midline deviation of about 2 mm, crossbite on left side. (Figure 2)

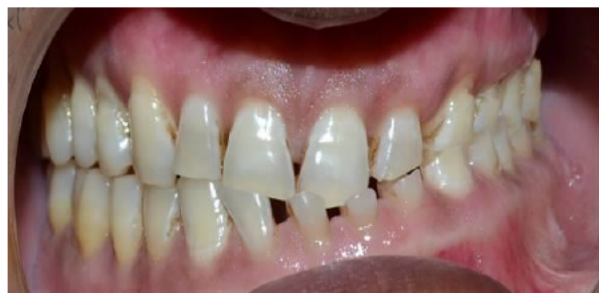

Figure 2: - Intraoral view showing mandibular midline deviation and occlusal crossbite.

Provisional diagnosis of Condylar hyperplasia was made and a differential diagnosis of hemifacial hypertrophy was suggested.

OPG with KODAK 8000C revealed right sided condylar enlargement, increased distance between the condylar head to sigmoid notch, enlarged body of mandible at the premolar region. (Table-1)

Measurement	Right Side (mm)	Left Side (mm)
Condylar head to Sigmoid notch	37.7	21.9
Condylar head - Anteroposteriorly	20.4	6.9
Body of mandible- Superoinferiorly (premolar region)	29.9	26.4
Condylar neck	10.7	6.6

Table 1: - Measurements on OPG and TMJ view (using Kodak 8000 c)

Orthopantomogram(OPG) shows anterior lipping of condyle, bowing of inferior border of mandible on right side with an overlying thin radiolucent line which probably indicates areas of bone remodelling. (Figure-3, 4 A & B)

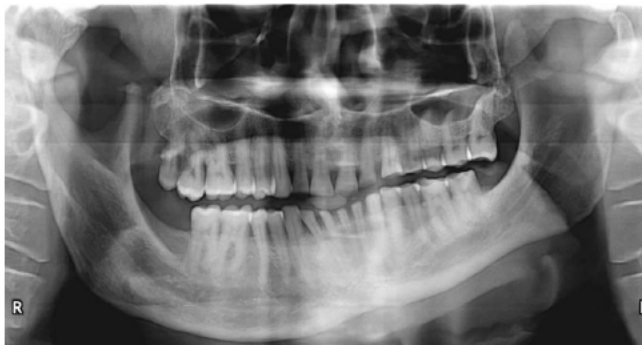

Figure 3: - OPG showing right sided enlargement of condyle and body of the mandible

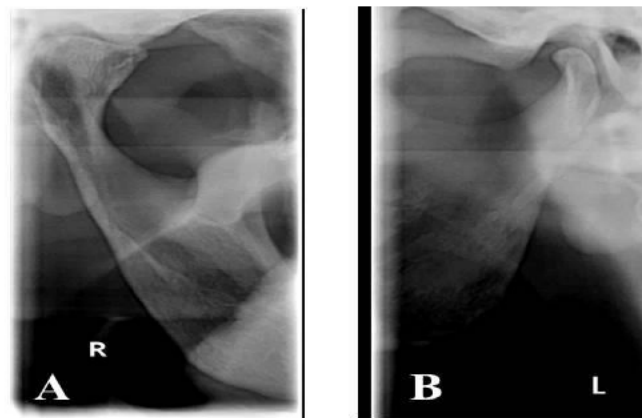


Figure 4: - TMJ view shows enlargement of right side condyle with anterior lipping in 4A and normal anatomy of left side condyle in 4B.

Correlating history, examination and radiographic investigation diagnosis of condylar hyperplasia was confirmed. In our case, the patient was not willing for a surgery and thus the regular follow up was advised for ruling out progressive changes in asymmetry.

Discussion

All the features in our case confirms unilateral condylar hyperplasia type 1B (classification by wolford *et al*).⁷ Alongwith history and, clinical signs, a radiological examination is necessary for a definitive diagnosis. Lateral cephalometric radiographs and the measurements from the radiographs would provide information whether maxilla or other facial and skull bone are involved. Posteroanterior cephalometric projections aids in detecting any horizontal shift of the mandibular midline. However, pantomograms are more valuable in this condition.² SPECT together with study models, serialized radiographs and photographs determine the state and progress of the CH; currently, the use of cone beam CT is widely used for examination. Histopathological study of surgical specimen also confirms the diagnosis, which involve surgery.³

Bone scanning with 99 technetium phosphate is a non-invasive technique to evaluate the active phase of condylar growth.² When evaluating a patient with unilateral CH hemifacial hypertrophy should be considered in the differential diagnosis. In our case, hemifacial hypertrophy is distinguishable due to the absence of unilateral overdevelopment of hard and soft-tissue structures along with absence of teeth size enlargement on the right side.⁸ The treatment options for CH are as follows:

1. The high condylectomy with disc repositioning is performed for arresting condyle and mandibular growth which is proceeded by orthodontic treatment, regardless of the magnitude of skeletal and dental malalignment. The conventional orthognathic surgery is performed in second stage.
2. The high condylectomy with disc repositioning is performed with simultaneous orthognathic surgery. This technique is helpful when patients have already passed through orthodontic treatment.⁹

Treatment depends on the presence or absence of active bone growth. If the bone is inactive the treatment would be bilateral sagittal split mandibular osteotomies, possibly with a maxillary Le Fort - I osteotomy if it involves shifted maxillary occlusal plane. High condylectomy is performed in active phase to remove the growth site, combined with further mandibular osteotomies if there is still asymmetry.¹

The radiographic investigations would serve as an aid in evaluating any changes or otherwise as an indicator of prognosis for any treatment done.

Conclusion

Unilateral condylar hyperplasia is a rare condition resulting from increased activity of the condylar growth centre. Careful history, clinical and radiographic examination will usually reveal the true nature of the condition. As this

condition can cause challenges in diagnosing, it has to be carefully differentiated with other similar conditions for planning and initiating the proper treatment modality for both functional activity and for aesthetic appearance of patient.

References

1. Mehrotra D, Dhasmana S, Kamboj M, Gambhir G. Condylar Hyperplasia and Facial Asymmetry: Report of Five Case. *J Maxillofac Oral Surg* 2011;10(1):50-56.
2. Bharathi SC, Senthilnathan S, Kumar LD, Mohan AC, Taranth M. Unilateral condylar hyperplasia: A case report and review of literature. *J Int Soc Prev Community Dent* 2014;4(1):67-70.
3. Olate S, Netto HD, Rodriguez-Chessa J, Alister JP, de Albergaria-Barbosa J, de Moraes M. Mandible condylar hyperplasia: a review of diagnosis and treatment protocol. *Int J Clin Exp Med* 2013;6(9):727-737.
4. Gray RJ, Sloan P, Quayle AA, Carter DH. Histopathological and scintigraphic features features of condylar hyperplasia. *Int J Oral Maxillofac Surg* 1990;19(2):65-71.
5. Olate S, Almeida A, Alister JP, Navarro P, Netto HD, de Moraes M. Facial asymmetry and condylar hyperplasia: considerations for diagnosis in 27 consecutive patients. *Int J Clin Exp Med* 2013;6(10):937-941.
6. de Bont LG, Blankestijn J, Panders AK, Vermey A. Unilateral condylar hyperplasia combined with synovial chondromatosis of the temporomandibular joints. Report of a case. *J Maxillofac Surg* 1985;13(1):32-36.
7. Wolford LM, Movahed R, Perez DE. A classification system for conditions causing condylar hyperplasia. *J Oral Maxillofac Surg* 2014;72(3):567-95.
8. Bhuta BA, Yadav A, Desai RS, Bansal SP, Chemburkar VV, Dev PV. Clinical and imaging findings of true hemifacial hyperplasia. *Case Rep Dent* 2013;2013:152528. doi:10.1155/2013/152528
9. Everton Da Rosa, Júlio Evangelista De Souza Júnior and Melina Spinosa Tiussi. Mandibular Condylar Hyperplasia, Maxillofacial Surgery, Prof. Leon Assael (Ed.), ISBN: 978-953-51-0627-2, InTech, Available from: <http://www.intechopen.com/books/maxillofacial-surgery/mandibular-condylar-hyperplasia>

Corresponding Author

Dr. Virender Gombra
Assistant Professor,
Department of Oral Medicine & Radiology,
Faculty of Dentistry, Jamia Millia Islamia,
New Delhi.
Email- vgombra@jmi.ac.in