

OVERDENTURE WITH CEKA PRECI-CLIX ATTACHMENTS

A CASE REPORT

Rajat R. Khajuria,¹ Rishav Singh,² Priyanka³

1. Private Practitioner, Prosthodontist, Jammu.

2. Private Practitioner, Pedodontics & Preventive Dentistry, Noida.

3. Private Practitioner, Prosthodontist, Patna, Bihar.

Abstract

Over dentures is a preferred treatment option in patients which have to go for extraction of remaining teeth for fabrication of complete dentures earlier. The teeth which are preserved, play a vital role by improvement of crown root ratio, provide proprioception, decrease the rate of resorption and improve support to the denture. Rehabilitation using over dentures is a widely accepted preventive approach due to its ease of fabrication and the successful prognosis. The use of ball and socket type of attachments for improved retention is a novel technique and is becoming popular day by day. The advantage of freedom of rotation it provides makes it user friendly for patients. In this case-report, we have rehabilitated the patient with few remaining teeth with over dentures supported by Preci-Clix attachments.

Keywords: Attachments, Overdenture, Preci-Clix, Retention

Introduction

In the past, when patients presented themselves as candidates for a denture with badly mutilated teeth, the only option available to us was extraction followed by fabrication of conventional denture with all of its pit falls. Chief deficiencies viewed in such patients are of gradual ridge resorption and decrease of neuromuscular function due to decrease in proprioceptive responses.¹

Today, with the stress on preventive measures in Prosthodontics, the use of over dentures has increased to the point of most feasible treatment plan.

The over denture basically fulfills three main goals: First, it maintains the teeth as part of the residual ridge. Secondly, it decreases the rate of resorption and thirdly, it improves the proprioceptive response of patient.¹

Case Report

An old medium built male patient of 62 years reported with the chief complaint of problem in chewing due to missing teeth since last one year. Patient was a public speaker and was concerned regarding the retentive features of his prosthesis. On clinical examination, the patient was found to have an acceptable bilateral symmetry with oval face form and a straight profile. The maxillary arch was having 13, 12, 21 and 22. In the mandibular arch, teeth present were 34 & 44 with root stump w.r.t 31. (Figure-1)

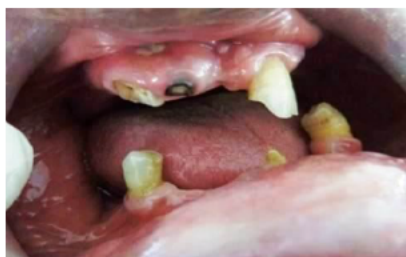

Figure 1: - Pre-Operative view.

The entire treatment plan was divided into three phases: Surgical phase, Endodontic phase and Prosthetic Phase. The patient was adamant not to go for extraction due to past bad experience so surgical phase was omitted from treatment

plan. Endodontic phase included Intentional Endodontic treatment for all the teeth present except 31. (Figure-2)

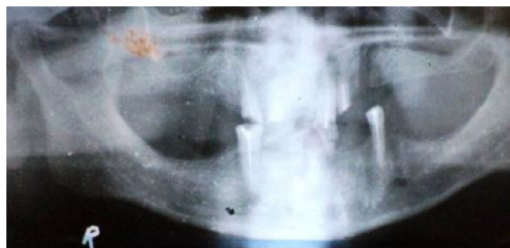


Figure 2: - Orthopantograph after Endodontic treatment.

Prosthetic phase started around 10 days after the completion of endodontic phase and included fabrication of an over denture with Ceka Preci-clix type of attachments. Steps carried out are as under:

Step 1: Diagnostic Impressions

Diagnostic Impressions were made using irreversible hydrocolloid as impression material.

Step 2: Preparation of the teeth and cementation of posts (12, 13, 21, 22, 34 and 44).

- Teeth were reduced to the level of the gingiva and rounded to form a dome shape.
- Ceka Preci-Clix Kit has 3 preformed burs of 10mm length. First, Pre-drilling bur is used and the canal is prepared. Then the second bur is used which incorporates the specific countersinking in the tooth. Finally, the reamer is used with pull out fashion to increase the diameter and smoothen the walls. (Figure-3,4)

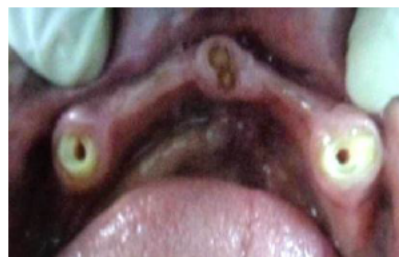

Figure 3: - Post space prepared in mandibular arch

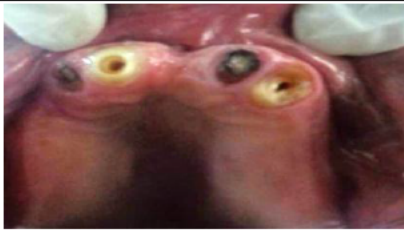


Figure 4: - Post space prepared in Maxillary arch.

c) The fit of the post was confirmed and cementation of posts was carried out with Glass Ionomer Cement in luting consistency. (Figure-5)

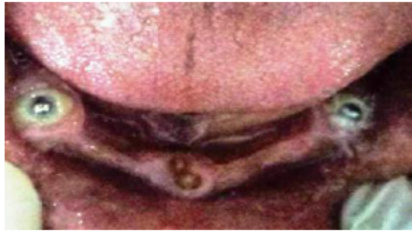

Figure 5: - Post placed in the endodontically treated tooth.

Step 3: Primary Impression making.

Impressions were made using heavy viscosity irreversible hydrocolloid as impression material and casts were poured in type 3 dental stone. Special tray was made of auto-polymerizing acrylic resin with double thickness spacer around posts.

Step-4: Border Molding

Border molding was carried out using low fusing impression compound. Spacers were removed from both maxillary and mandibular arches and secondary impressions were made using low viscosity addition silicone paste.

Step-5: Jaw Relations

Face-Bow transfer was carried out and transferred to semi-adjustable articulator. Vertical dimensions were assessed and centric relation was recorded using nick and notch method.

Step-6: Teeth Arrangement and trial denture

Bilateral balanced teeth arrangement was carried out for the patient and trial denture was evaluated for centric, vertical relations, esthetics, form and phonetics.

Step-7: Insertion of the prosthesis

The prosthesis was cured in high impact heat cure acrylic resin and was finished to a high finish.

The female component of Ceka Preci-Clix is available in 3 different colors i.e white (less retention), yellow (normal retention) and red (Increased retention).² The yellow female components were incorporated in denture with the black fixing tool and held with the chair-side rapid repair resin. The denture was inserted and occlusal equilibrations were carried out. Post insertion instructions were given to the patient and patient was recalled for checkup. A follow-up of 6 months reveals patient with healthy mucosa and successful rehabilitation using attachments. (Figure - 6, 7)

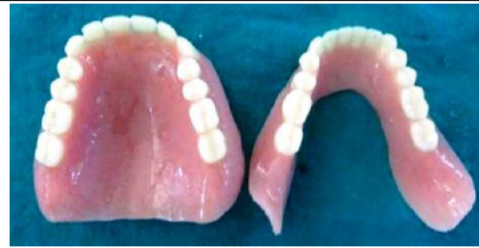

Figure 7: - Final denture after incorporation of female segment

Discussion

The most significant decisions in successful over dentures are selecting the proper type of patient and establishing a careful mode of treatment that will satisfy both the patient and dentist. Various techniques are there for restoration of the lost dentition using over dentures namely Simple tooth modification and reduction, Tooth reduction and cast coping, Endodontic therapy with cast coping and Endodontic therapy with some form of attachment.¹ The approach of using attachments is reserved for selective candidates having increased amount of bone loss desiring significant improvement in retention. We, in this case selected for the Preci-Clix type of attachments which belong to the category of Stud Attachments. Preci-Clix attachments consist of male stud part that usually is a post extending into the Endodontically treated tooth. Fixation is achieved with the help of female component in the form of ring placed on the tissue side of the denture. The chief reasons for selection of this type of attachment are its simplicity, ability to rotate in all directions and single visit application of the attachment.

Conclusion

Over denture usage has become popular mode of rehabilitation in the modern dentistry. Its usage is limitless and should be encouraged. The failures occurring in this therapy are only due to the poor case selection and inadequate maintenance. As more is learned about these techniques, better prognosis and success rates are assured.

References

1. Winkler S. Essentials of complete denture Prosthodontics, 2nd Edition, 2000, 384-402.
2. Ceka Attachment Preci -Line technique manual. Waregem (Germany) 2007.
3. Harold W. Preiskel; Overdentures Made Easy: A Guide to Implant and Root Supported Prosthesis, 1st Edition, 1996.
4. Fenton AH. The decade of overdenture: 1970-1980. J Prosthet Dent 1998;79(1):31-6.

Corresponding Author

Dr. Rajat R. Khajuria
Prosthodontics,
Private Practitioner,
Jammu, INDIA
Email id: - drrajatkajuria@yahoo.com