

PERIPHERAL OSSIFYING FIBROMA IN A 13 YEAR OLD CHILD: A CASE REPORT

Jaiswal N,¹ Kaur H,² Garg N,³ Lumbini P,⁴ Yeluri R⁵

1. Post Graduate Student, Department of Pedodontics & Preventive Dentistry, Teerthanker Mahaveer Dental College & Research Centre, Moradabad, Uttar Pradesh.
2. Professor, Department of Pedodontics & Preventive Dentistry, Teerthanker Mahaveer Dental College & Research Centre, Moradabad, Uttar Pradesh.
3. Reader, Department of Pedodontics & Preventive Dentistry, Teerthanker Mahaveer Dental College & Research Centre, Moradabad, Uttar Pradesh.
4. Reader, Department of Pedodontics & Preventive Dentistry, Teerthanker Mahaveer Dental College & Research Centre, Moradabad, Uttar Pradesh.
5. Professor & Head, Department of Pedodontics & Preventive Dentistry, Teerthanker Mahaveer Dental College & Research Centre, Moradabad, Uttar Pradesh.

Abstract

Peripheral ossifying fibroma (POF) is a relatively uncommon, gingival overgrowth, which comprises of fibroblastic tissue that contains one or more mineralized tissues. It is considered reactive rather than neoplastic, with difficulty in diagnosing from other gingival overgrowths owing to its similar clinical presentation. Considerable confusion has prevailed in the nomenclature of POF due to its variable histopathological features. Occurrence of POF in mandible is uncommon when compared with maxilla. This report presents a clinical case of 13 year old boy with a gingival overgrowth along the mandibular anterior region, which was diagnosed as peripheral ossifying fibroma.

Keywords: Ossifying Fibroma; Gingiva; Inflammatory Hyperplasia; Pyogenic Granuloma.

Introduction

Most of the reactive lesions occurring on the gingiva include focal fibrous hyperplasia, pyogenic granuloma, peripheral giant cell granuloma and peripheral ossifying fibroma (POF).¹ Peripheral ossifying fibroma (POF) is a reactive gingival overgrowth which is relatively uncommon in nature. POFs comprises of, one or more mineralized tissues, including bone, cementum like material or dystrophic calcification, within a matrix of cellular fibroblastic tissue.² POF is defined as a well demarcated and occasionally encapsulated lesion consisting of fibrous tissue containing variable amounts of mineralized material resembling bone (ossifying fibroma). It is considered to be the soft tissue counterpart to central ossifying Fibroma.³ POF is considered hyperplastic reaction rather than neoplastic, as various factors including local irritation, microorganisms, masticatory forces, minor trauma, trapped food and debris, microbial plaque, calculus and iatrogenic factors lead to development of the lesion.⁴ The objective of this report is to present a case of peripheral ossifying fibroma in a 13 year old child.

Case report

A 13-year-old boy with swollen gums in his lower front teeth region was referred to the department of paediatric dentistry. The patient had noticed the swelling 6 month back and since then there has been increase in its size. There was no associated history of pain or discharge from the swelling. Past medical, dental and family history were found to be non contributory. No abnormalities were detected on general and extra oral examination. Intra oral examination revealed a generalized pink gingiva with a well-demarcated, non-tender, firm, focal, sessile nodular growth arising from the interdental papilla of the mandibular right central and lateral incisors and covering the crown of the mandibular lateral incisor extending to lingual aspect. The oval-shaped mass was 2 cm x 1.5 cm in size, with a reddish pink color, smooth surface, and distinct edges. On palpation all inspectory findings were confirmed. It was firm to hard in consistency with a sessile base and non tender on palpation. Bleeding on probing was

noted. The lesion was asymptomatic, and showed no clinical evidence of ulceration. [Figures 1&2]

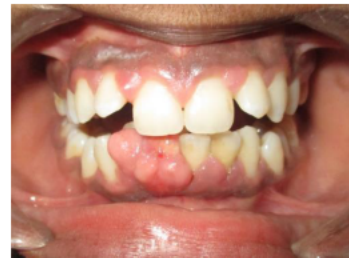

Figure 1: Labial view of the lesion.

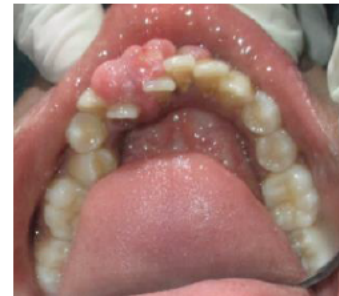

Figure 2: Lingual view of the lesion.

Based on these findings a provisional diagnosis of pyogenic granuloma was made. Further a differential diagnosis of peripheral ossifying fibroma, peripheral giant cell granuloma was considered. Patient was subjected to intra oral periapical radiograph examination which showed no visible bone involvement. [Figure 3]

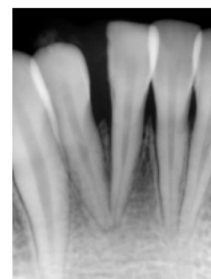


Figure 3: IOPAR shows no bony erosion irt 31, 41, 42 & 43.

Later with the patients consent an excisional biopsy was performed under aseptic precautions and under bilateral mental nerve block and lingual infiltration, the lesion was split into two halves (buccal and lingual) using electrocautery. The buccal half was elevated using a periosteal elevator upto the base. Then the base of the buccal half was excised closed to the cervical line of the teeth using a combination of scalpel and electrocautery. Haemostasis was achieved followed by placement of Coe pack. The postoperative period was uneventful. [Figure 4]

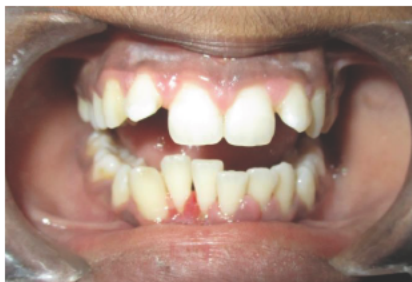

Figure 4: After surgical excision.

The histopathological examination of the lesion revealed hyperplastic stratified squamous epithelium with elongated rete ridges with underlying fibrovascular connective tissue. The connective tissue showed rich vascularity with loosely arranged collagen fibers, osteoid like areas and areas showing spicules of bone with osteocytes in the lacunae along with osteoblastic rimming. Chronic inflammatory cell infiltrate consisting predominantly of lymphocytes were seen within the connective tissue with numerous proliferating capillaries along with extravasated RBC.0 [Figure 5]

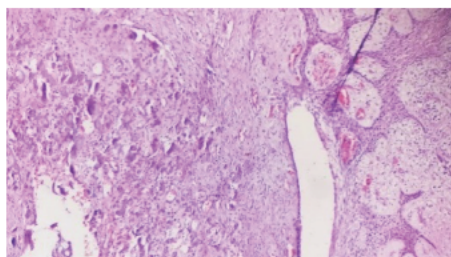


Figure 5: Histopathological view of the lesion under 4X low magnification.

These features confirmed the diagnosis of peripheral ossifying fibroma. Patient was reviewed consequently two times with in a period of two year, with no known recurrence. [Figure 6]

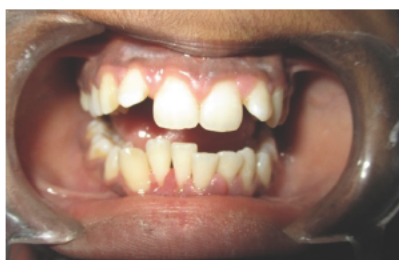

Figure 6: Follow up view after 2 years.

Discussion

In 1844 Shepherd, first reported and described Peripheral ossifying fibroma (POF) as 'alveolar exostosis'.⁵ Fibroblastic gingival lesions have been given a number of names, such as epulis, peripheral fibroma with calcification, peripheral ossifying fibroma, calcifying fibroblastic granuloma, peripheral cementifying fibroma, peripheral fibroma with cementogenesis and peripheral cemento-ossifying fibroma, which indicates that there is a lot of controversy surrounding the classification of these lesions.¹ The peripheral ossifying fibroma (POF) is a relatively uncommon reactive lesion of the gingiva, associated with mineralization and derived from the periodontal ligament cells.⁶ World Health Organization has recognized peripheral odontogenic fibroma as a distinct and different entity from the POF.⁷ Although, the definitive etiology of POF remains unknown, trauma or local irritants, such as dental plaque, calculus, ill-fitting dental appliances and poor quality dental restorations are said to play an important role in its etiology and pathogenesis. Inflammatory hyperplasia originating in the superficial periodontal ligament (PDL) is considered to be a factor in the histogenesis of the POF.⁸ These lesions originate in the cells of the periodontal ligament for the following reasons:

- POF exclusively appears in the gingival tissue, close to the periodontal ligament.
- Oxytalan fibers are present within the mineralized matrix of some lesions.
- The age distribution of the lesions is inversely proportional to the number of permanent teeth lost.
- POF fibrocellular response is similar to that of other reactive gingival lesions originating in the periodontal ligament.⁹

POF most commonly occurs in the second decades of life with wide range of age. The average age is about 25 years with more predilection towards females than males.¹⁰ Although POF is reported in children with primary or mixed dentition periods, there is very little specific occurrence with primary teeth.¹¹ Mostly POFs occur in the maxilla, more often in the anterior than the posterior area, with most prevalence in the incisor cuspid region.¹ Clinically, POF presents as a solitary, slow growing, pedunculated or sessile, nodular mass. The surface mucosa appears smooth or ulcerated, with color varying from pink to red. In few cases migration of teeth with interdental bone destruction has been reported. POFs measure about <1.5 cm in diameter, even though lesions can grow till the size of 6 to 9 cm.² It most commonly appears to originate from an interdental papilla.¹² In children POF can exhibit a rapid growth rate and reach a significant size in a short period of time. These soft tissue nodules can cause superficial erosion of bone, producing minor or moderate tooth movement, and also results in delayed eruption of teeth.¹¹ Differential diagnoses include peripheral giant cell granuloma, pyogenic granuloma, fibroma and peripheral odontogenic fibroma. Histologically, the POF should be

differentiated from peripheral odontogenic fibroma.^{13,14} Radiographic features of the peripheral ossifying fibroma may vary. Few lesions in the central area show radiopaque foci of scattered calcifications. On a radiograph underlying bone involvement is usually not visible. Superficial erosion of bone noted in few instances.¹⁵ POF does not require any further imaging in addition to plain radiographs.¹³ The basic microscopic pattern of POF is one of a fibrous proliferations associated with the formation of mineralized product. In few conditions the epithelium is ulcerated with the surface covered by fibrinopurulent membrane covering the subjacent zone of granulation tissue. The deeper fibroblastic component frequently is cellular, predominantly in areas of mineralization. The type of mineralized component is variable and may composed of bone, cementum like material or dystrophic calcifications. Often combination of products is formed. Generally the bone is woven and trabecular type or the older lesions may express mature lamellar bone. Dystrophic calcifications are characterized by multiple granules, tiny globules or large, irregular masses of basophilic mineralized material.¹⁶ Treatment for POF includes proper surgical intervention that ensures thorough excision of the lesion including the involved periosteum and the periodontal ligament. Thorough scaling and root planing should be accomplished. The recurrence rate of the POF is said to be high. Recurrence probably occurs due to incomplete removal of lesion, repeated injury or persistence of local irritants.³ But in our case we have not observed any recurrence even after 2 years of follow up.

Conclusion

POF is an uncommon slow growing reactive lesion of gingiva which goes unnoticed for long periods because of the lack of symptoms associated with the lesion. Prompt diagnosis and treatment is essential as it plays a major role on the prognosis of the lesion.

References

1. Farquhar T, Maclellan J, Dymont H, Anderson RD. Peripheral ossifying fibroma: a case report. *J Can Dent Assoc.* 2008;74(9):809-812.
2. Mergoni G, Meleti M, Magnolo S, Giovannacci I, Corcione L, Vescovi P. Peripheral ossifying fibroma: A clinicopathologic study of 27 cases and review of the literature with emphasis on histomorphologic features. *J Indian Soc Periodontol.* 2015;19(1):83-87.
3. Nazareth B, Arya H, Ansari S, Arora R. Peripheral ossifying fibroma: a clinical report. *Int J Odontostomat.* 2011;5(2):153-156.
4. Mesquite RA, Orsini SC, Sousa M, de Araújo NS. Proliferative activity in peripheral ossifying fibroma. *J Oral Pathol Med.* 1998;27(2):64-67.
5. Ogbureke EI, Vigneswaran N, Seals M, Frey G, Johnson CD, Ogbureke KU. A peripheral giant cell granuloma with extensive osseous metaplasia or a hybrid peripheral giant cell granuloma-peripheral ossifying fibroma: a case report. *J Med Case Rep.* 2015;9:14.

6. Garcia BG, Caldeira PC, Johann AC, Sousa SC, Caliar MV, Carmo MA, *et al.* Cellular proliferation markers in peripheral and central fibromas: a comparative study. *J Appl Oral Sci.* 2013;21(2):106-111.
7. Rossmann JA. Reactive lesions of the gingiva: diagnosis and treatment options. *Open Pathol J.* 2011;5:23-32.
8. Cuisia ZE, Brannon RB. Peripheral ossifying fibroma - a clinical evaluation of 134 pediatric cases. *Pediatr Dent.* 2001;23(3):245-248.
9. Garcia de Marcos JA, Garcia de Marcos MJ, Arroyo Rodríguez S, Chiari Rodrigo J, Poblet E. Peripheral ossifying fibroma: a clinical and immunohistochemical study of four cases. *J Oral Sci.* 2010;52(1):95-99.
10. Gardner DG. The peripheral odontogenic fibroma: an attempt at clarification. *Oral Surg Oral Med Oral Pathol.* 1982;54(1):40-48.
11. Ozalp N, Sener E, Songur T. Peripheral giant cell granuloma and peripheral ossifying fibroma in children: two case reports. *Med Princ Pract.* 2010;19(2):159-162.
12. Rajendran A, Sivapathasundaram B, editors. Shafer's textbook of oral pathology. 7th Ed. New Delhi:Elsevier Publications. 2012;133-135.
13. Moon WJ, Choi SY, Chung EC, Kwon KH, Chae SW. Peripheral ossifying fibroma in the oral cavity: CT and MR findings. *Dentomaxillofac Radiol.* 2007;36(3):180-182.
14. Taur S, Hadakar S, Patil P, Mane P. Peripheral ossifying fibroma: report of a case. *Int J Pre Clin Dent Res.* 2014;1(4):107-110.
15. Yadav R, Gulati A. Peripheral ossifying fibroma: a case report. *J Oral Sci.* 2009;51(1):151-154.
16. Neville BW, Damm DD, Allen CM, Boquout J. *Oral Maxillofacial Pathology.* 3rd Ed. Philadelphia: Saunders. 2009;521-523.

Corresponding Author

Dr. Neha Jaiswal

Post Graduate Student,
Department of Pedodontics & Preventive Dentistry,
Teerthanker Mahaveer Dental College & Research
Centre, Moradabad, Uttar Pradesh, INDIA
Email Id: - 2011neha91@gmail.com