

TREATMENT OF CLASS II MALOCCLUSION IN ADOLESCENT BY “FORUS FRD”

Hanumanth S,¹ Nayak Krishna US²

1. Senior Lecturer, Department of Orthodontics, Indira Gandhi Institute of Dental Sciences, Puducherry
2. Professor, Department of Orthodontics, A. B. Shetty Memorial Institute of Dental Sciences, Mangalore

Abstract

Traditional technique for correcting Class II in a growing patient is by growth modulation. In adults Class II discrepancy are treated either by orthodontic or camouflage or by surgical correction. Class II discrepancies with mandibular deficiency during active growth are treated by Myofunctional appliances. Non-compliance has been a major factor in functional appliances. This Case report describes the management of Class II malocclusion by Forsus FRD. A 14 year old patient reported to the department with complains of spacing between upper and lower front teeth. On examination patient had a skeletal Class I with dental Class II relation. Intra orally patient had a Class II molar and incisor relation with increased overjet and overbite and missing upper lateral incisors. The treatment plan of non-extraction with Forsus FRD for bite jumping was to correct the discrepancy and obtain an aesthetic, harmonious facial profile. This was followed by replacement of Upper lateral incisors. The Forsus FRD helped to accomplish the objectives of the treatment.

Keywords: - Forsus FRD, Class II correctors G

Introduction

Treatment of Class II malocclusion has always been an enigma in the orthodontic fraternity. Class II malocclusion could be either a skeletal or a dental malocclusion. Skeletal Class II malocclusion could be treated either by:

1. Growth modification
2. Camouflage
3. Orthognathic Surgery.¹

Skeletal Class II malocclusion during active growth can be corrected using myofunctional appliances like activator, bionator or a twin block. Treatment of Class II during decelerating growth has been a challenge.²

Lack of compliance is another factor in the failure of functional appliances. In order to combat these disadvantages non-compliant Class II correctors were introduced.

Fixed functional appliances are considered to be non-compliant Class II correctors.³ This case report demonstrates the use of Forsus fatigue resistant device to correct a Class II malocclusion.

Case Report

A 16 year old patient reported to the Department of Orthodontics, A. B. Shetty Memorial Institute of Dental Sciences with complains of spacing between upper front teeth. Clinical examination revealed a brachycephalic type with a mild convex facial profile. The patient had a flat mandibular plane angle.

On Intra oral examination the patient had upper and lower anterior spacing with missing upper lateral incisors, class II molar relation and Class II division 1 incisor relation with an over jet of 6 mm and overbite of 5 mm. (Figure 1a & 1b)

The lateral cephalogram showed a skeletal Class I relation with flat mandibular plane angle, decreased lower anterior facial height. Dentally Class II relation was seen with proclined upper and lower anteriors. The naso-labial angle was within normal limits. (Figure 2)

The Treatment objective in this case was to achieve an aesthetically harmonious soft tissue profile by reducing the patient's facial convexity and increasing her lower facial height. The occlusal goals were to achieve a Class I molar relation, Class I incisor relation, obtain a normal overjet, overbite and replace the missing lateral incisors.

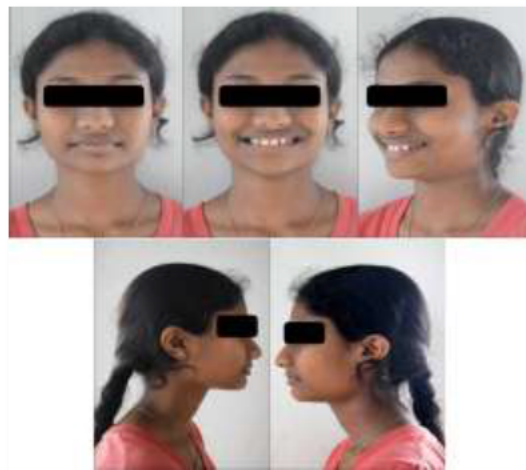

Figure 1a: - Pre Treatment Extra-oral Photographs

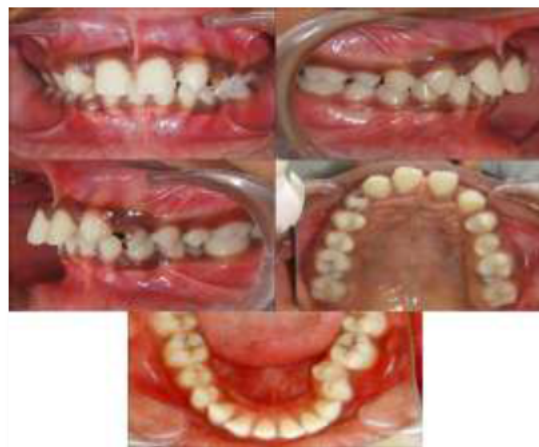

Figure 1a: - Pre Treatment Intra-oral Photographs

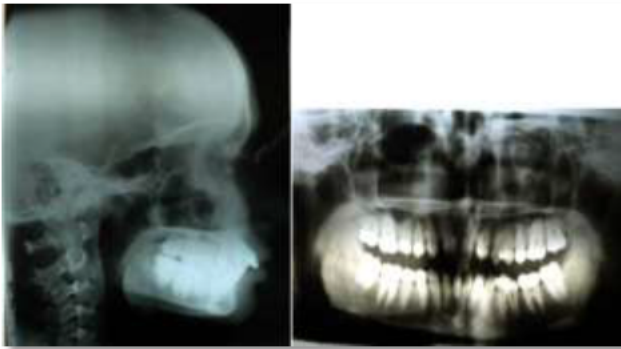

Figure 2: - Pre Treatment Lateral Cephalogram and OPG
The patient was presented with option of non-extraction treatment with fixed functional appliance.

The primary purpose of orthodontic treatment was to attain a Class I canine and molar relationship and create space for replacement of upper lateral incisors.

Treatment Progress

The maxillary and mandibular arches were banded and bonded with 0.022 MBT slot brackets. The initial levelling and aligning were done with 016 Ni-Ti, 018 Ni-Ti, 16 X 22 Ni-Ti and 19 X 25 Ni-Ti.

After initial alignment, upper and lower 19 X 25 stainless steel wires were placed and the upper canines were retracted using Ni-Ti coil spring. (Figure 3a, 3b)

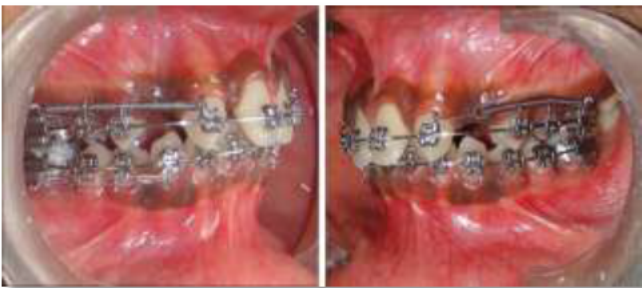

Figure 3a: - Canine retraction using Ni-Ti coil spring

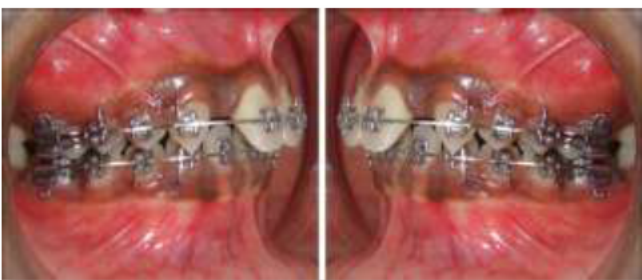

Figure 3a: - End of Retraction

At the end of retraction the upper and lower arches were consolidated. The space between upper canine and central incisor was maintained by a plastic sleeve on both sides. Lower 19 X 25 stainless steel wire was placed with U loop between the canine and premolar on each side for the attachment of push rod of forsus appliance. The brackets

were ligated with stainless steel ligatures and were left in place for one month to express the bracket prescription.

Following this Forsus FRD was installed to advance the mandible and correct the molar and canine relation. Fig 4

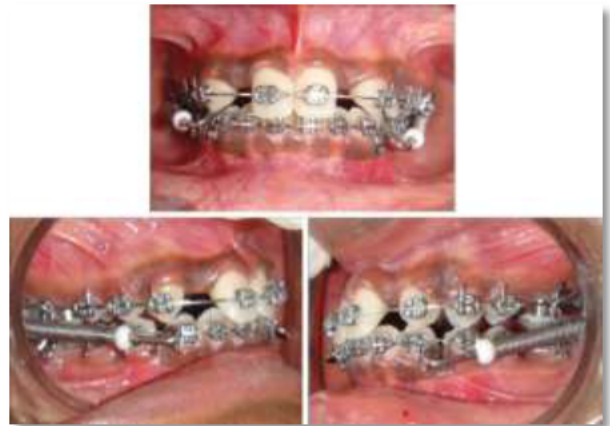

Figure 4: - Placement of Forsus FRD

The Forsus appliance was left in place for 6 months. After 6 months Class I molar and canine relation was achieved. This was followed by settling of occlusion and final finishing and detailing. Figure 5

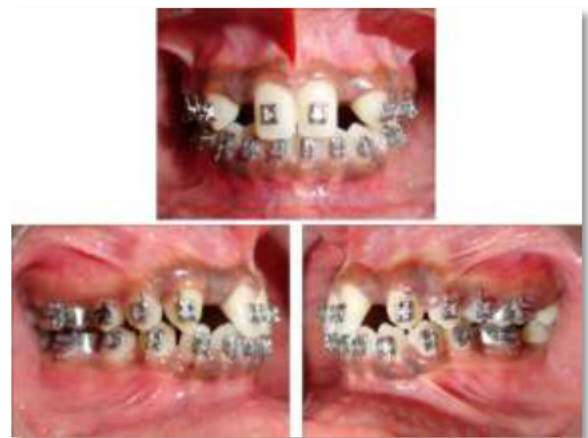

Figure 5: - Post Forsus FRD

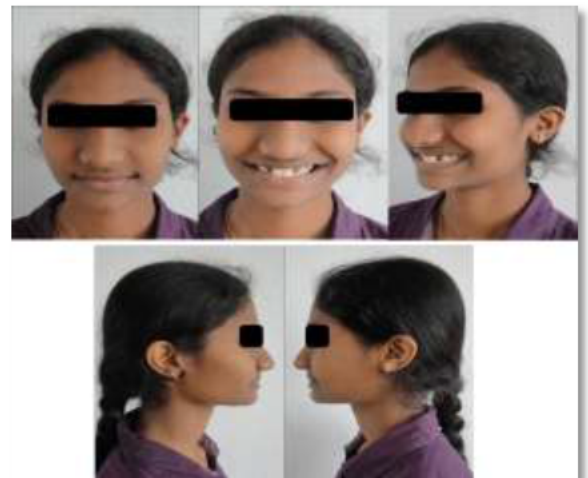


Figure 6a: - Post De-bond Extra Oral Photographs

After 5 months of finishing and detailing the appliance was de-bonded. Maxillary and mandibular wrap around retainers were given with artificial upper lateral incisors in the maxillary retainer and final records were taken. Figure 6a – 6b, Figure 7, Figure 8.

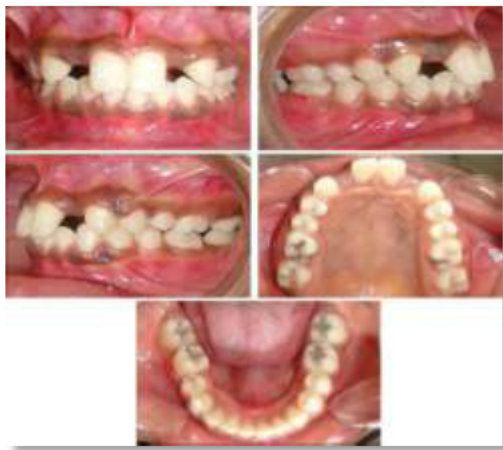

Figure 6b: - Post De-bond Intra Oral Photographs

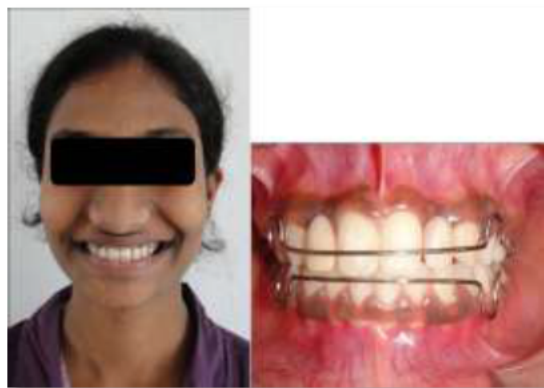

Figure 7: - Retainers

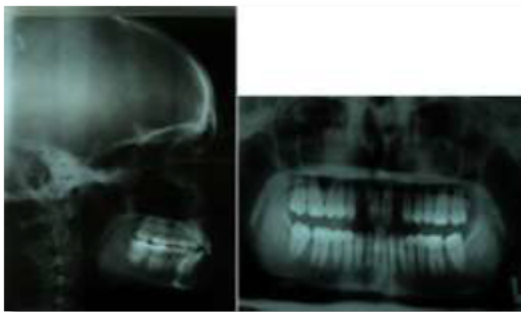

Figure 8: - Post Treatment Lateral Cephalogram and OPG

Discussion

Treatment of Class II in this case was by Forsus FRD. Over the years orthodontists have been using many fixed functional appliances. The most recent of the lot is the Forsus FRD which has been found to produce stable results.³

The results achieved with Forsus in this case are shown in the tables 1.

Cephalometric Values	Pre Treatment	Mid Treatment	Post Treatment
SNA	84	84	81
SNB	81	80	80
WITS	4	4	2
N-A-Pg	4	3	0
Upper Incisor to NA	34/7	30/5	31/5
Lower Incisor to NB	28/5	31/4	31/3
Lower incisor to Mandibular Plane	105	110	112
Inter-Incisal Angle	104	126	123
Naso-Labial Angle	104	103	102
Upper lip to E line	-6	-6	-6
Lower lip to E line	-2	+1	+1
Upper lip to S line	1	2	3
Lower lip to S line	0	1	2

Table 1: - Showing the changes in cephalometric values during the course of treatment

Post treatment measurements showed favourable changes in the SNA and SNB Values. SNA changed from 84° to 81° while SNB remained the same. The angle of convexity showed improvement. The mandibular plane angle improved increasing the facial height. There was significant change in the axial inclination of both upper and lower incisors. The lower incisors showed significant proclination of 4°. The soft tissue profile improved indicated by Naso-labial angle, Position of upper and lower lips.

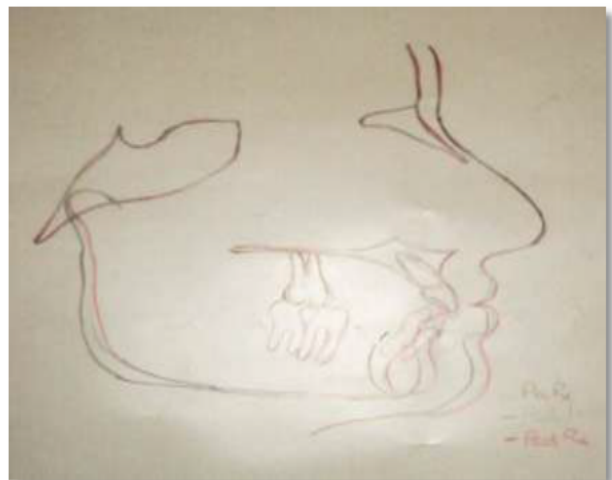


Figure 9: - Super-imposition

The Values indicated a more dento-alveolar correction with mild skeletal changes.

As the patient’s age was not ideal for placement of implants for the missing lateral incisors, the replacement was done

by modifying the retainers with acrylic teeth attached to it for replacement of 12 and 22.

Conclusion

Class II malocclusions require careful diagnosis and treatment planning for a successful outcome. Here in this case report the Class II malocclusion was treated by Forsus FRD.

Significant improvement in the soft tissue profile and occlusion was obtained in this case by mild mandibular advancement which added to the aesthetic value. Cases requiring bite jumping to correct a Class II dental relation can be corrected using Forsus FRD as described in this case report here.

References

1. Heinig N, Goz G: Clinical application and effects of the Forsus spring. A study of a new Herbst hybrid. *J Orofac Orthoped* 2001;62(6):436–450.
2. Jones G, Buschang P H, and Kim K B, Oliver D R: Class II non-extraction patients treated with the Forsus Fatigue Resistant Device versus inter-maxillary elastics. *Angl Orthodont* 2008;78(2):332-338.
3. Karacay S, Akin E, Olmez H, Gurton A U, and Sagdic D: Forsus Nitinol Flat Spring and Jasper Jumper corrections of Class II division:1 malocclusions. *Angl Orthodont* 2006;76(4):666–672.
4. Nelson B, Hansen K, Hagg U: Class II correction in patients treated with class II elastics and with fixed functional appliances: a comparative study. *Am J Orthodont Dentofac Orthoped* 2000;118(2):142–149
5. Pancherz, H: Treatment of class II malocclusions by jumping the bite with the Herbst appliance: A Cephalometric investigation. *Am J Orthodont* 1979;76(4):423–442.

Corresponding Author

Dr. Hanumanth S.
Senior Lecturer
Indira Gandhi Institute of Dental Sciences,
Puducherry
Email: - hanumanth001@gmail.com