

## FORENSIC: AT FIRST SIGHT

Bhagwat Sharma,<sup>1</sup> Amit Srivastav,<sup>2</sup> Yogesh Chand Rajwar,<sup>3</sup> Sankalp Sharma,<sup>4</sup> Divya Sharma,<sup>5</sup> Puneet Batra<sup>6</sup>

1. Post Graduate Student, Department of Oral Pathology & Microbiology, Institute of Dental Sciences & Technology, Modinagar

2. Senior Lecturer, Department of Orthodontics, Institute of Dental Sciences & Technology, Modinagar

3. Senior Lecturer, Department of Oral Pathology & Microbiology, Eklayya Dental College & Hospital, Kotputli, Rajasthan

4. Senior Lecturer, Department of Prosthodontics, Kothiwala Dental College & Research Center, Moradabad.

5. Senior Lecturer, Department of Oral Pathology & Microbiology, Swami Devi Dayal Dental College & Hospital, Barwala, Panchkula

6. Professor & Head, Department of Orthodontics, Institute of Dental Sciences & Technology, Modinagar

### Abstract

Forensic Odontology is a relatively new science that utilizes the dentist's knowledge to serve the judicial system. It has established itself as an important indispensable science in medico legal matters and in particular in personal identification, gender determination and age estimation. Forensic dentistry is the branch of dentistry that deals with the legal aspects of professional dental practices and treatment, with particular emphasis on the use of dental records to identify victims of crimes or accidents. Forensic dentistry plays an important role in mass disasters (terrorist attacks, earthquakes, Tsunamis), child/elder/spouse abuse, bite mark analysis, criminal/natural deaths and injuries, Bioterrorism etc... It also helps in identification of decomposed and charred bodies like that of drowned persons, burns, and victims of motor vehicle accidents. There are several reliable alternative methods of establishing identity like Cheiloscopy, Bite marks, Rugoscopy, Tooth prints, Photograph analysis, molecular methods (DNA extraction) and biometrics analysis (gate and finger print analysis). This article presents a literature review referring to the understanding the various methods employed in forensic odontology.

**Key Words:** - Bite marks, Cheiloscopy, Dental Identification, Forensic Odontology, Rugoscopy

### Introduction

Forensic Odontology plays an important role in the identification of human remains and a dental surgeon is actively involved in various objectives of forensic odontology like age and sex determination, personal identification of unknown deceased person, analysing bite marks as evidence, participating in mass disaster, studying lip prints, giving evidence in child abuse and in civil and criminal litigation. His role in personal identification and criminal investigation is very much important, as this evidence would be very much useful in law and justice.<sup>1</sup> In forensic identification, the mouth allows for a myriad of possibilities. Collection of information from bite marks, lip prints and teeth in crime scenes such as murder and rape can play a major role in criminal investigations.<sup>2</sup> The word 'forensic' is derived from the Latin word 'forensic' meaning "before the forum". In Roman times the forum, meant 'Public Square.' In today's usage, forum refers to belonging to, used in or suitable to courts of adjudication. It may also refer to public discussion or debate. Forensic science is defined as the study and practice of the application of science for the purpose of law.<sup>3</sup>

Forensic Odontology has been defined by the Federation Dentaire Internationale (FDI) as 'that branch of dentistry which, in the interest of justice, deals with the proper handling and examination of dental evidence, and with the proper evaluation and presentation of dental findings'.<sup>4</sup>

It is an area of specialization under dentistry and also under forensic medicine as the knowledge of both the fields is vital for its activities. The term forensic dentistry is also used interchangeably with forensic odontology.<sup>4</sup>

Forensic Odontology, which is a branch of forensic medicine, has been defined by Keiser, "as that branch of odontology which in the interest of justice deals with the proper handling and examination of dental evidence and

with the proper evaluation and presentation of dental findings".<sup>5</sup>

There are three major areas of activity currently in forensic odontology namely:

1. The examination and evaluation of injuries to teeth, jaws, and oral tissues resulting from various causes (abuse, assault, mass disasters and crime related injuries).
2. The examination of marks with a view to subsequent elimination or possible identification of a suspects the perpetrator.
3. The examination of dental remains (whether fragmentary or complete, and including all types of dental restorations) from unknown persons or bodies with a view to the possible identification of the latter.<sup>6</sup>

Many different methods employed in forensic Odontology for identification include Bite mark analysis, Rugoscopy, Cheiloscopy, Dental DNA analysis, Radiographs, Photographic study, tooth printing, Dental records and habits of an individual etc.<sup>7</sup>

### Cheiloscopy

One of the most interesting emerging method of human identification which originates from the criminal and forensic practice is human lip print recognition.<sup>8</sup> Lip prints are the normal lines and furrows in the form of wrinkles and grooves present in the zone of transition of the human lip between the inner labial mucosa and outer skin, the study of which is known as Cheiloscopy. Lip prints are genetic, once developed at the 6th month of intrauterine life. They are permanent, unchangeable even after death and unique to each person except in monozygotic twins.<sup>2</sup> Fischer was the first anthropologist to describe the furrows on the red part of the human lips in 1902.<sup>9</sup> In 1930, Diou de Lille developed some studies which led to lip print use in criminology and in 1932, Edmond Locard, one of France's

greatest criminologists, acknowledged the importance of Cheiloscopy in crime investigation.<sup>10,11</sup> In the period between 1968-1971, Suzuki and Tsuchihashi examined 1364 persons at the Department of Forensic Odontology at Tokyo University and established that the arrangement of lines on the red part of human lips is individual and unique for each human being. Two years later, Tsuchihashi and Suzuki developed another study and proposed a new classification for lip prints. They further evaluated in other studies, the principles of heredity of furrows on the red part of the lips.<sup>12</sup>

**CLASSIFICATION OF LIP PRINTS:**

*Suzuki and Tsuchihashi classification: (1970)<sup>13</sup>*

These authors considered six different types of grooves, as seen in Table 1 & Figure 1

- Type I: Clear cut grooves running vertically across the lip.
- Type I': Straight grooves that disappear half way in to the lip instead of covering the entire breadth of the lip or partial-length grooves of type I.
- Type II: The grooves fork in their course or a branched groove.
- Type III: An intersected groove
- Type IV: A reticular groove
- Type V: Grooves do not fall into any of the type I to IV (morphologically undifferentiated)

Classification	Groove type
Type I	Complete vertical
Type I'	Incomplete vertical
Type II	Branched
Type III	Intersected
Type IV	Reticular pattern
Type V	Irregular

Table 1 Classification proposed by Suzuki and Tsuchihashi<sup>12</sup>

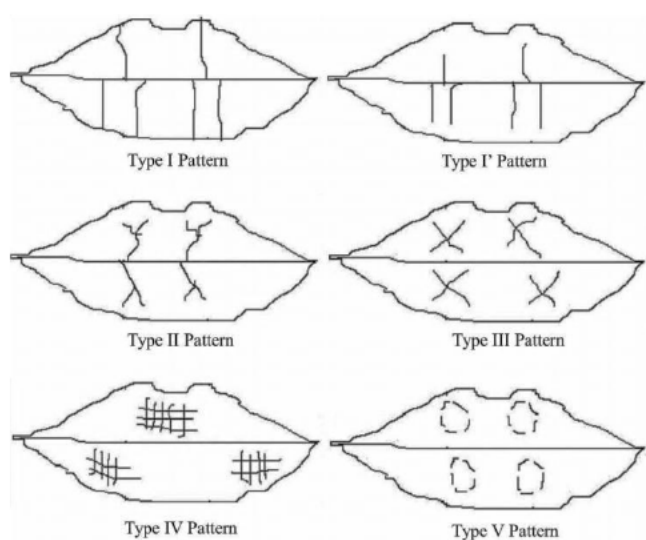


Figure 1 Different type of lip prints (Suzuki & Tsuchihashi)

**Bite marks**

The science of identification of bite mark identification can be used to link a suspect to a Crime. Bite can be defined by Mac Donald as the mark made by human or animal teeth in the skin of alive people, cadavers or unanimated objects with relatively softened consistence.<sup>14</sup> Bite marks depending upon the crime or circumstances are impressions left on food, skin or other items left at a scene. In assault cases they may be found on the victim. Besides the agent identification, bite mark analysis, in a forensic investigation, can elucidate the kind of violence and the elapsed time between its production and the examination. It can show if the bite was produced intra-vitam or post-mortem and, in case of several bite marks, identify the sequence of them.<sup>9</sup> There are many drawbacks of bite mark analysis. The size of the bitemark may shrink in size in a relatively short duration (10-20 minutes) and this necessitates their recording at the earliest possible time.<sup>15</sup> Incomplete bite marks are not conclusive and a minimum of four to five teeth have to be present for reliable bite mark analysis.

**Classification of bite marks:<sup>16</sup>**

Several classification systems have been proposed for the bite marks.

- 1: **Cameron and Sims' classification:** A simple classification based on the type of agent producing the bite marks and material exhibiting it.

**Agent:** Human and Animal

**Materials:** Skin, body surface, food stuff, other materials

2. **MacDonald's classification:** Most commonly followed classification and it is a etiological classification.

**Tooth pressure marks:** Marks produce on tissue as a result of direct application of pressure by teeth. Generally produced by incisal or Occlusal surfaces of teeth.

**Tongue pressure marks:** When sufficient amount of tissue is taken in to the mouth, the tongue presses it against rigid areas such as the lingual surface of teeth and palatal surface. These marks referred as suckling. There is a combination of sucking and tongue thrusting.

**Tooth scrape marks:** These marks caused due to scraping of teeth across the bitten material. They are usually caused by anterior teeth and present as a scratches or superficial abrasions.

3. **Webster's classification:** classification based on the depth of teeth on the food stuff

- Type 1:** The food items fractures readily with limited depth of tooth penetration. e.g. Hard chocolate
- Type 2:** Fracture of fragment of food item with considerable penetration of teeth. E.g. marks on fruits
- Type 3:** Complete penetration on food items with slide marks. E.g. cheese



*Study of palatal rugae (Rugoscopy)*

Use of human palatal rugae has been suggested as an alternative method for identification when teeth are lost due to any reason, the most common of which is trauma. Palatal rugae are formed in the third month in utero from the hard connective tissue covering bone. The pattern orientation is formed by about 12th to 14th week of prenatal life and remains stable until the oral mucosa degenerates after death. The palatine rugae possess unique characteristics that can be used in circumstances when it is difficult to identify a dead person through fingerprints or dental records.<sup>17</sup> The application of palatal rugae patterns for personal identification was first suggested by Allen in 1889. A common concern about palatal rugae voiced by many researchers is the possibility of rugae pattern changing with age and other outside influences. Orthodontic movement, extraction of teeth, cleft palate surgery, periodontal surgery, and eruption of an impacted canine are only some of the concerns. This method of identification can be used only when an ante-mortem record of the palatal rugae is available. This could simply consist of existing dental casts.

**CLASSIFICATION OF PALATAL RUGAE:**1. *Lysell's Classification*<sup>18</sup>

Lysell, in 1955, developed the first classification system for palatal rugae pairs which is widely accepted. It is comprehensive and includes the incisive papilla. Rugae are measured in a straight line between the origin and termination and are grouped in three categories:

- Primary: 5 millimetres or more
- Secondary: 3-5 millimetres
- Fragmentary: 2-3 millimetres

2. *da Silva classification*<sup>19</sup>

In this classification, palatal rugae are divided into two groups: simple, from 1 to 6 (Table 2) and composed, resulting from two or more simple rugae. They are named according to each rugae number. It is possible to classify each rugae individually (describing its form), but also to describe all the palatal rugae system (describing each rugae type number), making this a difficult classification to use.

Table 2: *da Silva palatal rugae classification*

Classification	Rugae type
1	Line
2	Curve
3	Angle
4	Circle
5	Wavy
6	Point

*DNA Analysis*

Teeth present as an excellent source as DNA material<sup>20</sup> and its sources are pulp, dentine, cementum and periodontal ligament fibres. DNA from teeth and bone are preserved for many years even after putrefaction of remains. The other sources include saliva and mucosal swabs. Saliva may also

be isolated from various sources in the crime scene, for example, postage stamps and envelopes, glasses, cigarettes, straws, food and chewing gum, toothbrushes and dental floss, and dental impressions. Use of DNA for human identification is proved to be very effective and has been documented. Polymerase chain reaction (PCR) technique allows amplification of DNA from even negligible amounts of source material. The amplified DNA is then compared with ante-mortem samples such as stored blood, hairbrush, clothing, cervical smear, biopsy specimens. Other methods include Restriction fragment length polymorphism (RFLP), single nucleotide polymorphism-based (SNP) and micro-assays. DNA can also help in identification of a parent or sibling. Most of these techniques involve nuclear DNA but mitochondrial (mt) DNA is more abundant, and can be identified in cases when nuclear DNA is insufficient. Dental tissues like dentin and cementum are rich in mtDNA.<sup>6</sup>

*Radiographs*

The utilization of radiographs in identification is valuable if sufficient ante mortem records are available. Various morphological and pathological alterations can be studied from the radiographs. Crown and root morphology aids in identification. The presence of decayed, missed, filled, and fractured teeth, various stages of wound healing in extraction sockets, degree of root formation, and bone trabecular pattern in the jaws aid in identification. However in countries like India ante mortem records are meagre and incomplete or improper.<sup>20</sup>

*Examination of tooth prints (Amelogyphics)*

Ameloblasts lay down the enamel rods in an undulating and intertwining path. This is reflected on the outer surface of the enamel as patterns of the ends of a series of adjacent enamel rods. This study of the enamel rod end patterns is termed as Amelogyphics by Manjunath et al. and could aid as a tool in decomposed or burned bodies as enamel can resist decomposition. This study needs antemortem records. Though enamel is the hardest mineralized substance in human body, the enamel surface is usually subjected to micro and macrowear. Fractured, decayed, attrited, abraded, and eroded teeth cannot be included in this method. Amelogyphics is still in its infancy and whether the tooth prints are the same at different depths of enamel has to be evaluated with further studies.<sup>7</sup>

*Dental record and identification*

Dental identification assumes a primary role in the identification of remains when post-mortem changes, traumatic tissue injury or lack of a fingerprint record invalidate the use of visual or fingerprint methods. The identification of dental remains is of primary importance when the deceased person is skeletonized, decomposed, burned or dismembered. The principal advantage of dental evidence is that, like other hard tissues, it is often preserved after death. Even the status of a person's teeth changes throughout life and the combination of decayed, missing and filled teeth is measurable and are comparable. Dental

identification is dependent on the availability, adequacy and accuracy of ante-mortem dental records that can be compared with the post-mortem dental findings. During the collection of dental post-mortem examination following information should be noted.<sup>1</sup>

*Table 3 Post-mortem Dental Findings<sup>1</sup>*

1	Dental arch shape, alignment, occlusion
2	Number and position of teeth present and missing
3	Size, shape, position and material of any restorations, presence and position of decayed surfaces
4	Denture and other appliance design and material
5	Individual tooth characteristics, for example tooth wear, fractures, anomalies of size, shape and color
6	Hard tissue and soft tissue (if present) status, abnormalities or pathologies
7	Any other findings of interest, or clues to age, race, diet, occupation etc.
8	Labelled prosthesis

#### *Habits*

Habits such as smoking or betel nut chewing are found by the presence of stains and the presence of erosion suggests alcohol or substance abuse. Pipe stems, cigarette holders, hairpins, carpet tacks or previous orthodontic treatment show unusual wear pattern. Socioeconomic status is assessed by the quality, quantity and presence or absence of dental treatment.<sup>6</sup>

#### *Age Determination*

Dental structures can provide useful indicators to the individual's chronological age. The age of children (including fetuses and neonates) can be determined by the analysis of tooth development and subsequent comparison with developmental charts. Third molar development is used by some forensic dentists to assign age to young adults. Periodontal disease progression, excessive wear, multiple restorations, extractions, bone pathosis and complex restorative work may indicate an older individual. Labelled dentures can be of great assistance in the identification of individuals. Unlabelled dentures have been recovered from patients and then fitted to casts retained by the treating dentist or laboratory, and this has been an accepted method of identification.<sup>21</sup>

#### *Photographs*

Photographs are valuable substitutes for written records and can overcome language barriers. However, photographs have considerable inherent limitations and stringent requirements are needed for accurate reproduction. The basic difficulty arises when three-dimensional objects are replicated as two-dimensional photographs, which can create distortion, and color change. Photographs are sometimes associated with parallax errors. Lighting, camera orientation, close-up capability, and stability are extremely critical factors while taking photographs.<sup>7</sup>

#### **Conclusion**

Forensic odontology plays an important role in medico-legal death investigations in mass disasters, especially transportation mishaps such as aircraft accidents where fragmentation and thermal injuries are common. A consistent effort has been made to computerize much of the data to improve comparative efforts. Today it is not unusual to observe a forensic odontologist working alongside identification teams at an air crash, gathering bite mark evidence at a crime scene, or examining a victim of child abuse. Therefore, dental professionals working on the field of Forensic Dentistry should incorporate new technologies in their work to improve their investigations.

#### **References**

1. Datta P, Sood S. Contemporary Practices Employed in Forensic Odontology. *Indian J Forensic Odontol* 2012;5:6-10.
2. Rastogi P, Parida A. Lip prints: an aid in identification. *Aust J Forensic Sci* 2011;1:1-8.
3. Definition of Forensic Odontology. [http://en.Wikipedia.org/wiki/Forensic\\_science](http://en.Wikipedia.org/wiki/Forensic_science)
4. Acharya AB, Sivapathasundharam B. Forensic Odontology. *Shafer's Textbook of Oral Pathology* 5th Ed. Elsevier 2006;1199-1227.
5. Bailoor DN, Mody RN. Forensic Odontology in Dental Practice. In Bailoor DN, Nagesh KS. *Fundamentals of Oral Medicine and Radiology*, 1<sup>st</sup> ed. New Delhi, Jitendar P Vij, 2005;333-342.
6. Prasad S, Sujatha G, Sivakumar G, Muruganandhan J. Forensic Dentistry: what a dentist should know. *Ind J Multidisciplin Dent* 2012;2(2):443-447.
7. Kavitha B, Einstein A, Sivapathasundharam B, Saraswathi TR. Limitation in forensic odontology. *J Forensic Dent Sci* 2009;1(1):8-10.
8. Reddy LVK. Lip prints: An overview in forensic dentistry. *J Adv Dent Res* 2011;3(1):17-20.
9. Prabhu RV, Dinkar A, Prabhu V. Study of Lip Print Pattern: A Digital Approach. *Indian J Forensic Odontol* 2012;5(2):47-54.
10. Gupta S, Gupta K, Gupta OP. A study of morphological patterns of lip prints in relation to gender of North Indian Population. *J Oral Biol Craniofacial Res* 2011;1(1):12-16.
11. Singh H, Chhikara P, Singroha R. Lip Print as evidence. *J Punjab Acad Forensic Med Toxicol* 2011;11(1):23-25.
12. Datta P, Sood S, Sabarwal JR. Cheiloscropy as a Tool for Human Identification. *Indian J Forensic Odontol* 2012;5(1):17-13.
13. Prabhu VR, Dinkar AD, Prabhu VD Rao PK. Cheiloscropy: Revisited. *J Forensic Dent Sci* 2012;4(1):47-52.
14. Strom F. Investigation of bite marks. *J Dent Res* 1963;42(1):312-316.
15. Utsuno H, Kanoh T, Tadokoro O, Inoue K. Preliminary study of post mortem identification

- using lip prints. *Forensic Sci Int* 2005;149(2-3):129-132.
16. Acharya AB, Sivapathasundharam B. *Forensic Odontology. Shafer's Textbook of Oral Pathology* 5<sup>th</sup> ed, Elsevier, 2006; 1199-1227.
  17. Sadler TW. *Langman's medical Embriology*. Baltimore; Williams and Wilkins, 1990; 316-20.
  18. Lysell L. Quoted in Patil MS, Achazya A B. Palatine rugae and their significance in clinical dentistry: A review of literature. *J Am Dent Assoc* 2008;139(11):1471-1478.
  19. Caldas IM, Magalhaes T, Afonso A. Establishing identity using cheiloscopy and palatoscopy. *Forensic Sci Int* 2007;165(1):1-9.
  20. Ratnakar.P, Singaraju GS. Methods of identification in forensic dentistry. *AEDJ* 2010;2:26-28.
  21. Zakirulla M, Allahbaksh M. Modern Tools in Forensic Dentistry. *Int. J Contempor Dent* 2011;2(3):28-32.

**Corresponding Address**

Dr.Bhagwat Sharma  
Post Graduate Student,  
Department of Oral Pathology & Microbiology,  
Institute of Dental Sciences & Technology,  
Modinagar, Uttar Pradesh  
Email Id: - chandyogesh18@gmail.com