

UNICYSTIC AMELOBLASTOMA OF A MANDIBLE :A RARE CASE REPORT

Bhardwaj S,¹ Bhardwaj D,² Yeluri G,³ Jain S⁴

1. Post Graduate Student, Department of Oral Pathology & Microbiology, Maharana Pratap College of Dentistry & Research Centre, Gwalior, MP.
2. Senior Lecturer, Department of Oral Medicine & Radiology, Maharana Pratap College of Dentistry & Research Centre, Gwalior, MP.
3. Senior Lecturer, Department of Oral Medicine & Radiology, Teerthanker Mahaveer Dental College & Research Centre, Moradabad, UP.
4. Post Graduate Student, Department of Oral Medicine & Radiology, K. D. Dental College & Hospital, Mathura, UP.

Abstract

Ameloblastoma is considered as a true neoplasm of odontogenic epithelial origin which is reported as second most common odontogenic neoplasm, after odontomes in reported occurrence rate. Its incidence and clinical behavior, makes ameloblastoma one of the most important odontogenic neoplasm. Unicystic ameloblastoma (UA) clinically and radiographically one of the most important odontogenic neoplasm. Unicystic ameloblastoma (UA) clinically and radiographically shows features of a cyst, but histologically shows cystic cavity lined by epithelium with typical ameloblastomas changes, with or without luminal and/or mural tumor growth. It accounts for 10 % - 46 % of all intra osseous ameloblastomas. We hereby report a case of unicystic ameloblastoma in a 70 – years old male patient.

Key words: Ameloblastoma, Mandible, Odontogenic tumors.

Introduction

Mandibular swellings may occur as a result of many benign lesions of odontogenic or non-odontogenic origin. Ameloblastoma is one of the most common tumors originating from odontogenic epithelial cellular elements and dental tissues in various stages of development. It is a slow-growing, persistent and locally aggressive neoplasm, involving the posterior vicinity of lower jaw in 80% of cases. There are three variants of ameloblastoma; solid/multicystic, peripheral and unicystic.^{1,2}

The unicystic ameloblastoma (UA) is a less encountered variant of the ameloblastoma. It frequently occurs in the second or third decade with no gender and racial predilection. It is encountered almost asymptotically in the posterior region of mandible. The clinical and radiological simulation of an UA with mandibular cyst often leads to simple surgical procedure i.e enucleation of lesion.³

This report emphasizes the importance of histopathological analysis of any pathology in jaws even if it appears harmless in clinical and radiological screening.

Case Report

A 70 year old male edentulous patient reported to the department of Oral Medicine and Radiology at K.D Dental College and Hospital, Mathura with chief Complaint of swelling in his Right posterior mandible region since one and a half month which gradually increases to attain the present size. Swelling was painless. Patient also gives history of extraction of the tooth of same region two months back.

On extra oral examination no facial asymmetry was appreciated. (Figure1) On intra oral examination during inspection, a solitary swelling was present irt to Right mandibular posterior region ,ovoid in shape of size 1 x 2 cm extending 3 cm away from midline till premolar region and 4 cm ahead of retromolar area, Mediolaterally it is extending from alveolar ridge of 44 & 45 region to 1 cm laterally in the buccal vestibule with smooth surface and well defined borders.

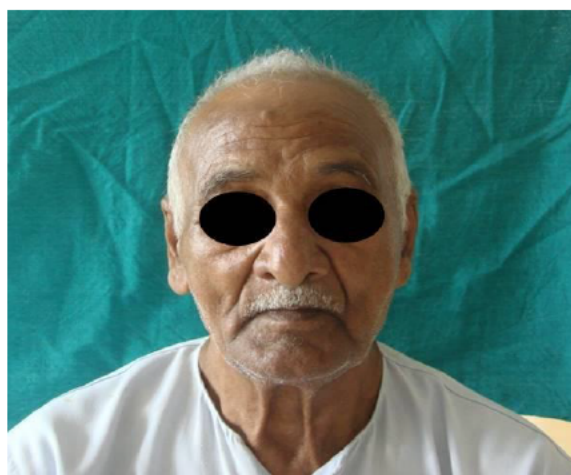

Figure 1: Extra oral photograph showing no facial asymmetry

On palpation number, site, shape, size margins and extensions were confirmed. Swelling is firm to hard in consistency and is not associated with any kind of discharge. (Figure 2)

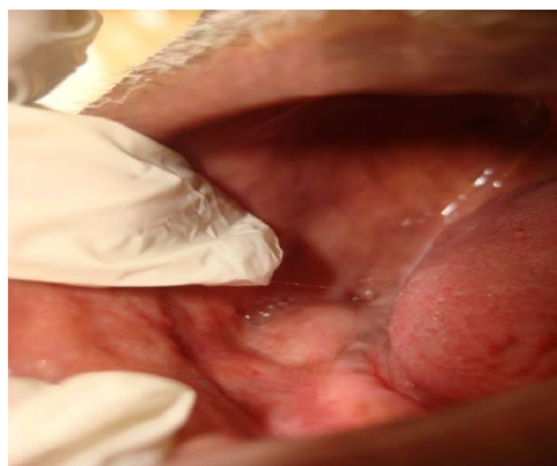

Figure 2: - Intraoral photograph showing swelling at right alveolar mucosa irt 44 & 45 obliterating buccal vestibule

A provisional diagnosis of Residual Cyst in relation to right posterior mandibular region was made and differential

diagnosis of Ameloblastoma, Central giant cell granuloma, Odontogenic keratocyst, Ossifying fibroma, Osteomyelitis were put forth. Orthopantomograph revealed mixed radio opaque radiolucent lesion of size approximately 1 x 1cm in relation to 44 and 45 tooth region with well defined margins anteriorly, posteriorly and inferiorly along with destruction of alveolar crest superiorly. (Figure 3)

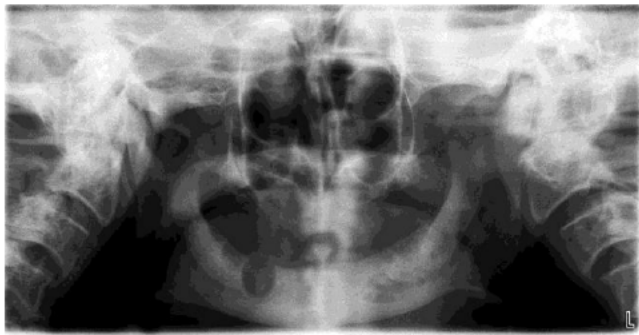


Figure 3: - OPG showing mixed radio opaque & radiolucent lesion in 44 & 45

Excisional biopsy was done and specimen was submitted to Histopathological examinations. Microscopically stained sections by haematoxylin and eosin showed cystic lumen with stratified squamous epithelium supported by connective tissue capsule. The cystic lining epithelium was thin and showed areas of ameloblastomatous epithelium with basal hyperchromatic palisaded layer of cuboidal and columnar cells. The overlying connective tissue capsule is made up of dense and loose connective tissue with areas of mild inflammatory infiltrates and blood vessels. (Figure 4)

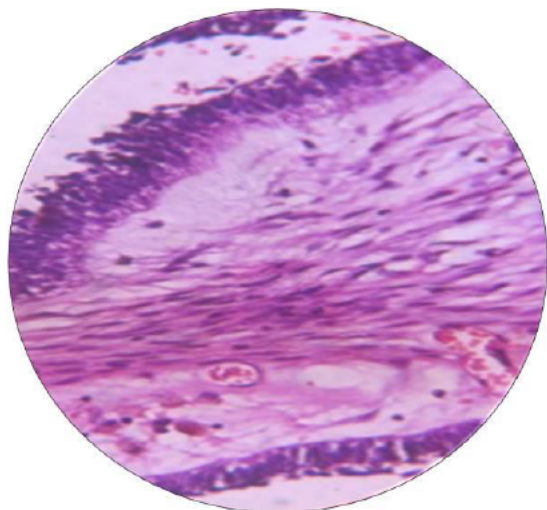


Figure 4: - Photomicrograph (Magnification 40x) showing cuboidal and columnar ameloblastomatous epithelial cells.

The final diagnosis of Unicystic Ameloblastoma in Right Mandibular Posterior region was thus made.

Discussion

Unicystic ameloblastoma (UA) is a rare subtype of ameloblastoma, accounting for about 6% of intra osseous ameloblastomas. Its manifestation involves younger age

group, with almost 50% of the cases in the second decade of life and more than 90% are located in the mandible.^{3,4,5}

Patients commonly present with moderate to severe swelling and facial asymmetry, pain being an occasional presenting symptom. Ulceration in mucosa is rare, but may be caused by continued and aggressive growth of the tumor. Small lesions are sometimes revealed on routine radiographic screening examinations or as a result of local factors (like mobility in teeth, occlusal alterations and failure of eruption of teeth) produced by the tumor.⁶ In our case patient was an adult with mild swelling intraorally and no facial symmetry.

Histologically, the minimum criterion for diagnosing a lesion as UA is the demonstration of a single cystic sac lined by odontogenic (ameloblastomatous) epithelium which often occurs focally.

UA should be differentiated from odontogenic cysts as the UA has a relatively higher recurrence rate.⁷

In a clinicopathologic study of 57 cases of unicystic ameloblastoma, Ackermann histologically classified it into the following three groups:²

- A. Group I: Luminal UA (tumor limited to the luminal surface of the cyst).
- B. Group II: Intraluminal/plexiform UA (nodular proliferation into the lumen without infiltration of tumor cells into the connective tissue wall),
- C. Group III: Mural UA (invasive islands of ameloblastomatous epithelium in the connective tissue wall not involving the complete epithelium).

Another histological subgrouping by Philipsen and Reichart has also been described:⁸

- Subgroup 1: Luminal UA
- Subgroup 1.2: Luminal and intraluminal UA
- Subgroup 1.2.3: Luminal, intraluminal and intramural UA
- Subgroup 1.3: Luminal and intramural UA

In present case the histological diagnosis revealed a single cystic cavity lined by ameloblastomatous epithelial lining thus showed features of Luminal UA which is subgroup 1 according to Philipsen and Reichart.

The UAs diagnosed as subgroups 1 and 1.2 can be conservatively treated with enucleation, whereas subgroups 1.2.3 and 1.3 showing intramural growths require treated radical resection, as for a solid or multicystic Ameloblastoma.³

Conclusion

In the present case, the diagnosis was made possible only by histopathologic examination performed of the enucleated material. Hence, we conclude that the clinician should be aware of differential diagnosis of such kind of case and surgical procedure must include the postoperative histopathological examination for proper assessment of

any ameloblastomatous changes, so that the proper and correct treatment plan can be given to the patient.

References

1. Gerzenshtein J, Zhang F, Caplan J, Anand V, Lineaweaver W. Immediate mandibular reconstruction with microsurgical fibula flap transfer following wide resection for ameloblastoma. *J Craniofac Surg* 2006;17(1):178–82.
2. Philipsen HP, Reichart PA. Classification of odontogenic tumors and allied lesions; London: Quintessence Pub Co Ltd; 2004. 21–23.
3. Philipsen HP, Reichart PA. Unicystic ameloblastoma. Odontogenic tumors and allied lesions; London: Quintessence Pub; 2004; 77–86
4. Pizer ME, Page DG, Svirsky JA. Thirteen-year follow-up of large recurrent unicystic ameloblastoma of the mandible in a 15-year-old boy. *J Oral Maxillofac Surg* 2002;60(2):211–5.
5. Navarro CM, Principi SM, Massucato EM, Sposto MR. Maxillary unicystic ameloblastoma. *Dentomaxillofac Radiol* 2004;33(1):60–2.
6. Roos RE, Raubenheimer EJ, van Heerden WF. Clinico-pathological study of 30 unicystic ameloblastomas. *J Dent Assoc S Afr* 1994;49:559–62.
7. Konouchi H, Asaumi J, Yanagi Y, Hisatomi M, Kawai N, Matsuzaki H *et al*. Usefulness of contrast enhanced-MRI in the diagnosis of unicystic ameloblastoma. *Oral Oncol* 2006;42(5):481–6.
8. Chana JS, Chang YM, Wei FC, Shen YF, Chan CP, Lin HN *et al*. Segmental mandibulectomy and immediate free fibula osteoseptocutaneous flap reconstruction with endosteal implants: An ideal treatment method for mandibular ameloblastoma. *Plast Reconstr Surg* 2004;113(1):80–87.

Corresponding Author

Dr. Deepti Bhardwaj
Senior Lecturer,
Department of Oral Medicine & Radiology,
Maharana Pratap College of Dentistry & Research Center,
Gwalior, Madhya Pradesh.
Email Id: - diptibhrdwj@gmail.com