

FULL MOUTH REHABILITATION USING TWIN STAGE PROCEDURE – A CASE REPORT

Verma K,¹ Gowda EM,² Kalra A,³ Verma R⁴

1. Graded Specialist, Division of Prosthodontics, 12 Corps Dental Unit

2. Dy Commandant & Senior Specialist, Division of Prosthodontics, CMDC

3. Graded Specialist, Division of Prosthodontics, 21 Corps Dental Unit

4. Dental Surgeon, ECHS Polyclinic, Jodhpur, Rajasthan.

Abstract

Full mouth rehabilitation of a severely worn out dentition managed by Twin-stage procedure to achieve definite aesthetic and occlusal scheme favorable to the patient. Diagnostic maxillary and mandibular impressions were made and articulated. Diagnostic wax up was done according to Condition 1 and 2 of Hobo's Twin stage procedure followed by full mouth rehabilitation with porcelain fused to metal full coverage fixed partial dentures and crowns at an acceptable increased vertical dimension of occlusion. The treatment goal was to rehabilitate the patient with coinciding centric relation and centric occlusion by eliminating posterior interferences, restoring the worn out surfaces to enhance functional efficiency and aesthetics.

Key words: Aesthetics, Disocclusion, Twin Stage.

Introduction

Aesthetic and functional restoration of the severely worn dentition represents a significant clinical challenge.¹ One of the most demanding aspects of such cases involves the development of sufficient restorative space, while simultaneously fulfilling aesthetic, occlusal, and functional parameters essential for long-term success.² The treatment planning and execution requires a multidisciplinary approach but overall responsibility and decision making lies with the prosthodontist in selecting an appropriate occlusal scheme, rehabilitating the occlusion at a correct vertical dimension so as to establish the harmony of stomatognathic system.

This clinical report describes a case of full mouth rehabilitation of a severely worn out dentition managed by Twin-stage procedure to produce definite aesthetic and occlusal scheme favorable to the patient.

Case Report

A 58 years old male patient complained of multiple discoloured, worn out upper and lower teeth and difficulty in chewing. Medical history revealed that patient was hypertensive, diabetic and was on medications following bypass surgery he had undergone 05 years back. Clinical examination revealed severe attrition and abrasion involving multiple maxillary and mandibular teeth with near pulpal exposure. 14, 17, 18, 28, 37, 41 and 48 were missing. [Figure 1, 2]

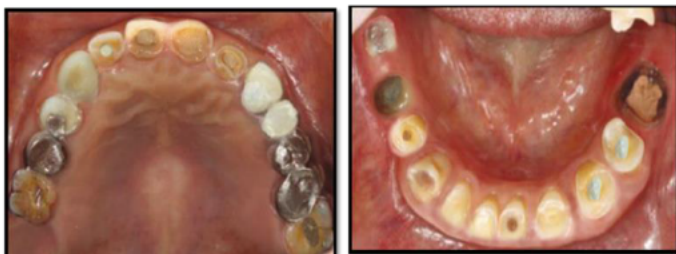

Figure 1: Maxillary and mandibular preoperative occlusal view

The freeway space recorded was around 09 mm. No abnormality was detected in temporomandibular joints and

muscles of mastication. Periodontal charting was carried out and treatment plan was formulated involving oral prophylaxis, crown lengthening of few teeth, extraction of periodontally involved 48, endodontic treatment of pulpally involved maxillary and mandibular teeth, followed by full mouth rehabilitation with porcelain fused to metal full coverage fixed partial dentures and crowns at an acceptable increased vertical dimension of occlusion to improve esthetic and functional value of patient.

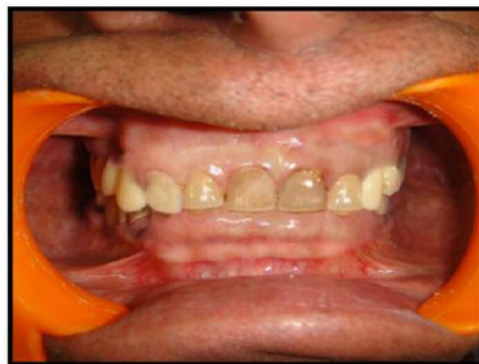

Figure 2: Intraoral frontal view in occlusion

Procedure

Diagnostic maxillary & mandibular impressions were made with irreversible hydrocolloid impression material and casts were retrieved. Occlusal equilibration was done in the patient's mouth by removing the occlusal interferences so that centric relation coincided with maximum intercuspal position. Again impressions were made and the casts were articulated using an earpiece face bow (Hanau Springbow) over which maxillary occlusal splint was fabricated at increased vertical dimension. The permissive occlusal splint at centric relation position for 12 weeks was given to determine acceptability of proposed change in occlusal scheme. [Figure 3]

Extraction of 48, endodontic therapy of pulpally involved teeth and crown lengthening of 11, 21, 34, 35, 42, 43 and 44 was carried to achieve optimum crown to root ratio. [Figure 4] Centric records were made at increased vertical dimension of occlusion of 4mm using anterior

deprogramming jig and triple tray technique in the patient's mouth. Casts were mounted on semiadjustable articulator (Hanau H2) for diagnostic wax up. Mandibular occlusal plane was analysed using Broadrick's occlusal plane analyser. [Figure 5]

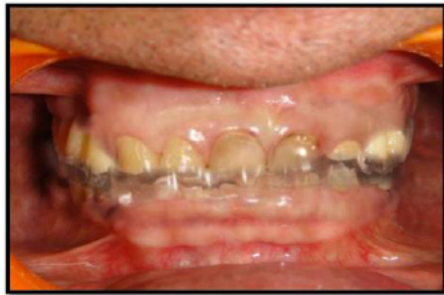

Figure 3: Permissive maxillary occlusal splint in situ

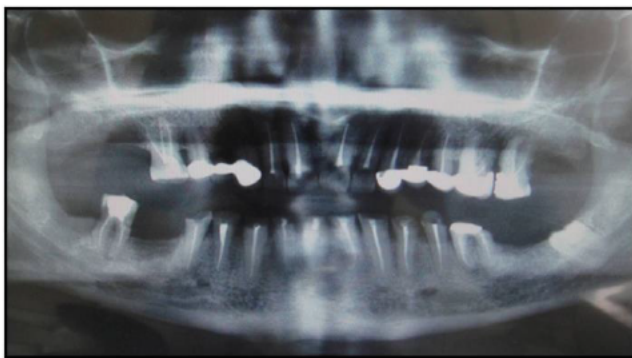


Figure 4: Orthopantomogram showing endodontic treatment done for pulpally involved teeth



Figure 5: Mandibular occlusal plane was analyzed using Broadrick's occlusal plane analyzer

The semi adjustable Hanau articulator was programmed to Condition 1 of Hobo's Twin stage procedure (Table 1) wherein posterior segment mock wax up was done in bilaterally balanced occlusion after removal of the maxillary anterior segment. [Figure 6a] The settings were changed to Condition 2 where the maxillary anterior segment was replaced and the anterior wax up was completed [Figure 6b] and checked for proper anterior guidance to achieve disocclusion in eccentric movements. Simultaneously twin tables were fabricated according to condition 1 and 2 using pattern resin. (GC Corp; Tokyo, Japan)

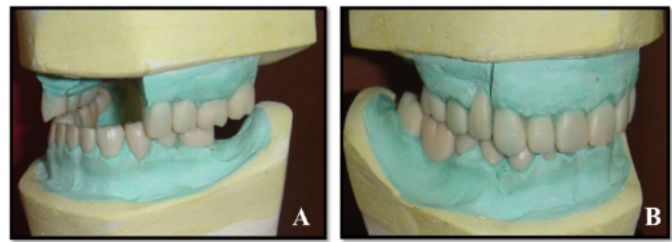


Figure 6: a) Diagnostic wax up in Condition 1
b) Diagnostic wax up in Condition 2

Condition	Condylar path		Anterior guide table	
	Sagittal condylar path inclination	Bennett angle	Sagittal inclination	Lateral wing angle
Condition 1: without anterior teeth	25	15	25	10
Condition 2: with anterior teeth	40	15	45	20

Table 1: Articulator adjustment values for the twin-stage procedure (degrees) [11, 12]

Tooth preparations for full coverage metal ceramic crowns were done for the maxillary and mandibular teeth. [Figure 7]

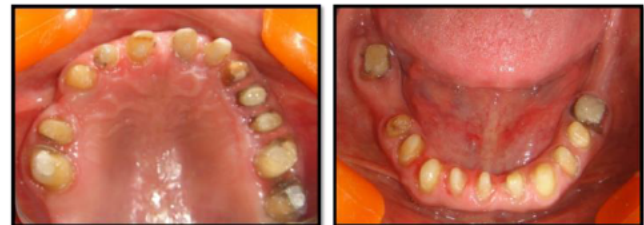

Figure 7: Maxillary and mandibular tooth preparations

A final full-arch impression for maxillary and mandibular teeth was made using polyvinyl siloxane (Aquadil, Dentsply, Germany) impression material with double-mix two stage putty wash impression technique [Figure 8] and casts were poured in die stone (Kalstone, Kalabhai, India). Casts were mounted on an articulator using centric inter-occlusal record at previously determined increased vertical dimension. Provisional restorations were made from the diagnostic wax-up template with autopolymerizing acrylic resin, and esthetics and occlusion were evaluated. Provisional crowns were cemented with zinc oxide non-eugenol cement (Rely X, 3M ESPE, Germany). [Figure 9]

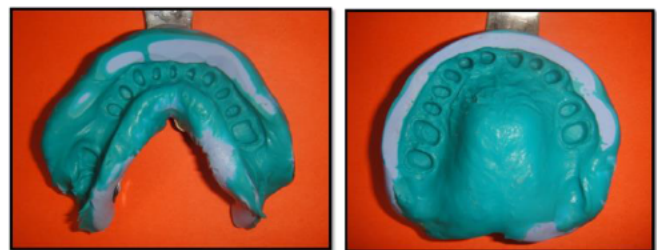

Figure 8: Maxillary and mandibular final impressions

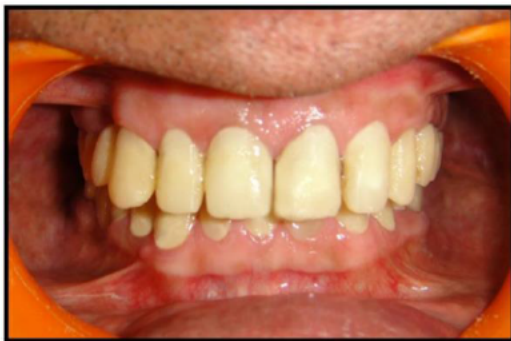

Figure 9: Provisional crowns in situ

Wax build up was done and casted. [Figure 10] Metal copings were tried in and adjusted. [Figure 11]

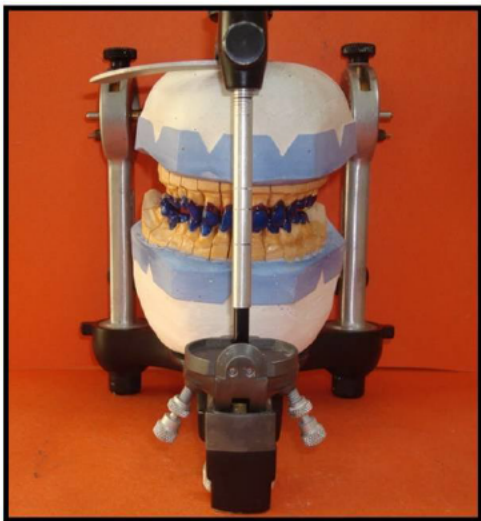


Figure 10: Wax pattern build up

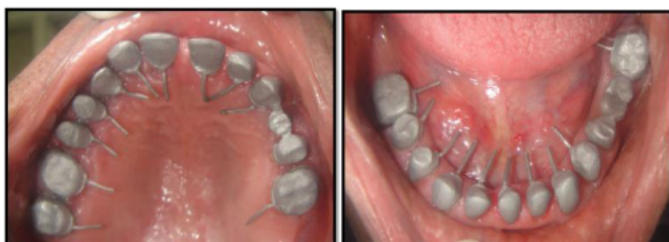

Figure 11: Metal try-in

Articulator was programmed to Condition 1 and 2 for ceramic build up of posterior and anterior segments respectively to achieve effective cusp angle of 25° posteriorly and incisal guidance of 40° anteriorly, which produced standard amount of disocclusion. Bisque try-in was done. Occlusal adjustments and equilibration was carried out and squash bite was made with Aluwax for remounting. Anterior guidance and disocclusion was verified using previously fabricated twin tables. Permanent restorations were cemented with glass ionomer type I (GC Fuji, Tokyo) luting cement [Figure 12] and oral hygiene instructions were given to the patient.

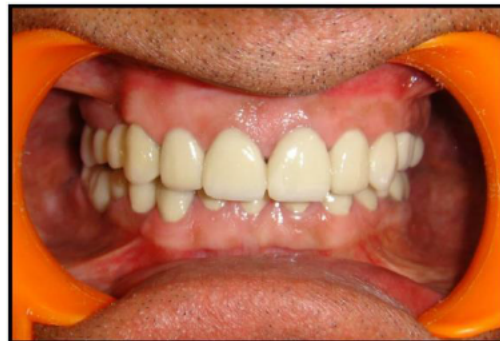

Figure 12: Definitive restorations in situ

Discussion

Treatment of reduced vertical dimension is not designed to increase it but is intended to restore the amount of vertical dimension lost. All our efforts for full mouth rehabilitation are directed towards re-establishing a state of functional efficiency in which the hard and soft tissues of stomognathic system function in synchronous harmony.³ Dawson stated that interocclusal space is never lost and any loss is compensated by tooth eruption, alveolar bone expansion and muscle action.^{4,5} The vertical dimension of occlusion (VDO) and vertical dimension at rest are not constant throughout life and the vertical dimension of occlusion can be raised upto vertical dimension at rest, being the minimal muscle activity position.⁶ In 1984, Turner and Missirlian⁷ classified the patients requiring full mouth rehabilitation into three categories: -

1. Excessive occlusal wear with loss of vertical dimension but with space available to restore the vertical height.
2. Excessive wear without loss of VDO but space available.
3. Excessive wear without loss of VDO but with limited space.

The rationale behind altering and raising the vertical dimension by 4 mm in the patient was to allow adequate inter occlusal space for the permanent restorations. A moderate increase in vertical dimension of occlusion does not seem to be a hazardous procedure, provided the occlusal stability is established.⁸

Stuart and Stallard in 1957 proposed cuspid protected occlusion concept which was given to the patient as it had many advantages over the group function.⁹ D'Amico stated that cuspid protected occlusion and disocclusion were natural adaptations for preventing destructive occlusion.¹⁰

Hobo and Takayama studied the influence of condylar path, incisal path, and the cusp angle on the amount of disocclusion and concluded that cusp angle was the most reliable and used as a new determinant of occlusion.¹¹ Twin-stage procedure proposed by Hobo and Takayama was adopted because studies have proved that it is possible to accurately control the amount of disocclusion on the restoration without measuring the condylar path.¹² Twin-stage procedure helps in achieving a standard disocclusion

of 1.1 mm on protrusion, 1 mm on nonworking side, and 0.5 mm on working side in eccentric movements at 3-mm protrusion from centric relation.

Conclusion

The reorganization of occlusion should be carried out only when there is good reason to do so. Proper diagnosis and treatment planning with adequate manual dexterity, knowledge and judgment is paramount and gateway to success. The treatment goal was to restore the centric relation, occlusion, eliminate posterior interferences, restore the worn out surfaces to enhance mastication and to improve the esthetic appearance.

References

1. Brown KE. Reconstruction considerations for severe dental attrition. *J Prosthet Dent* 1980;44(4):384-388.
2. Binkley TK, Binkley CJ. A practical approach to full mouth rehabilitation. *J Prosthet Dent* 1987;57(3):261-6.
3. Kazis H. Complete mouth rehabilitation through restoration of lost vertical dimension. *J Am Dent Assoc* 1948;37(1):19-39.
4. Dawson PE. *Functional Occlusion - From TMJ to smile design*. 1st ed. New York: Elsevier Inc.; 2008.
5. Thomson JR. The rest position of mandible and its significance to dental science. *J Am Dent Assoc* 1946;33:151.
6. Weinberg LA. Vertical dimension: a research and clinical analysis. *J Prosthet Dent* 1982;47(3):290-302.
7. Turner KA, Missirlian DM. Restoration of the extremely worn dentition. *J Prosthet Dent*. 1984;52(4):467-474.
8. Carlsson GE, Ingervall B, Kocak G. Effect of increasing vertical dimension on the masticatory system in subjects with natural teeth. *J Prosthet Dent* 1979;41(3):284-9.
9. Stuart CE. Good occlusion for natural teeth. *J Prosthet Dent* 1964;14:716-24.
10. Damico A. Function occlusion of natural teeth in man. *J Prosthet Dent* 1961;11:899-915.
11. Hobo S. Twin-tables technique for occlusal rehabilitation: Part I: Mechanism of anterior guidance. *J Prosthet Dent* 1991;66(3):299-303.
12. Hobo S. Twin-tables technique for occlusal rehabilitation: Part II: Clinical procedures. *J Prosthet Dent* 1991;66(4):471-477.

Corresponding Author

Maj. Kamal Verma
Graded Specialist,
Division of Prosthodontist,
12 Corps Dental Unit,
Near Military Hospital, Jodhpur, Rajasthan.
Email:- kamalverma_in@yahoo.com