

PUTTY SILICONE AS A GUIDE IN THE RESTORATIVE MANAGEMENT OF PRIMARY DOUBLE TOOTH: A CASE REPORT

Mishra A,¹ Yeluri R,² Garg N,³ Rallan M⁴

1. Post Graduate Student, Department of Pedodontics & Preventive Dentistry, TMDRC, Moradabad, UP
2. Professor & Head, Department of Pedodontics & Preventive Dentistry, TMDRC, Moradabad, UP
3. Reader, Department of Pedodontics & Preventive Dentistry, TMDRC, Moradabad, UP
4. Senior Lecturer, Department of Pedodontics & Preventive Dentistry, TMDRC, Moradabad, UP

Abstract

The phenomenon of fusion has always been confused with germination, especially if it involves a supernumerary tooth. Clinically, it may appear as two separate crowns or a double-the-normal size crown. The objective of this paper is to present a case of a 3 year old girl child with primary double tooth. The tooth was endodontically treated and esthetic management was done by using a silicone putty guide.

Key words: Fusion, Gemination, Odontogenic Developmental Anomalies.

Introduction

Odontogenic developmental anomalies are more frequently observed in primary dentition than in permanent dentition during routine intraoral examination. These variations can be numerical (hypodontia or hyperdontia), in tooth structure (size or shape), eruption wise (early or delayed), or a combination of these because of enamel and dentin malformation. Among the variations of tooth structure anomaly, co-joined teeth are most common.¹ Fusion also known as synodontia or false germination is a developmental dental anomaly and is defined as the union of two or more separately developing tooth germs at the dentinal level, yielding a single large tooth during odontogenesis, when the crown is not yet mineralized.² Its prevalence is higher in primary dentition than that in permanent dentition. It can occur between teeth of the same dentition or mixed dentitions, and between normal and super-numerary teeth. In both dentitions incisors are most commonly affected, although fusion of other teeth, including molars also occurs.³ This developmental anomaly is most often confused with germination. However, a differential diagnosis can be made radiographically. In case of fusion, the crowns are united by enamel and/or dentine, but there are two roots or two root canals in single root. On the other hand in gemination, the structure most often presents two crowns, either totally or partially separated, with a single root and one root canal.⁴

The etiology of double tooth is unknown, but trauma has been suggested as a possible cause apart from hereditary tendency. Double teeth are generally asymptomatic but problems like poor esthetics, malocclusion, changes in the dental arch length, hyper/hypodontia of the successional tooth, anomalies in the eruption of the permanent successors, periodontal disease or dental caries may be associated with it.⁵

The present article reports a case of fusion of right maxillary lateral incisor with a supernumerary tooth with two roots and two canals, which was treated non-surgically by endodontic treatment followed by esthetic rehabilitation using putty silicone as a guide.

Case Report

A 3 year old girl reported to the department of pedodontics and preventive dentistry with the chief complaint of decaying of upper front tooth region in the right side. The patient was asymptomatic 5 to 6 months back then her parents noticed blackish discoloration of the upper front tooth which increased with time. There was no family history of dental anomalies. General and extra-oral examinations appeared non-contributory. Intra-oral examination revealed the presence of an extra tooth, fused with maxillary right lateral incisor with caries on the line of developmental groove in the labial and palatal aspect. (figure 1)

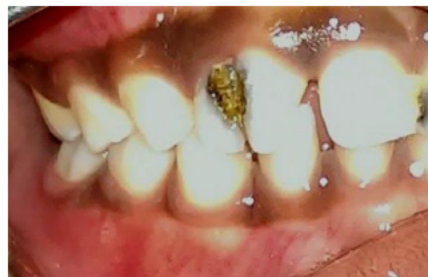

Figure 1: - Preoperative photograph showing supernumerary tooth along with maxillary right lateral incisor.

On radiographic examination, there was fusion of supernumerary tooth with maxillary right lateral incisor with two crowns in two roots. (figure 2)

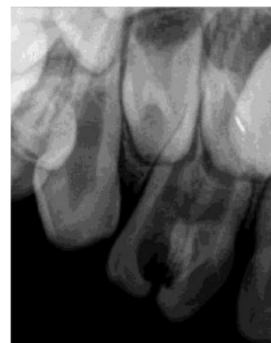

Figure 2: - Preoperative radiograph showing fusion of supernumerary tooth with maxillary right lateral incisor.

A pulp vitality test was performed and it was found that both the teeth were non-vital. Based on clinic-radiographic features and endodontic evaluation, a diagnosis of primary double tooth was made in relation to primary right maxillary lateral incisor. Treatment was planned and consent was taken after discussion with the parents, which included endodontic treatment of the affected tooth followed by esthetic rehabilitation using silicon putty as guide for composite buildup.

Endodontic Treatment

After administration of local anaesthetics, direct excavation of caries was done with spoon excavator and all the caries were removed from both labial and lingual surfaces of the fused supernumerary tooth and the right maxillary lateral incisor (figure 3).

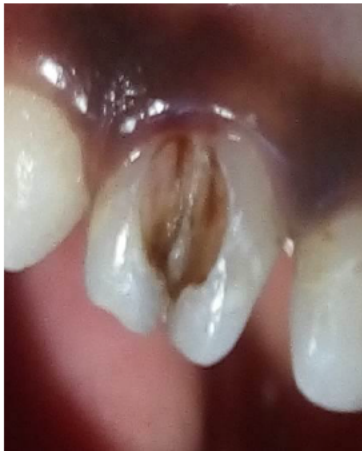

Figure 3: - After excavation of caries from the labial surface.

The excavation of the caries from the labial surface led to direct access into the canals. Shaping and cleaning of the canals was performed by using K-files and H-files (MAILLEFER, DENTSPLY India Pvt Ltd, Delhi, India). Irrigation of the root canals at every step was done with betadine and normal saline. The root canals were dried filled with zinc-oxide eugenol (Mfg, Deepak Ent, Ganeshdham, India).

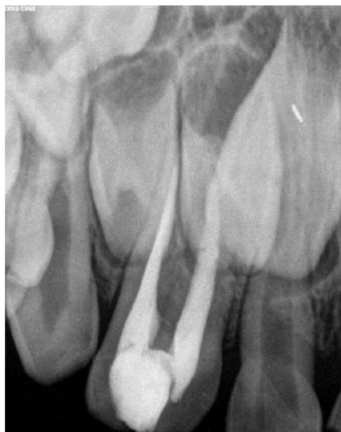

Figure 4: - After obturation with Zinc-oxide eugenol

Access cavity was sealed primarily with temporary restorative material (Orafil-G, Prevest DenPro, Ltd., Jammu, India) followed by glass ionomer cement (Mfg GC. Corp, Tokyo, Japan) (figure 4).

Esthetic Rehabilitation

Alginate impressions of both the upper and lower arches were taken and the models were poured using dental stone. The supernumerary tooth was scraped off on the model and a laboratory wax up was done to mimic the final esthetic contour of the single lateral incisor. (figure 5)

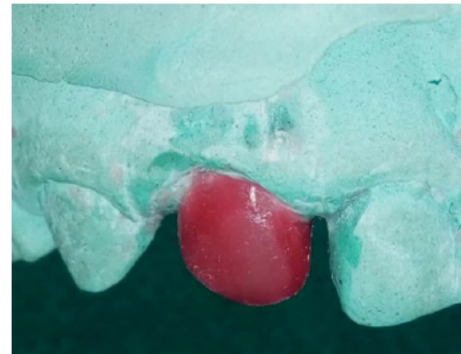

Figure 5: - Wax-up to mimic the final esthetic contour of the single lateral incisor

A composite build-up guide (stent) (figure 6A) was fabricated using addition type silicone elastomeric impression material (Aquasil soft putty/regular set, DENTSPLY Detrey GmbH, Konstanz, Germany).

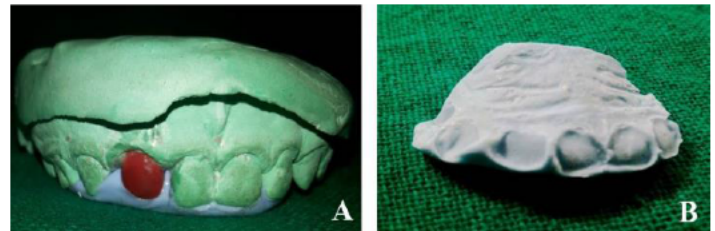


Figure 6: -
A: - Stent fabrication
B: - Stent showing registered palatal surface

The purpose of this stent was to register the palatal surfaces, proximal contours and the incisal edges of the right maxillary primary lateral incisor against which the composite resin would be built. Using this stent as a guide, the supernumerary teeth were trimmed using 700L diamond bur. (figure 6B)

The teeth were etched for 15 seconds with 37% phosphoric acid (Ammdent, Amrit Chem & Min Ag, Mohali, India) and rinsed for 10 seconds with water. After drying, dentine bonding agent (Adper™ Single bond 2, adhesive; 3M ESPE AG, Seefeld, Germany) was applied for 15 seconds with a brush and then light cured for 20 seconds. The stent was then positioned in the mouth and the palatal, proximal and incisal aspects were built with the composite restorative material (Filtek Z250; 3M ESPE AG, Seefeld, Germany) in

increments. This was followed by building up the facial surfaces. (figure 8)

Final finishing and polishing of the composite was done using finishing burs and composite kit (SHOFU, SHANK CA, PN0310, Shofu Dental Corporation, USA). A follow up was done with the patient after one month and a clinically acceptable result was obtained. (figure 9)

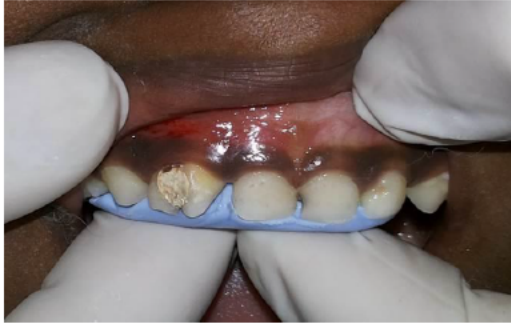

Figure 8: - Stent in mouth to build up palatal, proximal and incisal aspects.

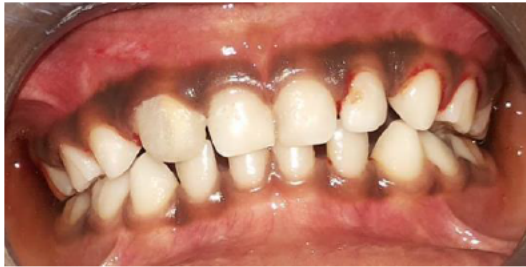

Figure 9: - Post operative photograph.

Discussion

In the present case, full complement of primary maxillary teeth were present and at the same time the two halves of the anomalous crown in relation to maxillary right lateral incisor were like mirror images, clinically indicating gemination. However, radio-graphically, there were separate pulp chambers and root canals confirming the fusion of maxillary right lateral incisor with supernumerary tooth. Prevalence of tooth fusion was estimated at 0.5% to 2.5% in the primary dentition, whereas prevalence in the permanent dentition seemed to be clearly lower than in primary dentition. However, primary teeth anomalies can affect the permanent successors significantly as there may be delayed resorption of root due to great root mass and increased area of root surface relative to the size of the permanent successor crown.⁶ Fused teeth may induce esthetic problems and malocclusions, especially when supernumerary elements are included. Since fused teeth are wider than the circumjacent teeth, esthetics may be a concern.⁷

Whenever fusion occurs, the groove created by the union of the involved teeth is deep and extend subgingivally which readily provides room for bacterial plaque accumulation. Pulpal involvement is common in such teeth and endodontic treatment is quite challenging because of

complex tooth anatomy. In our case, the endodontic treatment was followed by esthetic management with direct composite using silicone putty guide as done by Kulkarni *et al*⁵ and Agarwal *et al*.⁸ Strip crowns could also be a treatment option for esthetic management in such cases. However, this technique is an easy and accurate way to produce natural dentition anatomy.

Conclusion

Composite restoration on palatal surfaces of the anterior teeth using free-hand technique is difficult and requires more time and efforts to have a natural appearance. Therefore the use of stents allows easy restoration of the teeth with accurate incisal and proximal contours and less time consumption for trimming and polishing the restoration.

References

1. Mahajan SK, Dua P, Simran K, Ritu M. Unilateral co-joined primary teeth with and without partial anodontia of permanent dentition-Report of 2 cases. *Ind J Dent Sci* 2013;3(5):61-63.
2. Narayanan KS. Endodontic management of supernumerary tooth fused with maxillary second molar. *J Orofac Sci* 2013;5(1):47-49.
3. Delany GM, Goldblatt LI. Fused teeth: a multidisciplinary approach to treatment. *J Am Dent Assoc* 1981;103(5):732-734.
4. Prasad Rao VA, Reddy VN, Krishnakumar R, Sugumaran DK, Mohan G, Senthil Eagappan AR. Primary double tooth with partial anodontia of permanent dentition-a case report. *J Clin Exp Dent* 2010;2(2):79-81.
5. Kulkarni VK, Ragavendra TR, Deshmukh J, Vanka A, Duddu MK, Patil AKG. Endodontic treatment and esthetic management of a primary double tooth with direct composite using silicone buildup guide. *Contemp Clin Dent* 2012;3(suppl 1):S92-S95.
6. Veerakumar R, Pari MA, Prabhu MN. Caution! We are erupting as twins. *J Clin Diag Res* 2011;5(5): 1123-1124.
7. Sekerci AE, Sisman Y, Ertas ET, Gumus H, Ertas H. Clinical and radiographic Evaluation and comparison of six cases of fusion involving the primary dentition. *J Dent Child* 2012;79(1):34-39.
8. Agarwal R, Chaudhry K, Yeluri R, Munshi AK. Esthetic management of a primary double tooth using a silicone putty guide: A case report. *J Calif Dent Assoc* 2013;41(3):203-206.

Corresponding Author

Dr. Arun Mishra
Postgraduate student,
Department of Pedodontics & Preventive Dentistry,
Teerthanker Mahaveer Dental College and Research
Centre, Moradabad, Uttar Pradesh.
Email- arundr22@gmail.com