

# HORIZONTAL RIDGE AUGMENTATION – AN OVERVIEW

George N,<sup>1</sup> Seema G,<sup>2</sup> Aswathy S,<sup>3</sup>

1. Post Graduate Student, Department of Periodontics, Sri Sankara Dental College, Thrivanthapuram, Kerala.

2. Professor & Head, Department of Periodontics, Sri Sankara Dental College, Thrivanthapuram, Kerala.

3. Post Graduate Student, Department of Periodontics, Sri Sankara Dental College, Thrivanthapuram, Kerala.

## Abstract

Rehabilitation by means of osseointegrated implants represents a highly predictable and widespread therapy. This necessitates sufficient bone quantity as well as bone quality, which may be compromised due to localized ridge defects. Thus the resulting three-dimensional bone morphology may not permit favourable implant positioning. Among the classes of ridge defects, horizontal defects are the ones most frequently encountered posing limitation for successful implant placement. As such, when implant-supported restorations are planned for tooth replacement, it is a challenge to regenerate adequate ridge width to house the dental implants which ensure biomechanics and long term esthetic outcome. Surgical techniques for augmentation involve bone grafting options & non-bone grafting options with ever evolving alternatives. Despite a relevant number of publications reporting favourable results with these different surgical procedures, considerable controversy still exists as far as the choice of the most reliable technique is concerned. In this review, an attempt is made to provide an insight on decision making for more predictable horizontal ridge augmentation with consistent treatment outcomes based on three dimensional bucco-lingual ridge dimensions.

**Key words:** – Guided Bone Regeneration, Onlay Block Grafts, Ridge Augmentation.

## Introduction

Restorations supported by means of dental implants are currently a highly predictable treatment modality for the rehabilitation of partial and complete edentulism.<sup>1</sup> Advantages of oral implant treatment over conventional non-surgical prosthetic rehabilitation has added to its wide acceptance.

Alveolar ridge, as a part of the periodontium, plays an integral role in the maintenance of both the natural dentition and dental implants. An adequate volume of bone at the site of implant placement is a necessity to ensure favourable biomechanics and long term esthetic outcome.

As reviewed from clinical situations, the minimum dimensions in the maxilla to insert a dental implant are an alveolar ridge width of 5 mm and a bone height of 10 mm.<sup>2</sup> Localized or generalized bone defects of the alveolar ridge can ensue, due to atrophy, prolonged edentulism, congenital anomalies, periodontal disease, infection and post-traumatic causes. These causes in turn may make it impossible to meet the minimum dimensions for implants to be placed.<sup>3</sup>

To regain lost bone tissue in height and width, ridge augmentation is employed. Surgical techniques for augmentation involve bone grafting options & non-bone grafting options with ever evolving alternatives. From the systematic reviews, the general consensus is that horizontal ridge augmentation is highly predictable, with good resultant implant survival rates when compared to vertical ridge augmentation.<sup>4</sup>

### An overview of ridge defects

The classification of ridge defects mentioned is intended as a guideline for choosing the best techniques and materials for ridge augmentation at implant sites (Figure 1).<sup>5</sup>

Class I: Extraction socket

Classes II & III: Dehiscence defects

Class IV: Horizontal defects

Class V: Vertical defects

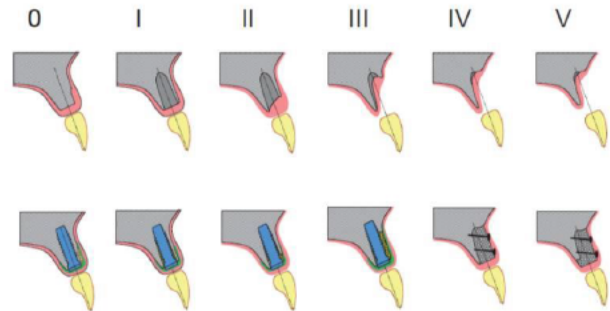


Figure 1: - Schematic drawing depicting the defect classification with classes 0–V<sup>5</sup>

### Horizontal ridge augmentation

A major limitation for successful implant placement is the problem posed by inadequate alveolar ridge width. Ideally a ridge width of 5 to 6mm is needed for placement of a regular 4mm implant.<sup>6</sup> These dimensions are based on an implant with a diameter of 4mm and should be used as a guide and not as an absolute term. Interestingly, horizontal bone defects are the ones most frequently encountered also. They include dehiscence's and fenestrations which occur at a faster rate and to a greater extent than vertical defects.<sup>7</sup> Common techniques introduced for horizontal ridge augmentation are Guided Bone Regeneration (GBR), Ridge splitting and Expansion, and Onlay Block grafts (OBG) of either autogenic or allogenic origin.<sup>7</sup> The treatment of these types of defects has been shown to be highly successful in numerous studies.<sup>5</sup>

As it is known, primary implant stability is a crucial element to the success of implant therapy. The quality and quantity of soft tissue present in the anticipated implant site is also important, since keratinized, attached mucosa favours better functional and aesthetic results for implant restorations. The success of these techniques therefore depends on their ability to work within the buccal bony housing with prudent soft tissue management.<sup>8</sup>

Three dimensional buccolingual bone dimensions have thrown light into the decision making process for horizontal ridge augmentation along with other factors such as the tissue thickness, primary implant stability, and the availability of autogenous bone. In order to extrapolate its application to clinical settings, ridge augmentation methods can be discussed in divisions based on ridge width. (Figure 2)

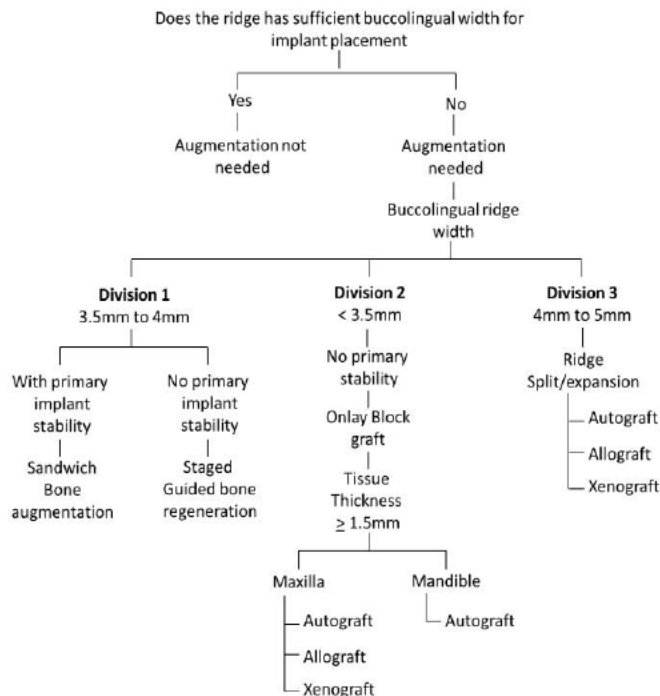


Figure 2: - Decision tree for predictable horizontal ridge augmentation in divisions<sup>7</sup>

#### Division 1(a): Ridge width of 3.5mm to 4mm with primary implant stability

A ridge width of 3.5mm to 4mm normally can present as implant dehiscence defects without hampering primary implant stability. In such cases, ridge augmentation can be applied along with simultaneous implant placement using absorbable barrier membranes by **Sandwich Bone Augmentation (SBA)** technique since it combines the advantages of properties imparted by unique blend of biomaterials to achieve bone regeneration.<sup>9</sup> In this technique, a layer of autogenous bone chips or fast resorbing particulate cancellous allograft are applied onto the exposed implant threads.<sup>10</sup> A second layer of slow resorbing particulate cortical allograft is placed above before an absorbable membrane is used to cover the site thus prolonging space maintenance for bone regeneration to occur. Preliminary studies have shown that the SBA technique is predictable and reliable in achieving bone regeneration with implant placement.<sup>11</sup> The SBA technique is designed to follow the PASS principle (i.e. achieving Primary wound closure, promoting Angiogenesis, maintaining Space for regeneration and obtaining primary implant, and blood clot Stability) in an attempt to achieve optimal bone regeneration.<sup>12</sup>

#### Division 1(b): Ridge width of 3.5mm to 4mm without primary implant stability

In situations where primary implant stability cannot be achieved in a residual ridge  $\geq 3.5$  mm wide, **Guided Bone Regeneration(GBR)** approach can be advocated. GBR works on the principle of compartmentalization, allowing osteoblasts to populate the wound site before epithelial and connective tissue cells, thus regenerating bone. Autogenous bone grafts either in blocks or in particulate form are firmly secured onto the ridge and a barrier membrane is placed. After attaining primary closure, the wound site is left to heal for 4 to 6 months before implant placement.<sup>7</sup> With non-resorbable barrier membranes along with tenting screws, promising outcomes have been achieved with the majority of bone replacement grafts.<sup>13-16</sup> An animal study demonstrated that implant osseointegration can be successfully achieved after GBR using expanded polytetrafluoroethylene membranes regardless of the types of osseous grafts used.<sup>15</sup> In a systematic review, GBR showed an implant survival rate of  $95.8\% \pm 5.3\%$  in  $56.5 \pm 25.5$  months.<sup>17</sup> Others found that implant survival rates were  $95.5\%$  for GBR while ridge augmentation success rates were 60% to 100%.<sup>18</sup>

#### Division 2: Ridge width below 3.5mm

For decreased ridge width even below 3.5mm, horizontal ridge augmentation can be performed with the use of **Onlay Block Grafts (OBG)**. For OBG, allogenic and xenogenic bone blocks as well as chin or ramus autografts have been used.<sup>19</sup> The crucial element to success in this technique is the elimination of graft mobility and dead space between the graft and host bone.<sup>7</sup> Cortico cancellous block grafts are preferred here because of the added advantage of enhanced revascularization provided by the cancellous portion, along with mechanical support and rigidity provided by the cortical portion.<sup>20</sup>

Augmentation with an autograft leads to faster revascularization and graft incorporation which makes autografts the best choice in case of mandible with type 1 or 2 bone. In contrast, the maxilla has typically type 3 or 4 bone, with more cancellous nature and high vascularity which makes augmentation with an allograft or alloplast to work as well.<sup>21</sup> This biologic consideration is supported by the fact that greater graft resorption has been reported in the patients treated with allograft block grafts compared to autologous block grafts with failure rates significantly higher in mandible.<sup>22</sup> In addition to the surface area of the vascularized defect bony walls, degree of regeneration directly correlates with the adequacy of soft tissue cover also. A minimum soft tissue thickness of 1.5 mm is therefore considered to provide additional protection and coverage to the augmented bone site.<sup>23</sup> Flap advancement is found easier in the maxilla as compared to the mandible in order to obtain primary wound closure.<sup>11</sup>

Thus, it is suggested that block autografts can be effective in both jaws, whereas block allografts may be more predictable for the maxilla. Block xenografts may be a



feasible option, but the efficacy remains unknown.<sup>24,25</sup> Studies have demonstrated that onlay grafts are highly predictable in ridge augmentation procedures with very high ridge augmentation success rates of 92% to 100% and high implant survival rates of about 90.4%.<sup>3</sup>

### Division 3: Ridge width of 4mm to 5mm

Originally proposed by Summers, **Ridge Splitting/Expansion** may be a wisely opted when residual ridge width is 4 to 5 mm with expectable remaining cancellous bone between cortical plates.<sup>7</sup> Ridge splitting and ridge expansion osteotomies use the ability of trabecular bone to get compressed to create space for the implant by osteocondensation. This technique in turn exposes cancellous bone and marrow providing enhanced revascularization and healing. Monocortical or corticocancellous autogenous or allogeneous block grafts can then be secured to the ridge to increase its width for implant placement.<sup>26</sup> Osteocondensation is preferably best undertaken in type 3 or 4 bone, common to maxilla because it is more pliable. This technique is considered to be advantageous in that a regular implant can be placed with primary stability without creating donor site or incurring additional expenses of commercial bone grafts.<sup>7</sup> Evidence from comparative studies are all the most limited.<sup>27</sup> Ridge splitting in combination with different particulate graft has shown promising results in most studies and reported with implant survival rates of 91% to 97.3% and ridge augmentation success rates of 98% to 100%.<sup>3,28,29</sup>

### Conclusion

Dental implantology has evolved to a mature evidence based discipline and is currently a valuable treatment modality in the prosthetic treatment of edentulous patients. In implant therapy, successful treatment outcome demands stability of the implant or graft material. For the same reason, augmentative bone surgery has frequently been a prerequisite of implant placement today with wide range of options that has added to clinician's dilemma. The proposed guideline amplifies the benefits of different techniques and grafting options and throws light on categorized individual clinical situations to achieve a more favourable horizontal ridge augmentation.

### References

- Annibaldi S, Bignozzi I, Sammartino G, La Monaca G, Cristalli MP. Horizontal and vertical ridge augmentation in localized alveolar deficient sites: A retrospective case series. *Implant Dent* 2012;21(3):175-85.
- Raghoebar GM, Batenburg RH, Vissink A, Reintsema H. Augmentation of localized defects of the anterior maxillary ridge with autogenous bone before insertion of implants. *J Oral Maxillofac Surg* 1996;54(10):1180-1185.
- Aloy-Prósper A, Peñarrocha-Oltra D, Peñarrocha-Diago M, Peñarrocha-Diago M. The outcome of intraoral onlay block bone grafts on alveolar ridge augmentations: A systematic review. *Med Oral Patol Oral Cir Bucal* 2015;20(2):e251-8.
- Esposito M, Grusovin MG, Felice P, Karatzopoulos G, Worthington HV, Coulthard P. The efficacy of horizontal and vertical bone augmentation procedures for dental implants - a Cochrane systematic review. *Eur J Oral Implantol* 2009;2(3):167-184.
- Lindhe J, Karring T, Lang N, eds. *Clinical periodontology and implant dentistry*. 5th edn. Munksgaard: Blackwell, 2008.
- Buser D, Martin W, Belser UC. Optimizing esthetics for implant restorations in the anterior maxilla: Anatomic and surgical considerations. *Int J Oral Maxillofac Implants* 2004;19(suppl):43-61.
- Fu JH, Wang HL. Horizontal Bone Augmentation: The Decision Tree. *Int J Periodontics Restorative Dent* 2011;31(4):429-436.
- Lioubavina-Hack N, Lang NP, Karring T. Significance of primary stability for osseointegration of dental implants. *Clin Oral Implants Res* 2006;17(3):244-250.
- Wang HL, Misch C, Neiva RF. "Sandwich" bone augmentation technique: Rationale and report of pilot cases. *Int J Periodontics Restorative Dent* 2004;24(3):232-245.
- Lee A, Brown D, Wang HL. Sandwich bone augmentation for predictable horizontal bone augmentation. *Implant Dent* 2009;18(4):282-290.
- Park SH, Lee KW, Oh TJ, Misch CE, Shotwell J, Wang HL. Effect of absorbable membranes on sandwich bone augmentation. *Clin Oral Implants Res* 2008;19(1):32-41.
- Wang HL, Boyapati L. "PASS" principles for predictable bone regeneration. *Implant Dent* 2006;15(1):8-17.
- Pieri F, Corinaldesi G, Fini M, Aldini NN, Giardino R, Marchetti C. Alveolar ridge augmentation with titanium mesh and a combination of autogenous bone and anorganic bovine bone: A 2-year prospective study. *J Periodontol* 2008;79(1):2093-2103.
- Barboza EP, Stutz B, Ferreira VF, Carvalho W. Guided bone regeneration using nonexpanded polytetrafluoroethylene membranes in preparation for dental implant placements — A report of 420 cases. *Implant Dent* 2010;19(1):2-7.
- Fiorellini JP, Kim DM, Nakajima Y, Weber HP. Osseointegration of titanium implants following guided bone regeneration using expanded polytetrafluoroethylene membrane and various bone fillers. *Int J Periodontics Restorative Dent* 2007;27(3):287-294.
- Proussaefs P, Lozada J, Kleinman A, Rohrer MD, McMillan PJ. The use of titanium mesh in conjunction with autogenous bone graft and inorganic bovine bone mineral (Bio-oss) for localized alveolar ridge augmentation: A human study. *Int J Periodontics Restorative Dent* 2003;23(2):185-195.
- Fiorellini JP, Nevins ML. Localized ridge augmentation/preservation. A systematic review. *Ann Periodontol* 2003;8(1):321-327.

18. Chiapasco M, Zaniboni M, Boisco M. Augmentation procedures for the rehabilitation of deficient edentulous ridges with oral implants. *Clin Oral Implants Res* 2006;17(suppl 2):136–159.
19. Jensen SS, Terheyden H. Bone augmentation procedures in localized defects in the alveolar ridge: clinical results with different bone grafts and bone-substitute materials. *Int J Oral Maxillofac Implants* 2009;24 Suppl 2:218–236.
20. Rosenberg E, Rose LF. Biologic and clinical considerations for autografts and allografts in periodontal regeneration therapy. *Dent Clin North Am* 1998;42(3):467–490.
21. Spin-Neto R, Stavropoulos A, Dias Pereira LA, Marcantonio E Jr., Wenzel A. Fate of autologous and fresh-frozen allogeneic block bone grafts used for ridge augmentation. A CBCT-based analysis. *Clin Oral Implants Res* 2013;24(2):167-173.
22. Chaushu G, Mardinger O, Peleg M, Ghelfan O, Nissan J. Analysis of complications following augmentation with cancellous block allografts. *J Periodontol* 2010;81(12):1759-1764.
23. Hiatt WH, Schallhorn RG. Intraoral transplants of cancellous bone and marrow in periodontal lesions. *J Periodontol* 1973;44(4): 194–208.
24. Al-Nawas B, Schiegnitz E. Augmentation procedures using bone substitute materials or autogenous bone – a systematic review and meta-analysis. *Eur J Oral Implantol* 2014;7(Suppl 2):S219–S234.
25. Esposito M, Grusovin MG, Coulthard P, Worthington HV. The efficacy of various bone augmentation procedures for dental implants: a Cochrane systematic review of randomized controlled clinical trials. *Int J Oral Maxillofac Implants* 2006;2(5):696–710.
26. Chiapasco M, Casentini P, Zaniboni M. Bone augmentation procedures in implant dentistry. *Int J Oral Maxillofac Implants* 2009;24(Suppl): 237-259.
27. Hsu Y, Wang H. How to select replacement grafts for various periodontal and implant indications. *Clinical Adv Periodont* 2013;3(3):167-179.
28. Coatoam GW and Mariotti A. The segmental ridge split procedure. *J Periodontol* 2003;74(5):754-770.
29. Sethi A, Kaus T. Maxillary ridge expansion with simultaneous implant placement: 5-year results of an ongoing clinical study. *Int J Oral Maxillofac Implants* 2000;15(4):491-499.

**Corresponding Author**

Dr.Neenu George  
Post Graduate Student  
Department of Periodontics,  
Sri Sankara Dental College,  
Varkala, Thiruvananthapuram, Kerala, INDIA.  
E mail Id: - mariakutty@gmail.com