

# A CROSS-SECTIONAL STUDY OF THE FACTORS PREDICTING ROOT RESORPTION IN THE TEETH ADJACENT TO AN IMPACTED MAXILLARY CANINE

Tofangchiha M,<sup>1</sup> Padisar P,<sup>2</sup> Rayati F,<sup>3</sup> Ramezani M,<sup>4</sup> Hadad Z<sup>5</sup>

1. Associate Professor, Department of Oral and Maxillofacial Radiology, Dental Caries Prevention Research Center, Qazvin University of Medical Sciences, Qazvin, IRAN.
2. Associate Professor, Department of Orthodontics, Dental Caries Prevention Research Center, Qazvin University of Medical Sciences, Qazvin, IRAN.
3. Assistant Professor, Department of Oral and Maxillofacial Surgery, School of Dentistry, Qazvin University of Medical Sciences, Qazvin, IRAN.
4. Post-graduate Student of Endodontics, Student Research Committee, School of Dentistry, Qazvin University of Medical Sciences, Qazvin, IRAN.
5. General Dentist, Qazvin, IRAN.

## ABSTRACT

**Aim:** The permanent maxillary canine is the most frequently impacted tooth after third molars. An accurate diagnosis of the position of an impacted canine and the potential root resorption in the adjacent teeth may influence orthosurgery treatment options. The main objective of this study was to develop a model for predicting root resorption in the teeth adjacent to an impacted maxillary canine.

**Materials & Method** An evaluation was made of 57 cone beam computed tomography (CBCT) images depicting 67 impacted canines. We assessed the factors pertinent to the impacted maxillary canine that contribute to root resorption in the adjacent teeth by CBCT images and panoramic images reconstructed by CBCT.

**Results:** Of the 14 teeth with enlarged follicle, 13 exhibited root resorption; therefore a significant correlation was found ( $p < 0.05$ ). However, there was no statistically significant relationship between other variables and root resorption ( $p > 0.05$ ). Regression analysis revealed that follicle size is a key factor in predicting root resorption in a new case.

**Conclusion:** The results revealed that impacted canines with enlarged follicle are more likely to cause root resorption in the adjacent teeth.

**Key words:** Canine tooth, Cone-Beam Computed Tomography, Dental follicle, Impacted tooth, Root resorption.

## Introduction

Maxillary canines have a significant role in esthetic and chewing functions; therefore, any disruption in their eruption can lead to complications in the dental arch and the adjacent teeth, and this would require special care and attention.<sup>1</sup> The definition of impaction is “lack of tooth eruption in its proper location in the dental arch in the normal physiological range and time”.<sup>2</sup> The permanent maxillary canine is the most frequently impacted tooth after the third molar, with a prevalence rate of approximately 1-3%.<sup>3-6</sup> Accurately determining the location of an impacted canine and diagnosing its potential root resorption may influence the orthosurgical treatment options.<sup>7,8</sup>

Two-dimensional radiographic imaging is the most common primary technique for determining canine location. However, technical errors that are characteristic of two-dimensional imaging lead to an unreliable diagnostic validity for determining the position of an impacted canine and the adjacent structures.<sup>1</sup> Correct treatment planning requires the exact diagnosis and localization of the impacted canine in relation to the structures adjacent to it, particularly root resorption and changes in root morphology.

This is normally achieved via three-dimensional (3D) imaging. 3D computed tomography (CT) scanning overcomes the problems associated with conventional radiography and is superior in localizing the impacted canine, especially in assessing the root resorption of the adjacent teeth.<sup>1,9,10</sup>

Regarding the increased cost and radiation exposure concomitant with cone beam computed tomography (CBCT) compared to panoramic radiography and considering limited access to CBCT, the present study

evaluated 3D CBCT and panoramic images to offer a new approach to predicting the root resorption of the teeth adjacent to the impacted canine and requesting an appropriate radiographic image.

## Materials and Methods

This cross-sectional study was performed on CBCT images collected from the archives of a private oral and maxillofacial radiology center; therefore, there was no information about gender and age. The radiographic images of 57 patients who visited the mentioned center for having an impacted canine imaged and who also met the inclusion criteria were studied by census method between January 2014 and December 2016. The inclusion criteria were no history of orthodontic treatment; absence of dentofacial deformities, facial trauma, and pathological lesions; not having cleft lip/palate; and having no large metal restoration in the region.

The samples were inspected for the purpose of imaging an impacted canine. The collected images were taken using Planmeca ProMax® radiographic unit (Planmeca Oy, Helsinki, Finland). CBCT images were studied separately by two observers: an oral and maxillofacial radiologist with ten years of working experience and a trained last-year dental undergraduate. The condition of an impacted canine and the related factors were recorded in a design chart. The images were analyzed using Planmeca Romexis® software version 2.9.2 r. The observers used the panoramic images reconstructed via CBCT and other cross sections for recording the data.

## Parameters that were studied:

1. The unilateral or bilateral impacted canine and its localization side

2. The sagittal localization of the permanent maxillary canine: location in relation to the adjacent teeth labially, palatally, or in the middle of the arch (i.e., mid alveolus)
3. The vertical localization of the permanent canine:<sup>11</sup> location of the tip of the cusp of the impacted canine in relation to the adjacent lateral incisor: coronal, cervical third of the tooth, middle third of the tooth, apical third of the tooth, or below the root tip
4. The horizontal distance of the permanent canine from the midline in the coronal plane by measuring the horizontal distance in mm between the canine cusp tip and the jaw midline.<sup>3</sup>
5. Canine angulation in the coronal plane; i.e., the angle formed between the long axis of the impacted canine and the skeletal midline.<sup>3</sup> [Figure 1]

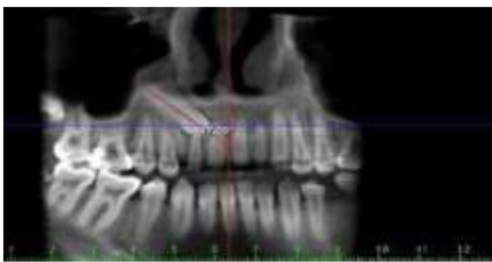

Figure 1. Canine angulation in relation to the midline.

6. The follicle size of the impacted canine obtained by measuring the distance in millimetres between the widest areas of the follicle perpendicular to the crown of the impacted canine. Distances greater than 3 mm were considered an enlarged follicle.<sup>7</sup> [Figure 2]

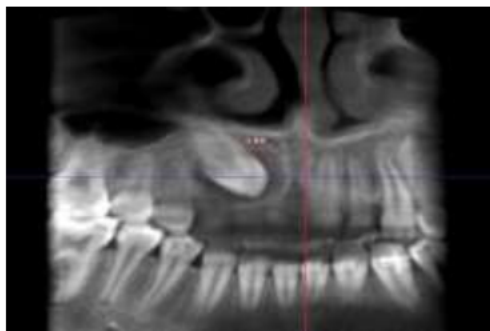


Figure 2. Enlarged follicle.

7. The development of the root of the permanent canine, classified using the method developed by Lai *et al.*<sup>11</sup> are as following: complete root development with closed apex, almost complete root development with open apex,  $\frac{3}{4}$  of the root length developed, or  $\frac{1}{2}$  of the root length developed.
8. The existence and morphology of the lateral tooth.
9. Root divergence.
10. Root resorption according to Ericson *et al.* classification:<sup>7</sup> no resorption (intact root surfaces although the cementum layer may be disrupted), mild resorption (resorption up to half of the dentin thickness), moderate resorption (resorption of half or

more than half of the dentin-pulp thickness), severe resorption (pulp exposure by the resorption). [Figure 3]

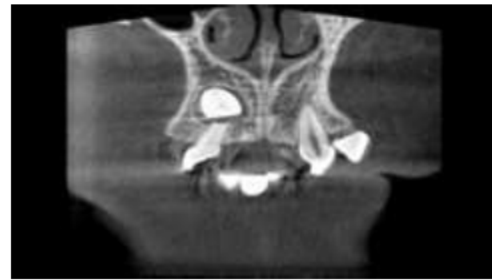

Figure 3. Severe root resorption in a lateral incisor.

**Statistical analysis**

Quantitative traits were analyzed using the independent-samples t-test, and qualitative traits via the chi-squared test and Fisher’s exact test. Since one of the objectives of the study was determining a model for predicting resorption, logistic regression was used to evaluate the concurrent effect of multiple traits on the probability of resorption, and the odds ratio of the contributing factors was determined. Statistical analysis was performed on SPSS 20 (IBM Corporation, NY, USA, 2011). A p value level of 0.05 or less was regarded as significant.

**Results**

A total of 57 CBCT images and panoramic images simulated by CBCT were evaluated. Ten of the CBCT images showed bilateral impacted canines; therefore, 67 impacted canines were evaluated.

Of the 67 impacted canines, 49.3% were on the right side and 50.7% on the left. Furthermore, unilateral impaction was present in 69.7% of the samples, while 30.7% of the cases exhibited bilateral impaction.

The labiopalatal position of the impacted canine revealed that palatal position had the highest frequency (80.6%), and the middle position had the lowest (4.5%). Moreover, the vertical localization of the impacted canine in relation to ipsilateral incisor showed a high frequency in the middle third of the adjacent teeth (44.8%), followed by the apical third (29.9%), the cervical third (17.9%), the supraapical (6%), and the coronal position (1.5%).

It was additionally found that the horizontal distance of the impacted canine from the midline was between 0.6 and 14.08 mm, and its angulation in relation to the midline was 14.84° to 87.19°.

Another observation was that in 14 (20.9%) of the cases, follicle size was greater than 3 mm. [Table 1]

Follicle size	Frequency	Percentage
Small	53	79.1
Enlarged	14	20.9
Total	67	100

Table 1. Frequency distribution of the impacted canines regarding follicle size.



Regarding the root development of the impacted canine, most of the cases had closed apex (89.56%), and the frequency of completed root with an open apex was 7.46%, while the development of ¾ of the root length was observed in 2.98% of the cases.

In 85.1% of the cases, the lateral incisor had normal morphology, but 11.9% of the cases had a peg-shaped lateral incisor, and 3% had missing lateral incisors. Also, the root divergence of the neighbouring teeth was non-existent in 70.1% of the cases; however, in 29.9% of the cases, the impacted canine caused root divergence.

Of the 67 impacted canines under study, 44 (65.7%) had caused pathological root resorption in the adjacent teeth (Table 2). Of the 44 cases with root resorption in the neighbouring teeth, 33 had caused root resorption in one tooth, 9 cases caused root resorption in two teeth, and finally in one case there was root resorption in three teeth. This means that 54 of the teeth adjacent to the impacted canine exhibited root resorption. Of the 54 teeth having resorbed root, 40.74% had mild resorption, 29.62% exhibited moderate resorption, and 29.62% showed severe resorption. Moreover, 57.4% of the resorption in the teeth adjacent to the impacted canine was localized in the apical third of the tooth, 40.75% occurred in the middle third and 1.85% in the cervical third.

Resorption	Frequency	Percentage
Yes	44	65.7
No	23	34.3
Total	67	100

Table 2. Frequency distribution of resorption in the teeth adjacent to the impacted canine.

Of the 14 teeth with enlarged follicle mentioned above, 13 exhibited resorption (Table 3). Statistical analysis revealed a significant relationship between an enlarged follicle and root resorption (p = 0.024).

Resorption	Yes		No	
	Frequency	Percentage	Frequency	Percentage
Small	31	70.5	22	95.7
Enlarged	13	29.5	1	4.3
Total	44	100.0	23	100.0

Table 3. Frequency distribution of resorption regarding the follicle size of the impacted canine.

The relationship between the following parameters and root resorption was insignificant: the localization side of the impacted canine (p = 0.4000), buccopalatal localization (p = 0.210), vertical localization (p = 0.814), distance of the impacted permanent canine from the midline (p = 0.830), angulation (p = 0.879), root development (p = 0.568), lateral tooth morphology (p = 0.132) and root divergence of the adjacent teeth (p = 0.165).

The data from logistic regression revealed that of the variables at issue, follicle size proved an important factor in predicting root resorption (Table 4). To evaluate the

probability of resorption in a new sample, follicle size was used for presenting the following equation:

$$Y = (-3.15 \times q2) + 0.655$$

	B	SE	Wald	df	Sig.	exp(B)	For exp(B)	
							Lower	Upper
Follicle size	-3.15	1.436	4.812	1	0.028	0.043	0.003	0.715
Constant	0.655	5.607	0.014	1	0.907	1.925		

Table 4. The data from logistic regression.

Where Y is the presence or absence of resorption, and q2 indicates follicle size, which can be small or enlarged. It follows that the probability of resorption increases with an increase in follicle size.

### Discussion

Nute<sup>12</sup> observed that the reported incidence of resorption depends on the imaging technique used. This can be considered a possible cause of the wide-ranging (6-67%) incidence of root resorption reported in the existing literature.<sup>13-15</sup> In the present study, the frequency of root resorption in the teeth adjacent to the impacted canine was 65.7%. Kim *et al.*<sup>16</sup> reported the occurrence of root resorption to be 49.5% in their study, while Cernochova *et al.*<sup>17</sup> reported a lower percentage of 17.7% for root resorption detected by CT examinations. This low incidence can be due to the fact that the authors only reported severe root resorption (As for the present study, severe root resorption was observed in 29.62% of the cases.).

Concerning the tooth inflicted with resorption, there was a general agreement between our findings and the studies existing in the literature.<sup>1,8,11,18</sup> The root of maxillary lateral incisor is the most likely region for resorption caused by the impacted canine, and it seems that resorption in the root of premolars is rare but possible.<sup>8</sup>

Furthermore, in the present study, most of the root resorption occurred in the middle third of the tooth followed by the apical third and the cervical third. No significant difference was found between the middle third and apical third regions (p > 0.05). The probability of resorption in the middle third and the apical third of the roots adjacent to the impacted canine is higher than the cervical third. Since the germ of the canine is situated deeply in the maxilla, it is acceptable to consider this a cause of more incisor root resorption in the apical third and middle third regions.<sup>15</sup>

Ericson and Kuroi<sup>13</sup> and Cuminetti *et al.*<sup>19</sup> found that the majority of resorption occurred in the middle third. In contrast, Guarnieri *et al.*<sup>20</sup> and Lai *et al.*<sup>11</sup> had a similar finding; Lai *et al.*<sup>11</sup> reported that most (50%) of the resorption took place in the apical third, followed by 45.84% in the middle third, and lastly 4.16% in the cervical third. Guarnieri *et al.*<sup>20</sup> found that 52% of the resorption was in the apical third, while 48% occurred in the middle third.

As for the severity of resorption, in the present study, mild resorption was observed in 40.75% of the cases, 29.62% of the teeth had moderate resorption, and 29.62% showed severe resorption.

In the study carried out by Al Ansari *et al.*<sup>1</sup> of the 18 teeth with resorption, 94.44% had mild resorption, and 5.55% exhibited moderate resorption. Lai *et al.*<sup>11</sup> examined 48 teeth with resorption and observed mild resorption in 47.91% of the cases and moderate resorption in 12.5% of the cases. In a study by Dogramaci *et al.*<sup>21</sup> 50% of the cases with resorption exhibited mild resorption.

Our study did not find a significant role for the left and right position of the canines, supporting the results reported by Kim *et al.*<sup>16</sup> Moreover, the relationship between unilateral/bilateral permanent canine impaction and root resorption did not reach significance.

Another finding of the present study was the insignificant relationship between the labiopalatal position of the impacted canine and root resorption. However, Lai *et al.*<sup>11</sup> argued that the labiopalatal position of the impacted canine may have an effect on root resorption. Ucar *et al.*<sup>22</sup> had the similar point of view. In a study performed by Kim *et al.*<sup>16</sup> the labiopalatal position of the impacted canine was significantly related to root resorption. Our study confirms Lai *et al.*<sup>11</sup> findings that a labially positioned impacted canine displays more tendency toward root resorption than a palatally positioned canine. Guarnieri *et al.*<sup>20</sup> found that the eruptive path of the canine may have effect on causing distopalatal resorption more common than purely palatal. They reported that 74% of resorption was observed on the palatal side of the adjacent root, in a labially positioned impacted canine.

The differences between our findings and those of Kim *et al.*<sup>16</sup> mentioned above could be attributed to the large size of their sample (186 canines); more importantly, 140 of their impacted canines they studied were labially located, a fact which leads to a stronger tendency toward resorption.

Furthermore, there was no significant association in our study between the vertical positioning of the impacted canines and root resorption. In a similar study by Lai *et al.*<sup>11</sup> it was found that the risk of root resorption decreases when the canine cusp tip is located coronally or supraapically. However, it is to be noted that this agreement between the two studies could not be of much significance due to the small number of the canines in coronal and supraapical positions in the present study.

We observed that root resorption is not significantly related to the distance and angulation of the impacted canine in relation to the midline. Linear and angular measurements are implemented frequently in radiographic evaluations. The use of these measurements in studies on impacted canine allows relative prediction of canine eruption.<sup>11</sup> In line with our study, Kim *et al.*<sup>16</sup> and Ucar *et al.*<sup>22</sup> reported no statistical connection between the angulation of the impacted canine and root resorption.

In this study, a statistically significant relationship was observed between enlarged canine follicle and root resorption ( $p = 0.024$ ). More specifically, root resorption occurred in 92.85% of the enlarged impacted canines, while this figure was 58.94% for the small-sized canines.

In some studies, no association has been reported between enlarged canine follicle and resorption.<sup>8, 13, 19, 23</sup> Ericson and Kuroi<sup>13</sup> compared the resorption group with a control group having ectopically positioned canines that did not cause root resorption. The result was that the incidence of follicular enlargement was not significantly different in the two groups. In addition, Lai *et al.*<sup>11</sup> pointed out that although there was no statistically significant correlation between follicle size and the occurrence of root resorption, enlarged follicles showed more resorption in comparison with small-sized follicles.

Dagsuyu *et al.*<sup>23</sup> believed that we can not predict the presence of resorptive features of maxillary impacted canines to adjacent lateral incisors by observing the follicle width of ectopically erupted canines. The active eruption pressure and cellular activities of environmental tissues in the eruption process may have effect on the resorption events of maxillary impacted canines. Neighboring anatomical structures near the follicle can have an influence on the follicle's size and shape. But as they have mentioned, further research is needed to compare the follicle width with other variables. They concluded that larger dental follicles of maxillary impacted canines were more common in mild resorption cases in adjacent laterals. We also found that the degree of root development is not significantly associated with root resorption. Lai *et al.*<sup>11</sup> and Mah *et al.*<sup>15</sup> reported that there is a higher risk of root resorption when the root of the impacted canine is fully developed and the apex is closed. As for the current study, the samples were not equally distributed in terms of root development; hence, our findings in this regard may not be considered statistically reliable. This observation can also applied to the study by Lai *et al.*<sup>11</sup> in that 82 of their 134 samples had closed apex, while only three had roots with half development. In our study, no significant connection existed between the morphology of permanent lateral incisors and root resorption. Brin *et al.*<sup>24</sup> hypothesized that the lateral incisor with a normal-sized crown obstructs the eruption path of the impacted canine, and this damages the root. In contrast, in cases where lateral incisors are peg-shaped and/or the width of their mesiodistal crown is small, the impacted tooth more easily bypasses roots and thus leaves them intact. In the present study, given the small number of the cases with peg-shaped or missing lateral incisors, the concordance between our findings and those of Brin *et al.*<sup>24</sup> may not be attached much significance.

## Conclusion

The main objective of the present study was to assess the extent to which the variables pertinent to the impacted canine are associated with root resorption in the adjacent teeth. The follicle size of the impacted canine was found to



be the most important factor in predicting root resorption. In the cases where follicle enlargement is identified (particularly, greater than 3), CBCT should be requested.

## References

1. Al-Ansari NB, Ghaib NH, Al-Naimi SH. Diagnosis and localization of the maxillary impacted canines by using dental multi-slice computed tomography 3D view and reconstructed panoramic 2D view. *J Bagh College Dentistry* 2014;26(1):159-165.
2. Maverna R, Gracco A. Different diagnostic tools for the localization of impacted maxillary canines: clinical considerations. *Prog Orthod* 2007;8(1):28-44.
3. Walker L, Enciso R, Mah J. Three-dimensional localization of maxillary canines with cone-beam computed tomography. *Am J Orthod Dentofacial Orthop* 2005;128(4):418-423.
4. Grover PS, Lorton L. The incidence of unerupted permanent teeth and related clinical cases. *Oral Surg Oral Med Oral Pathol* 1985;59(4):420-425.
5. Preda L, La Fianza A, Di Maggio EM, Dore R, Schifino MR, Campani R *et al*. The use of spiral computed tomography in the localization of impacted maxillary canines. *Dentomaxillofacial Radiol* 1997;26(4):236-241.
6. Ericson S, Kurol J. Incisor resorption caused by maxillary cuspids. A radiographic study. *Angle Orthod* 1987;57(4):332-346.
7. Ericson S, Bjerklin K, Falahat B. Does the canine dental follicle cause resorption of permanent incisor roots? A computed tomographic study of erupting maxillary canines. *Angle Orthod* 2002;72(2):95-104.
8. Alqerban A, Jacobs R, Lambrechts P, Loozen G, Willems G. Root resorption of the maxillary lateral incisor caused by impacted canine: a literature review. *Clin Oral Investig* 2009;13(3):247-255.
9. Heimisdottir K, Bosshardt D, Ruf S. Can the severity of root resorption be accurately judged by means of radiographs? A case report with histology. *Am J Orthod Dentofacial Orthop* 2005;128(1):106-109.
10. Yu JN, Gu YG, Zhao CY, Liu K, Mo SC, Li H *et al*. Three-dimensional localization and assessment of maxillary palatal impacted canines with cone-beam computed tomography. *Shanghai Kou Qiang Yi Xue* 2015;24(1):65-70.
11. Lai CS, Bornstein MM, Mock L, Heuberger BM, Dietrich T, Katsaros C. Impacted maxillary canines and root resorptions of neighbouring teeth: a radiographic analysis using cone-beam computed tomography. *Eur J Orthod* 2013;35(4):529-538.
12. Nute SJ. Severe incisor resorption by impacted maxillary canines: case report and literature review. *Int J Paediatr Dent* 2004;14(6):451-454.
13. Ericson S, Kurol J. Radiographic examination of ectopically erupting maxillary canines. *Am J Orthod Dentofacial Orthop* 1987;91(6):483-492.
14. Ericson S, Kurol J. Incisor root resorptions due to ectopic maxillary canines imaged by computerized tomography: a comparative study in extracted teeth. *Angle Orthod* 2000;70(4):276-283.
15. Mah JK, Alexandroni S. Cone-beam computed tomography in the management of impacted canines. *Seminars in Orthodontics* 2010;16(3):199-204.
16. Kim Y, Hyun HK, Jang KT. The position of maxillary canine impactions and the influenced factors to adjacent root resorption in the Korean population. *Eur J Orthod* 2012;34(3):302-306.
17. Cernochova P, Krupa P, Izakovicova-Holla L. Root resorption associated with ectopically erupting maxillary permanent canines: a computed tomography study. *Eur J Orthod* 2011;33(5):483-491.
18. Oana L, Zetu I, Petcu A, Nemtoi A, Dragan E, Haba D. The essential role of CBCT to diagnosis the localization of impacted maxillary canine and to detect the austeriety of the adjacent root resorption in the Romanian population. *Rev Med Chir Sco Med Nat Iasi* 2013;117(1):212-216.
19. Cuminetti F, Boutin F, Frapier L. Predictive factors for resorption of teeth adjacent to impacted maxillary canines. *Int Orthod* 2017;15(1):54-68.
20. Guarnieri R, Cavallini C, Vernucci R, Vichi M, Leonardi R, Barbato E. Impacted maxillary canines and root resorption of adjacent teeth: A retrospective observational study. *Med Oral Patol Oral Cir Bucal* 2016;21(6):e743-e750.
21. Doğramaci EJ, Sherriff M, Rossi-Fedele G, McDonald F. Location and severity of root resorption related to impacted maxillary canines: a cone beam computed tomography (CBCT) evaluation. *Aust Orthod J* 2015;31(1):49-58.
22. Ucar FI, Celebi AA, Tan E, Topcuoğlu T, Sekerci AE. Effects of impacted maxillary canines on root resorption of lateral incisors: A cone beam computed tomography study. *J Orofac Orthop* 2017;78(3):233-40
23. Dağsuyu İM, Okşayan R, Kahraman F, Aydın M, Bayrakdar İŞ, Uğurlu M. The Relationship between Dental Follicle Width and Maxillary Impacted Canines' Descriptive and Resorptive Features Using Cone-Beam Computed Tomography. *Biomed Res Int* 2017;2017:2938691.
24. Brin I, Becker A, Zilberman Y. Resorbed lateral incisors adjacent to impacted canines have normal crown size. *Am J Orthod Dentofacial Orthop* 1993;104(1):60-66.

## Corresponding Author

### Dr. Masoumeh Ramezani

Post-graduate Student of Endodontics,  
School of Dentistry,  
Qazvin University of Medical Sciences,  
Qazvin, IRAN.

Email Id: m269\_ramezani@yahoo.com