

THREE-DIMENSIONAL SKELETAL STABILITY IN LE FORT I OSTEOTOMY: A COMPARATIVE COHORT STUDY

Hung Tan Le^{1*}, Khiem Ai Tran², Huyen My Nguyen¹, Lanh Duc Le²

¹Faculty of Odonto-Stomatology, College of Medicine and Pharmacy, Tra Vinh University, Vinh Long Province, Vietnam. letanhung@tvu.edu.vn

²Faculty of Odonto-Stomatology, Hong Bang International University, Ho Chi Minh City, Vietnam.

Received: 03 February 2026; Revised: 14 April 2026; Accepted: 30 June 2026

<https://doi.org/10.51847/M8KwrSoLlv>

ABSTRACT

This study quantitatively evaluates and compares the three-dimensional (3D), 6-degrees-of-freedom (6-DOF) skeletal stability of Le Fort I osteotomies using a minimally invasive 2-plate fixation versus the conventional 4-plate approach. Utilizing a retrospective cohort design, 42 adult patients with severe skeletal Class III malocclusion were analyzed: a 4-plate control group (n=22) and a 2-plate test group (n=20). Spatial changes were measured via voxel-based cone-beam computed tomography (CBCT) superimposition at preoperative, immediate postoperative, 6-month, and 1-year intervals. A 3D semi-automated registration protocol was employed to quantify translational (X, Y, Z axes) and rotational (pitch, roll, yaw) alterations. Results indicated that baseline characteristics and initial surgical displacements were statistically equivalent between cohorts. Longitudinally, from one day to one year postoperatively, both fixation modalities demonstrated robust structural stability. All translational relapses remained below 1.0 mm; specifically, transverse drift (X-axis) was restricted to 0.31 mm in the 4-plate group and 0.37 mm in the 2-plate group. Rotational adaptations were uniformly limited to less than 1.0° across all axes, with no significant intergroup differences identified at the final assessment ($p > 0.561$). In conclusion, reducing rigid internal fixation from four to two plates at the zygomaticomaxillary buttresses provides equivalent 6-DOF spatial stability to the conventional method. This approach offers a reliable, minimally invasive alternative for monobloc Le Fort I osteotomies without increasing the risk of transverse or rotational relapse.

Key words: Le Fort I osteotomy, Rigid internal fixation, Three-dimensional cephalometry, Skeletal stability, Orthognathic surgery, Cone-beam computed tomography.

Introduction

Le Fort I osteotomy remains a cornerstone in orthognathic surgery for the correction of severe midfacial deformities. To counteract masticatory forces and secure the mobilized maxilla during the critical phase of bone healing, rigid internal fixation (RIF) using titanium miniplates is the established clinical standard [1-3]. Conventionally, a 4-plate fixation strategy, involving symmetric placement at the bilateral pyriform apertures and zygomaticomaxillary buttresses, has been universally adopted as the gold standard to prevent postoperative skeletal relapse [2, 4].

Despite its biomechanical reliability, the traditional 4-plate technique requires extensive mucoperiosteal dissection, prolongs surgical time, increases material costs, and elevates the risk of iatrogenic injury to adjacent dental roots and neurovascular structures [1, 5-8]. Consequently, a simplified 2-plate fixation approach, placing hardware solely at the robust zygomatic buttresses, has emerged as a minimally invasive alternative. Preliminary clinical studies and two-dimensional (2D) cephalometric evaluations, such as those by Fujio *et al.* suggest that 2-plate fixation may provide anteroposterior and vertical stability comparable to the 4-plate method [9-12].

However, a critical gap remains in the current evidence base. The vast majority of comparative studies have relied on 2D lateral cephalometry [9, 13], which is inherently limited by magnification errors, anatomical superimposition, and an absolute inability to accurately quantify transverse displacements or complex spatial adaptations [9, 14, 15]. Because transverse stability and rotational shifts (pitch, roll, and yaw) are paramount for maintaining long-term occlusal interdigitation and facial symmetry, a robust three-dimensional (3D) assessment is mandatory. Currently, voxel-based cone-beam computed tomography (CBCT) superimposition is the benchmark for evaluating these 6-degrees-of-freedom (6-DOF) movements. High-quality 3D comparative data addressing the transverse and rotational stability of 2-plate versus 4-plate fixation remains exceedingly sparse [16].

This highlights a pivotal clinical question: Does reducing fixation from 4 to 2 plates compromise the long-term 3D spatial stability of the repositioned maxilla, particularly in the transverse dimension? Therefore, this study aimed to quantitatively evaluate and compare the 6-DOF skeletal stability (translational X, Y, Z axes and rotational alterations) of Le Fort I osteotomies utilizing 2-plate versus 4-plate fixation via voxel-based CBCT superimposition. We hypothesize that 2-plate fixation yields long-term 3D spatial

stability equivalent to the conventional 4-plate approach, without increasing the incidence of transverse or rotational relapse.

Materials and Methods

Study design and patient selection

The retrospective cohort study was conducted in accordance with the Declaration of Helsinki and approved by the Independent Ethics Committee IEC, Tra Vinh University (Ref number 185/GCN.ĐC-HĐĐ); and the IEC of Van Hanh General Hospital (Ref number 01/2025/GCN-HĐĐ). This study enrolled adult patients diagnosed with skeletal Class III malocclusion, specifically characterised by maxillary retrognathia and mandibular prognathism, who underwent a Le Fort I osteotomy combined with a bilateral sagittal split ramus osteotomy (BSSO). The exclusion criteria comprised patients with congenital malformations (such as cleft lip and palate), a history of maxillofacial trauma, or cases where direct contact between the maxillary bone fragments could not be achieved post-osteotomy, preventing baseline stability.

To ensure robust statistical power, a minimum sample size of 20 patients per group was required to detect a clinically significant spatial difference of ≥ 1.0 mm with an 80% statistical power and a significance level (α) of 0.05. The inclusion criteria were: (1) completion of the aforementioned surgical protocol; (2) availability of high-quality Cone-Beam Computed Tomography (CBCT) scans at four specific time points: preoperative (T0), immediate postoperative within 1-4 weeks (T1), 6-month follow-up (T2), and 1-year follow-up (T3); and (3) positive osseous contact between bone fragments, assuring baseline stability. Exclusion criteria comprised patients with cleft lip and palate, craniofacial syndromes, history of maxillofacial trauma, or inadequate CBCT field of view.

Surgical protocol and fixation methods

All surgical procedures were executed by a highly experienced maxillofacial team. The maxilla was approached via a circumvestibular incision, and the Le Fort I osteotomy and down-fracture were performed utilising a reciprocating saw and Rowe forceps. Following mobilisation, an intermediate interocclusal splint was adapted to position the maxilla accurately. Concurrently, the mandible was repositioned via BSSO and fixed using a set of one titanium plate and four screws on each side. Adjunctive genioplasty was performed when clinically indicated. Postoperatively, guiding elastics were applied to maintain the ideal occlusion, and patients were instructed to adhere to a soft, non-chew diet starting 10 days after surgery.

Based on the rigid internal fixation (RIF) strategy, patients were divided into two cohorts:

- Control Group (4-Plate Fixation): The maxilla was

secured using four 0.8-mm-thick L-shaped titanium locking plates placed symmetrically at the bilateral piriform apertures and the zygomaticomaxillary buttresses. Each plate was fixated with five locking screws (1.7 mm in diameter and 4 mm in length).

- Test Group (2-Plate Fixation): Fixation was accomplished exclusively using two identical 0.8-mm-thick L-shaped titanium locking plates and screws placed strictly at the bilateral zygomaticomaxillary buttresses, completely omitting hardware at the piriform apertures.

6-Degrees-of-freedom (6-DOF) spatial assessment

To accurately capture the transverse dimensional changes and complex rotational adaptations, a 3D semi-automated, voxel-based registration protocol was utilised. The DICOM data from T0, T1, T2 and T3 were imported into medical image processing software. To bypass the inaccuracies of manual landmark identification, voxel-based registration (VBR) of the non-operated anterior cranial base (a structurally stable reference structure) was performed to superimpose the T1, T2 and T3 scans onto the T0 spatial matrix.

Following cranial base superimposition, individual maxillary segments were isolated. Transformation matrices were automatically computed to calculate the exact spatial discrepancies between the immediate postoperative position (T1) and the follow-up position (T2, T3). The 6-DOF skeletal stability was quantitatively evaluated using a Cartesian coordinate system with the following strictly defined axes:

Translational Displacements (mm) (Figure 1):

- ΔX -axis (Transverse): Left-right movement (Positive values indicate translation to the left).
- ΔY -axis (Vertical): Superior-inferior movement (Positive values indicate inferior displacement / downward).
- ΔZ -axis (Sagittal): Anteroposterior movement (Positive values indicate anterior displacement / forward).

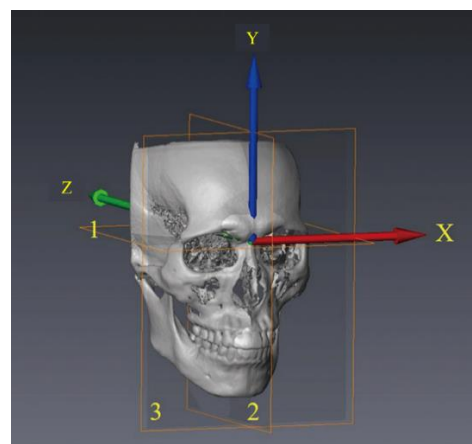


Figure 1. Reference axis and planes for the 3D coordinate system: X-axis (right-left); Y-axis (up-down); Z axis (posterior-anterior); 1, Horizontal plane; 2, Midsagittal plane; 3, Coronal plane²¹. (Adapted from Y.F. Chen et al. (2018))

Rotational Alterations (°) (**Figure 2**):

- Roll: Rotation around the anteroposterior axis (Positive values indicate clockwise rotation).
- Pitch: Rotation around the transverse axis (Positive values indicate clockwise rotation).
- Yaw: Rotation around the vertical axis (Positive values indicate clockwise rotation).

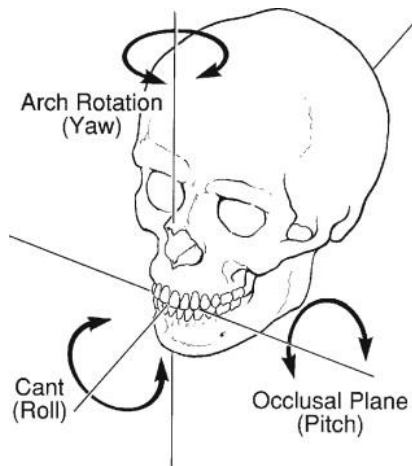


Figure 2. The yaw, pitch, and roll movements used when discussing manipulation of the maxilla for surgical repositioning. (From Erickson KL, Bell WH, Goldsmith DH: Analytical model surgery. In Bell WH, ed: Modern practice in orthognathic and reconstructive surgery, Vol 1, Philadelphia, 1992, Saunders.)

Error measurement and statistical analysis

To mitigate measurement errors and validate the reliability of the 3D assessment tool, 15 randomly selected CBCT datasets were re-digitised and re-measured after a 2-week washout period by the primary investigator and a second independent examiner. The Intra-Class Correlation Coefficient (ICC) and Mean Absolute Difference (MAD) were calculated to confirm intra-observer reproducibility and inter-observer reliability.

Statistical analyses were performed using SPSS software.

The Shapiro-Wilk test was applied to assess data normality. To compare the magnitude of 6-DOF skeletal relapse (T2-T1, T3-T1) between the 2-plate and 4-plate cohorts, the independent Student’s t-test was utilised for normally distributed variables, whereas the Mann-Whitney U test was applied for non-parametric data. A two-tailed *p*-value of <0.05 was considered statistically significant.

Results and Discussion

A comprehensive baseline analysis was conducted to verify the pre-surgical homogeneity between the two fixation cohorts. The demographic and cephalometric characteristics at T0 (**Table 1**) demonstrated a highly symmetrical distribution across the control (4-plate, $n = 22$) and test (2-plate, $n = 20$) groups. Both cohorts presented with severe skeletal Class III deformities, explicitly characterised by maxillary hypoplasia and mandibular prognathism. This severe anteroposterior discrepancy was further corroborated by highly negative ANB angles (-4.27° vs -4.36°) and Wits appraisals (-8.42 mm vs -8.76 mm). Additionally, vertical skeletal proportions (SN-MP Angle) and natural dental compensations (U1-SN Angle) were strictly consistent between the groups. Independent Student’s t-tests confirmed that there were no statistically significant intergroup differences across any baseline variables ($p > 0.562$), thereby ensuring that subsequent surgical outcomes would not be confounded by preoperative anatomical disparities.

The immediate postoperative voxel-based assessments (T1-T0) were evaluated to quantify the magnitude of actual surgical displacements executed in both cohorts (**Table 2**). The 3D spatial analysis revealed that the surgical interventions predominantly involved anterior advancement (Z) and inferior repositioning (Y) of the maxilla. Specifically, the 4-plate and 2-plate groups demonstrated comparable sagittal advancements of 5.41 ± 1.48 mm and 5.38 ± 1.52 mm, respectively, accompanied by downward displacements of 2.18 ± 1.24 mm and 2.31 ± 1.31 mm, respectively. Transverse translational shifts (X) were strictly controlled and remained minimal (< 0.15 mm) in both cohorts. Regarding rotational alterations, the surgical repositioning induced a slight clockwise Pitch rotation ($1.42 \pm 1.54^\circ$ vs. $1.61 \pm 1.59^\circ$), whereas Roll and Yaw rotations were successfully maintained below 0.5° . Independent statistical analyses confirmed that there were no significant intergroup differences across any of the six translational and rotational parameters.

Table 1. Baseline Demographic and Preoperative Cephalometric Characteristics (T0)

Variable	4-Plate Group (n = 22) Mean ± SD	2-Plate Group (n = 20) Mean ± SD	<i>p</i> -value*
Age (years)	24.38 ± 4.12	25.17 ± 4.63	0.562
SNA Angle (°)	79.14 ± 3.42	78.82 ± 3.71	0.768

SNB Angle (°)	83.41 ± 3.26	83.18 ± 3.82	0.834
ANB Angle (°)	-4.27 ± 1.84	-4.36 ± 2.12	0.881
Wits Appraisal (mm)	-8.42 ± 2.13	-8.76 ± 2.34	0.623
SN-MP Angle (°)	32.14 ± 4.52	31.89 ± 4.81	0.861
U1-SN Angle (°)	112.34 ± 5.61	111.92 ± 5.83	0.812

Note. SNA < 82° indicates maxillary hypoplasia; SNB > 80° indicates mandibular prognathism; Wits appraisal strongly confirms severe Class III skeletal discrepancy.

*Independent Student’s T-tests: p < 0.05 indicates statistical significance.

Table 2. Immediate 6-DOF Voxel-Based Surgical Displacements (T1-T0)

6-DOF Parameters	4-Plate Group (n = 22)	2-Plate Group (n = 20)	p-value
	Mean ± SD	Mean ± SD	
Translational Changes (mm)			
X-axis (Transverse)	0.12 ± 0.42	0.14 ± 0.47	0.882
Y-axis (Vertical)	2.18 ± 1.24	2.31 ± 1.31	0.741
Z-axis (Sagittal)	5.41 ± 1.48	5.38 ± 1.52	0.947
Rotational Changes (°)			
Pitch	1.42 ± 1.54	1.61 ± 1.59	0.686
Roll	0.31 ± 0.38	0.38 ± 0.41	0.562
Yaw	0.42 ± 0.39	0.49 ± 0.43	0.584

Note. Positive values indicate displacement to the left (X), inferiorly (Y), anteriorly (Z), and clockwise rotation (Pitch, Roll, Yaw)

Table 3. 6-DOF Spatial Relapse at 6-Month (T2-T1) and 1-Year (T3-T1) Follow-ups

6-DOF Parameters	6-Month Relapse (T2-T1)		1-Year Relapse (T3-T1)		p-value*
	4-Plate (n=22)	2-Plate (n=20)	4-Plate (n=22)	2-Plate (n=20)	
Translational (mm)					
X-axis	0.22 ± 0.34	0.26 ± 0.38	0.31 ± 0.39	0.37 ± 0.42	0.632
Y-axis	-0.38 ± 0.41	-0.44 ± 0.46	-0.48 ± 0.51	-0.54 ± 0.59	0.724
Z-axis	-0.41 ± 0.47	-0.49 ± 0.51	-0.52 ± 0.56	-0.61 ± 0.63	0.627
Rotational (°)					
Pitch	-0.42 ± 0.48	-0.51 ± 0.54	-0.58 ± 0.59	-0.69 ± 0.64	0.561
Roll	0.21 ± 0.29	0.26 ± 0.32	0.28 ± 0.34	0.33 ± 0.37	0.644
Yaw	0.28 ± 0.31	0.32 ± 0.34	0.37 ± 0.38	0.43 ± 0.41	0.628

Note. *p-values derived from independent Student’s t-tests. p < 0.05 indicates statistically significant

Building upon the immediate postoperative surgical displacements, the long-term 6-DOF spatial stability of the repositioned maxilla was longitudinally evaluated at 6-month (T2-T1) and 1-year (T3-T1) intervals (**Table 3**). The voxel-based tracking revealed a trend of highly robust structural stability across both fixation cohorts over time. Throughout the 1-year follow-up period, all translational relapses (X, Y, and Z axes) remained strictly under the clinically significant threshold of 1.0 mm. Specifically, the highly susceptible transverse dimension (X-axis) exhibited minimal lateral drift, reaching only 0.31 ± 0.39 mm in the 4-plate group and 0.37 ± 0.42 mm in the 2-plate group at T3. Sagittal and vertical relapses followed a similar stable pattern, with negative values indicating a slight posterosuperior settling that was nearly identical between the two groups. Concurrently, rotational adaptations (Pitch, Roll, and Yaw) were uniformly restricted to less than 1.0° across all time points. Independent statistical comparisons confirmed that there were no significant differences in the

magnitude of either translational or rotational relapse between the 4-plate and 2-plate cohorts at the final 1-year assessment (all p > 0.561). Overall, the data demonstrate that both fixation modalities exhibit minimal, equivalent spatial drift over the long term.

This 1-year retrospective cohort study aimed to quantitatively determine whether reducing rigid internal fixation from 4 to 2 plates compromises the 3D spatial stability of the repositioned maxilla in Le Fort I osteotomies, with a specific focus on the transverse dimension and 6-degrees-of-freedom (6-DOF). Based on this study's comprehensive voxel-based superimposition, the findings firmly support our primary hypothesis: 2-plate fixation at the zygomaticomaxillary buttresses yields long-term 3D spatial stability equivalent to the conventional 4-plate approach. The magnitude of translational (ΔX, ΔY, ΔZ) and rotational (Pitch, Roll, Yaw) relapses were clinically negligible (< 1.0 mm and < 1.0°) and statistically

indistinguishable between the two cohorts.

The traditional 4-plate configuration, while historically considered the biomechanical standard, necessitates extensive mucoperiosteal elevation, prolongs operative time, and significantly increases the iatrogenic risk of injuring the anterior dental roots and the infraorbital neurovascular bundles [17-19]. According to the established hierarchy of stability proposed by Proffit *et al.* maxillary expansion and transverse surgical movements are notoriously the most unstable orthognathic procedures, highly susceptible to relapse [16, 20, 21]. Therefore, the most critical clinical apprehension regarding the omission of pyriform aperture plates is the vulnerability to transverse drift (ΔX) and rotational yaw under the continuous strain of the masticatory musculature [16, 22, 23]. However, the data demonstrated robust transverse stability, with lateral deviations restricted to 0.37 ± 0.42 mm in the 2-plate group and 0.31 ± 0.39 mm in the 4-plate group at the 1-year follow-up. This remarkable transverse rigidity clearly demonstrates the biomechanical advantage of maintaining an intact maxillary arch (monobloc Le Fort I) over multisegmental osteotomies. Segmental Le Fort I procedures inherently compromise the structural continuity of the maxillary vault, rendering the isolated fragments highly susceptible to lateral relapse driven by palatal tissue contraction and muscular forces [24-28]. In stark contrast to our monobloc findings (< 0.4 mm transverse drift), the 3D voxel-based validation study by da Costa Senior *et al.* on segmented Le Fort I procedures demonstrated significantly greater transverse instability, reporting relative errors for left/right translational movements reaching up to 2.2. Furthermore, they observed substantial spatial variability across the isolated segments, with standard deviations reaching up to 2.84 mm in the transverse dimension of the central segment [16, 29, 30].

Biomechanically, the zygomaticomaxillary buttress offers the thickest and most dense cortical bone in the midface, providing an optimal foundation for maximum screw engagement [9, 31]. In *in vitro* and finite element analysis (FEA) studies, authors such as Erkmén *et al.* and Esen *et al.* have suggested that 4-plate configurations distribute mechanical stress more favorably and exhibit less micromovement under heavy artificial loading (e.g., >20 N) [10, 11]. However, our *in vivo* clinical results indicate that the structural integrity of 2-plate fixation is physiologically sufficient to withstand actual postoperative functional loads. When combined with thick 0.8-mm locking plates and immediate postoperative occlusal interdigitation - which acts as an intrinsic functional splint - the two zygomatic anchors effectively neutralize lateral and rotational muscular pull, preventing transverse expansion or constriction during the critical bone-healing phase [16, 22, 32].

In sagittal (ΔZ) and vertical (ΔY) dimensions, both of this cohorts exhibited minimal relapse, reflecting a slight

posterosuperior settling typical of Le Fort I bone healing. Our findings align closely with the long-term clinical observations of Fujio *et al.* and Murray *et al.*, which reported no significant differences in the horizontal and vertical relapse between 2- and 4-plate fixations using traditional 2D cephalometry [33-36]. Furthermore, the findings of Susarla *et al.* also demonstrated stable 1-year outcomes relying solely on two-point nasomaxillary fixation [18, 37, 38]. Crucially, the current literature transitions from conventional 2D metrics to 6-DOF voxel-based superimposition, which could eliminate inherent 2D magnification errors and anatomical superimpositions, providing definitive evidence that 2-plate fixation does not precipitate hidden rotational collapses (Pitch or Roll) that frequently go undetected in traditional lateral cephalograms.

Reducing rigid internal fixation from 4 to 2 plates in monobloc Le Fort I osteotomy at the zygomaticomaxillary buttresses provides equivalent 6-DOF spatial stability and serves as a highly reliable, minimally invasive alternative. Despite the robust 3D methodology, certain limitations must be acknowledged. The retrospective design inherently carries selection bias. Additionally, while structural stability was validated, this study did not quantify patient-specific postoperative masticatory bite forces using intraoral sensors, which could provide deeper insights into individual dynamic loading patterns. Future prospective, randomised controlled trials incorporating objective bite-force measurements, 3D airway volume adaptations, and patient-specific implants (PSIs) designed specifically for two-point fixation are warranted to further optimise this minimally invasive protocol.

Conclusion

In monobloc Le Fort I osteotomies, reducing rigid internal fixation from four plates to two at the zygomaticomaxillary buttresses provides equivalent six-degrees-of-freedom (6-DOF) spatial stability to the conventional technique. This approach offers a highly reliable, minimally invasive alternative that significantly simplifies the procedure without increasing the risk of transverse or rotational relapse.

Acknowledgments: None

Conflict of interest: None

Financial support: This research received no specific grant from any funding agency, commercial entity, or not-for-profit organization. Therefore, no funding information, grant numbers, or sponsor roles are applicable.

Ethics statement: This study was supported by the Independent Ethics Committee IEC, Tra Vinh University (Ref number 185/GCN.ĐC-HĐĐ); and the IEC of Van Hanh General Hospital (Ref number 01/2025/GCN-HĐĐ).

References

- Oudah A, Ali M, Mohammed N. The strategic role of bilateral sagittal split osteotomy in a advanced surgical management of mandibular skeletal discrepancies. *Bull Stomatol Maxillofac Surg*. 2025;150-60.
- Saghafi H. 3D Assessment of the skeletal stability of the surgery-first approach for orthognathic correction of maxillary deficiency [PhD thesis]. University of Glasgow; 2024.
- Bang SM, Kwon YD, Kim SJ, Lee BS, Choi BJ, Ohe JY, et al. Postoperative stability of 2-jaw surgery with clockwise rotation of the occlusal plane. *J Craniofac Surg*. 2012;23:486-90.
- Csep AN, Voiță-Mekereș F, Tudoran C, Manole F. Understanding and managing polypharmacy in the aging population. *Ann Pharm Pract Pharmacother*. 2024;4:17-23. doi:10.51847/VdKr0egSln
- Tai W, Leung YY, Li DTS. Le Fort I osteotomy with segmentation for the treatment of maxillary dentoalveolar protrusion: a single-centre, 10-year outcome study. *Int J Oral Maxillofac Surg*. 2022;51(9):1197-204.
- Ali RB, Drobyshev AY, Sharov MN, Melikov EA, Mikhaylyukov VM. Recovery of neurosensory function of the maxillofacial region following orthognathic surgery. *Head Neck (Russ J)*. 2024;12.
- Guzek K, Stelmach A, Roźnowska A, Najbar I, Cichocki Ł, Sadakierska-Chudy A. A preliminary investigation of genetic variants linked to aripiprazole-induced adverse effects. *Ann Pharm Pract Pharmacother*. 2023;3:40-7. doi:10.51847/ZT28xcs95J
- Ho MW, Boyle MA, Cooper JC, Dodd MD, Richardson D. Surgical complications of segmental Le Fort I osteotomy. *Br J Oral Maxillofac Surg*. 2011;49(7):562-6.
- Fujio M, Ogisu K, Chang Q, Tsuboi M, Hibi H. Comparison study of the Le Fort I osteotomy using 2- and 4-plate fixation. *Nagoya J Med Sci*. 2024;85.
- Erkmen E, Ataç MS, Yücel E, Kurt A. Comparison of biomechanical behaviour of maxilla following Le Fort I osteotomy with 2- versus 4-plate fixation using 3D-FEA. *Int J Oral Maxillofac Surg*. 2009;38(2):173-9.
- Kariri HDH, Radwan OA, Somaili HE, Mansour MEI, Mathkoo SA, Gohal KMM. The role of psychological capital in enhancing empowerment among female leadership. *Ann Organ Cult Leadersh Extern Engagem J*. 2024;5:17-27. doi:10.51847/w41TjwMAzM
- Tam LT, An HTT, Linh TK, Nhung LTH, Ha TNV, Huy PQ, et al. The impact of COVID-19 on value co-creation activities: a study of economics students in Vietnam. *Ann Organ Cult Leadersh Extern Engagem J*. 2023;4:25-34. doi:10.51847/QeaHrAoLoL
- Singh D, Piplani M, Kharkwal H, Murugesan S, Singh Y, Aggarwal A, et al. Comprehensive review on the anticancer potential of thiazolidin-4-one derivatives. *Asian J Curr Res Clin Cancer*. 2023;3(1):46-62. doi:10.51847/MpJ9fZKGZT
- Hashem W, Mokhtar M, Rahman AA, Rashad A. Adult acute lymphoblastic leukemia: insights from six years of clinical practice in an Egyptian tertiary care center. *Asian J Curr Res Clin Cancer*. 2024;4(2):51-61. doi:10.51847/fFirKGgI3X
- Esen A, Celik B, Dolanmaz D. Biomechanical evaluation of two miniplate fixations applied in the anterior region after Le Fort I osteotomy: an experimental study. *Br J Oral Maxillofac Surg*. 2022;60(2):152-6.
- Da Costa Senior O, Vaes L, Mulier D, Jacobs R, Politis C, Shaheen E. Three-dimensional assessment of segmented Le Fort I osteotomy planning and follow-up: a validation study. *J Dent*. 2021;111:103707.
- Alasseri N, Swennen G. Minimally invasive orthognathic surgery: a systematic review. *Int J Oral Maxillofac Surg*. 2018;47(10):1299-310.
- Susarla SM, Ettinger R, Preston K, Kapadia H, Egbert MA. Two-point nasomaxillary fixation of the Le Fort I osteotomy: assessment of stability at one year postoperative. *Int J Oral Maxillofac Surg*. 2020;49(4):466-70.
- Salikhova LR, Khantueva KK, Magomedkerimova NN, Arganov FI, Tambieva TS, Brodskaya TA. Evaluating the likelihood of hypoxia in pregnant women through analysis of erythrocyte membrane permeability. *Interdiscip Res Med Sci Spec*. 2023;3(1):20-5. doi:10.51847/nsfOJO4IDE
- Rios O, Lerhe B, Chamorey E, Savoldelli C. Accuracy of segmented Le Fort I osteotomy with virtual planning in orthognathic surgery using patient-specific implants: a case series. *J Clin Med*. 2022;11(19):5495.
- Nyamagoud SB, Swamy AHV, Chacko A, James J. A case report on actinomycetoma of the left foot: highlighting a neglected tropical disease and the consequences of poor medication adherence. *Interdiscip Res Med Sci Spec*. 2024;4(2):41-7. doi:10.51847/UcEjBW4qBs
- Haas Junior OL, Guijarro-Martínez R, De Sousa Gil AP, De Oliveira RB, Hernández-Alfaro F. Stability and surgical complications in segmental Le Fort I osteotomy: a systematic review. *Int J Oral Maxillofac Surg*. 2017;46(9):1071-87.
- Petronis Z, Golubevas R, Rokicki JP, Guzeviciene V, Sakavicius D, Lukosiunas A. A systematic review and meta-analysis on trigeminal neuralgia linked to neurovascular compression using MRI analysis. *J Curr Res Oral Surg*. 2025;5:17-24. doi:10.51847/sptZWIrWeo
- Ying X, Tian K, Zhang K, Ma X, Guo H. Accuracy of virtual surgical planning in segmental osteotomy in combination with bimaxillary orthognathic surgery with surgery first approach. *BMC Oral Health*. 2021;21(1).
- Hichijo N, Furutani M, Kuroda S, Tanaka E. Excessive gingival display treated with 2-piece segmental Le Fort I osteotomy. *J Am Dent Assoc*. 2019;150(1):58-68.
- Rahpeyma A, Khajehahmadi S. Effects of bimax and

- segmental surgeries for correction of bimaxillary dentoalveolar protrusion class I on soft tissue parameters: upper lip thickness and curvature, nasolabial angle and nasal prominence. *J Contemp Dent Pract.* 2013;14(6):1087-93.
27. Leadbeatter D, Tjaya KC. Human rights and bioethical principles in correctional settings: a systematic review of the evidence. *Asian J Ethics Health Med.* 2024;4:97-106. doi:10.51847/wSNBedLrGt
 28. Bratt A, Naimi-Akbar A. A comparative study of ethical issues in the Egyptian clinical research law. *Asian J Ethics Health Med.* 2023;3:66-80. doi:10.51847/mjnPnkn27U
 29. Muthanandam S, Muthu J, Babu BV, Rajaram S, Kengadharan S. Raising awareness of oral precancer and cancer among Indian long-distance heavy vehicle drivers: a neglected group. *Int J Soc Psychol Asp Healthc.* 2024;4:20-5. doi:10.51847/2JNlaeP6n5
 30. Çınaroğlu M, Ahlatcıoğlu EN, Prins J, Nan M. Psychological challenges in cancer patients and the impact of cognitive behavioral therapy. *Int J Soc Psychol Asp Healthc.* 2023;3:21-33. doi:10.51847/ZDLdztUSsw
 31. Cissé C, Konaré MA, Samaké M, Togola I. Exploring the anti-inflammatory potential of *Sericanthe chevalieri* and *Ceiba pentandra* as natural antitussives for children. *Spec J Pharmacogn Phytochem Biotechnol.* 2024;4:49-58. doi:10.51847/0OVczhRtw1
 32. Chen AMH, Chen Y. Pharmacognostic and phytochemical comparison of *Moringa oleifera* and *Moringa concanensis*. *Spec J Pharmacogn Phytochem Biotechnol.* 2023;3:1-9. doi:10.51847/iVjkOGlcDE
 33. Hernández-Alfaro F, Saavedra O, Duran-Vallès F, Valls-Ontañón A. On the feasibility of minimally invasive Le Fort I with patient-specific implants: proof of concept. *J Stomatol Oral Maxillofac Surg.* 2024;125(3):101844.
 34. Mavili ME, Canter HI, Saglam-Aydinatay B. Semirigid fixation of mandible and maxilla in orthognathic surgery. *Ann Plast Surg.* 2009;63(4):396-403.
 35. Murray RA, Upton LG, Rottman KR. Comparison of the postsurgical stability of the Le Fort I osteotomy using 2- and 4-plate fixation. *J Oral Maxillofac Surg.* 2003;61(5):574-9.
 36. Manfredini M, Poli PP, Giboli L, Beretta M, Maiorana C, Pellegrini M. Determinants of dental implant prognosis: a systematic review of key influencing factors. *J Curr Res Oral Surg.* 2024;4:41-9. doi:10.51847/Gv4h1XyPfr
 37. Cakmak C, Cinar F, Çapar H, Cakmak MA. The connection between cancer screening, awareness, and perceptions: insights from the American population. *Int J Soc Psychol Asp Healthc.* 2024;4(1):32-41. doi:10.51847/CCd71JaG8g
 38. Çınaroğlu M, Ahlatcıoğlu EN, Prins J, Nan M. Psychological challenges in cancer patients and the impact of cognitive behavioral therapy. *Int J Soc Psychol Asp Healthc.* 2023;3(1):21-33. doi:10.51847/ZDLdztUSsw