

# 3D PRINTED CUSTOMIZED CAD-CAM IMPLANT ABUTMENT FOR CORRECTION OF ANGULATED IMPLANT IN ESTHETIC ZONE-A CASE REPORT

Subhabrata Maiti<sup>1\*</sup>, Nitesh Rai<sup>2</sup>, Ponnanna Appanna<sup>2</sup>, Jessy Paulraj<sup>3</sup>

<sup>1</sup>Department of Prosthodontics, Saveetha Dental College and Hospitals, Saveetha Institute of Medical and Technical Sciences, Saveetha University Chennai -77, Tamil Nadu, India. drsubhoprotho@gmail.com

<sup>2</sup>Department of Prosthodontics, Krishnadevaraya College of Dental Science and Hospital Bangalore, Karnataka, India.

<sup>3</sup>Department of Pedodontics, Saveetha Dental College and Hospitals, Saveetha Institute of Medical and Technical Sciences, Saveetha University Chennai -77, Tamil Nadu, India.

<https://doi.org/10.51847/GUxhI7gCjJ>

## ABSTRACT

Aesthetic is always a key consideration for patients needing anterior teeth. An implant is the first choice of treatment in modern dentistry. Due to bone availability or underlying anatomical structure, implant placement may not always be favorable. With customized digital design and manufacturing using 3D printing DMLS technology, prosthetic management of angulated implants can produce results that are much more accurate, precise, and error-free. This case report will explain a case of a 38 years old female patient with grade III mobile teeth who was rehabilitated with CAD-CAM customized partial hybrid prosthesis where from the beginning of the case aesthetic was the prime factor. Immediate denture was planned along with natural teeth as denture teeth in order to preserve the aesthetics. CAD CAM abutment was excellent in accuracy where internal fit was done digitally through scan body and digital analog and superstructure framework was made based on digital wax up; then it was layered with indirect composite for high esthetic and easy repair. Screw retained prosthesis was planned for easy recovery and maintenance. The aesthetic rehabilitation in advance of digital implant dentistry is the prime focus of this case report.

**Key words:** Custom abutment, 3D printing, Angulated implant, CAD CAM, Esthetic, Digital dentistry.

## Introduction

Aesthetic is always a key consideration for patients needing anterior teeth as the orofacial construction depends on the stomatognathic system. Rehabilitation with implants is a recent trend for patient satisfaction and successful survival, but the implant placement position cannot always be favorable due to bone availability or underlying anatomical structure. Unfavorable placement or an angular implant always requires abutment customization for the suitable prosthetic requirement. The function of implant-supported restorations, as well as the nearby soft tissue health and soft tissue stability, are influenced by the design and precision of the implant-abutment connection. Stock abutments are a practical option for implant restorations, according to years of implant dentistry experience. However, new types of abutments—custom abutments—have emerged as a result of technological advancement. These abutments can easily be made for each patient, even with various materials depending on the patient's requirements. They can be created quickly using the CAD/CAM (Computer-Aided Design and Computer-Aided Manufacturing) technique [1-4]. The main issue with stock abutments was that it was difficult to achieve tissue compatibility and that they were insufficient for angulated implants. Custom abutments, however, are distinctive and created for specific patients. Additionally, these treatments improve the ability to clean and stop food residues under the abutment. Generally, Ti

base castable abutments, milling, or custom abutments can be used for customization; however, the decision to use precision fit is still up for debate.

The connection between the implant and the abutment is not "original," which is the main issue with custom abutments. These hex connections that come after them may not be entirely compatible with the implants. These surfaces can only be manufactured using calibrated, highly precise equipment. Tissue will always eventually fit the shape of the abutment, which is a major problem with stock implants. This means that maintaining the best emergence contours may become challenging for the dentist, leading to an unnatural finish. This may also imply a reduction in the amount of tissue support offered to adjacent teeth. The introduction of CAD-CAM abutment was made to address issues with traditional casting castable abutments. By using software to virtually design and print a DMLS digital CAD CAM abutment, angulation correction, precision passive fit, and accurate soft tissue adaptation can be accomplished [5, 6]. The CAD-CAM abutment is the option for implant restoration in the aesthetic zone because it creates a natural emergence profile between an implant and crown, can be customized for Crown Margin Depth and allows for better hygiene, aesthetics, and alignment with angled implants.

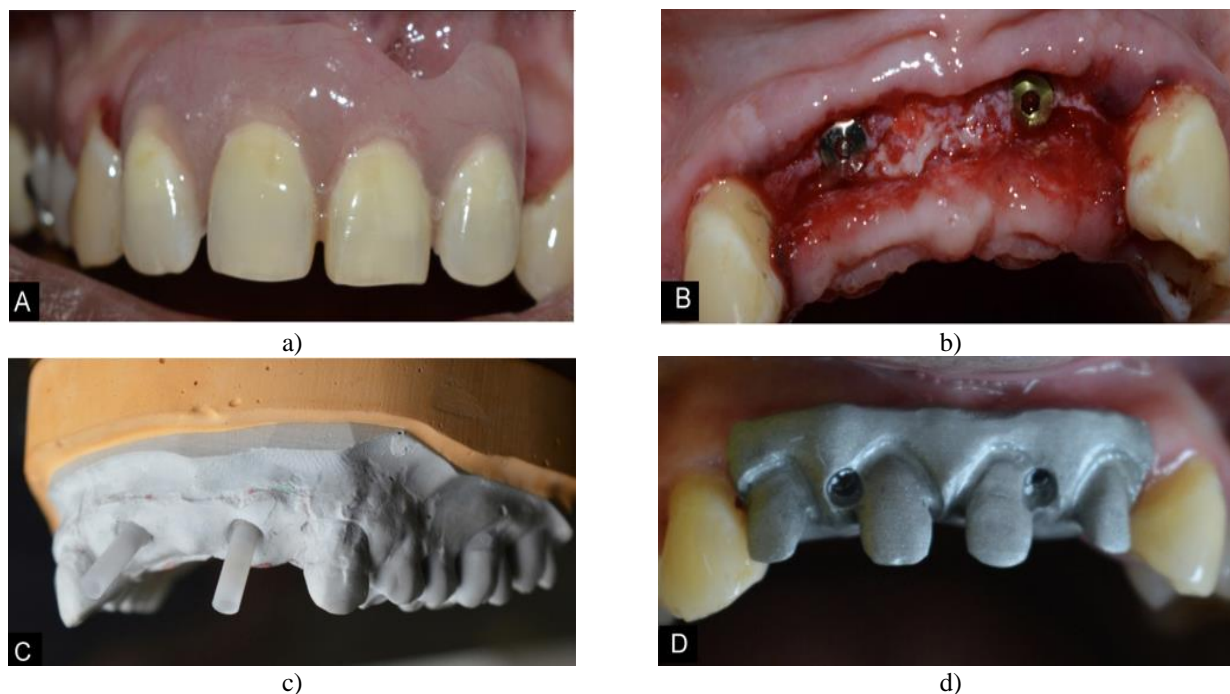
Manufacturing will change as a result of 3D printing, which has been dubbed a disruptive technology. DMLS is a form

of 3D printing technology that can be used to customize implant abutments with precise fit and passivity. The mechanical side effects of implant-supported rehabilitations, such as screw loosening or porcelain fractures, are a major risk factor in excessive crown height space [7-10]. A digitally approached, 3D printed screw retained framework with a custom abutment will therefore be the most effective approach in these compromised situations [11]. This is thought to have the benefits of precision, avoiding casting errors, and labor-intensive, light prosthesis. A young patient who had lost anterior teeth was the subject of this case report, which aimed to highlight and describe the step-by-step anterior aesthetic rehabilitation of that patient.

#### Case report

A 38-year-old female patient reported to a dental hospital, in Bangalore; with the chief complaint of mobile upper front teeth. On examination, it was observed that the teeth' mobility was right and left side maxillary central and lateral

incisor showing compromised horizontal bone width with deficient vertical height. The periodontal health of all other teeth was good. The patient was healthy with no known medical issues. Mobility was assessed with grade III and recommended for extraction followed by immediate denture as the esthetic was of prime concern for the patient. The temporary acrylic immediate partial denture was fabricated using the patient natural teeth in order to preserve the anterior natural esthetic. All the anterior teeth were splinted with dental floss before the impression and the cast were made. After making a putty index, teeth were trimmed and pulp was removed from natural teeth and used to fabricate dentures (**Figure 1**). The immediate denture was delivered with soft lining material (GC). Then the patient was recommended to wait for 6 weeks for healing. The patient was chosen as a candidate for implant-supported prostheses after CBCT (cone-beam computed tomography) analysis revealed manageable available bone for implant placement.



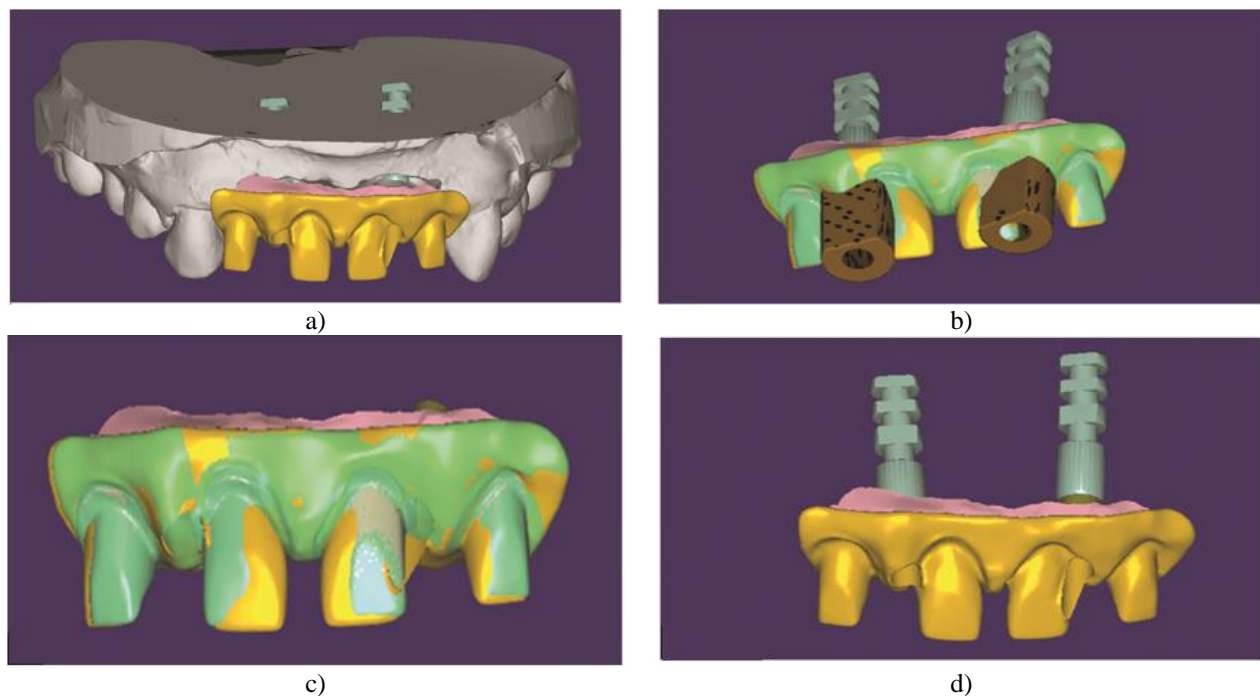
**Figure 1.** a) Immediate partial denture using naturally extracted teeth; b) Implant placement -surgical phase; c) Angulation of the implant -prosthetic phase; d) 3D printed mental framework with custom abutment -trial in the patient

Utilizing a manually made acrylic surgical guide that was obtained through wax up, two implants (MIS 3.75 x mm 11.5 mm standard platform) were inserted. With a 40N torque, the recommended implant placement protocol produced excellent primary stability. Osseointegration was assessed after a 6-month healing period, and second-stage surgery was carried out. Due to the compromised bone architecture, the implant was not in an ideal position. Therefore, it was decided to create a custom abutment with a screw-retained substructure framework and indirect composite layering on it for high esthetic and easy repair. A

polyvinyl siloxane impression material (3M) was used to create an implant-level impression after three weeks. The impression coping (MIS Closed tray) was attached to the implant laboratory analog (MIS), and an implant cast was created using a soft tissue gingival mask (GiMASK coltene) and a Type IV die stone (Kalrock). The model was scanned using a laboratory intraoral scanner (Medit SCANNER) attaching scan bodies on the implant analog to get the implant position and transfer the data to the design software. The missing teeth along with deficient soft tissue were planned in the digital design in a 3D design software

(Exocad) and a framework of substructure with labial access hole according to digital was up was designed (**Figure 2**). The abutment with internal hex was also designed along with the framework after checking the fit with digital analog. The angulation of implants was managed with this digital design and the precision fit design was planned along with it. The manufacturer of the chrome cobalt (cr-co) framework was done using metal three-dimensional printing DMLS (direct metal laser sintering) technology to get a highly precise outcome with lightweight and accuracy (**Figure 3**). Using a photograph and a customized shade tab, the pink gingival component was matched and VITA classic shade guide along with a digital spectrophotometer was for tooth color matching. DMLS 3D printed framework was placed in the patient's mouth and examined for a precise and passive fit. The indirect composite resin material (SR Adoro, Ivoclar Vivadent AG, Liechtenstein) was used to

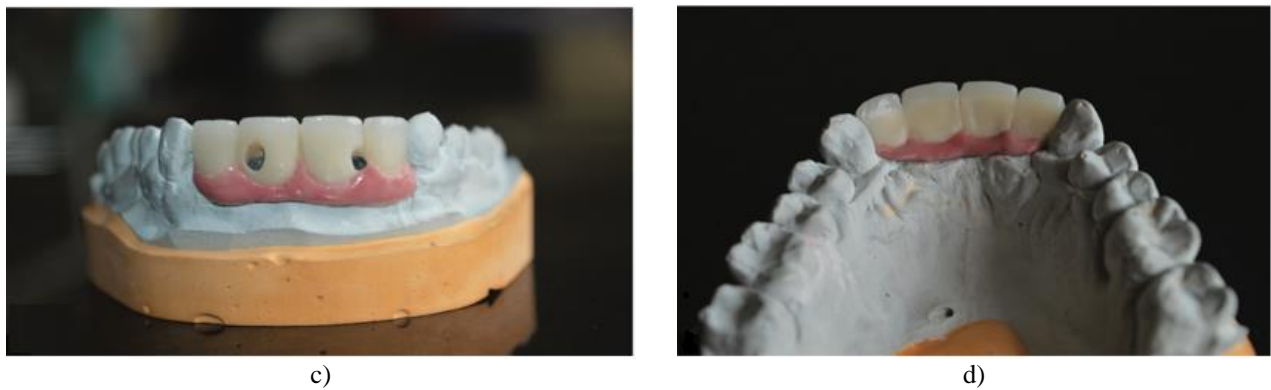
layer the 3D printed framework to achieve a good pink-and-white aesthetic. The abutment screw was then tightened to a 30N torque, and then cotton and gutta-percha were packed to stop the abutment screw from rotating and to seal the access hole. the hole was covered with direct composite with proper color matching. A minute natural stain spot (almost invisible, without disturbing esthetic) was made on the screw access hole area to locate it anytime for further correction and maintenance (**Figure 4**). To prevent food lodgment, the prosthesis' inner surface was given a modified ridge lap pattern. Occlusion was corrected in the articulator as well as the patient's mouth, anterior guidance was assessed and corrected before final polishing, keeping canine-guided occlusion to what was already existing. The patient was advised to use WaterPik to maintain good oral hygiene. Recall appointments were fixed for follow-up and maintenance.



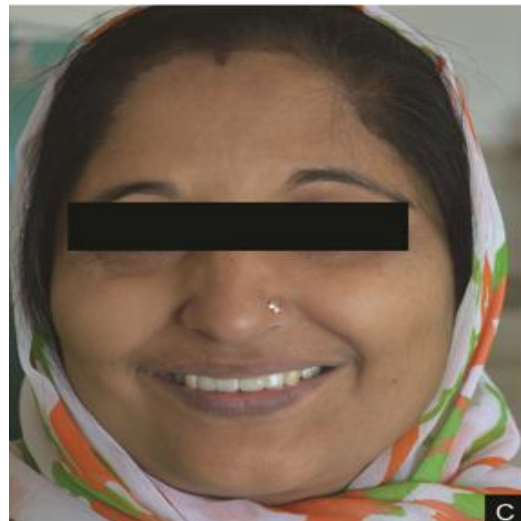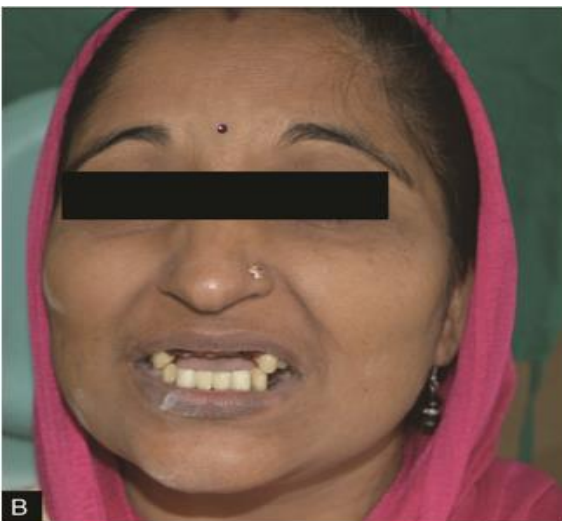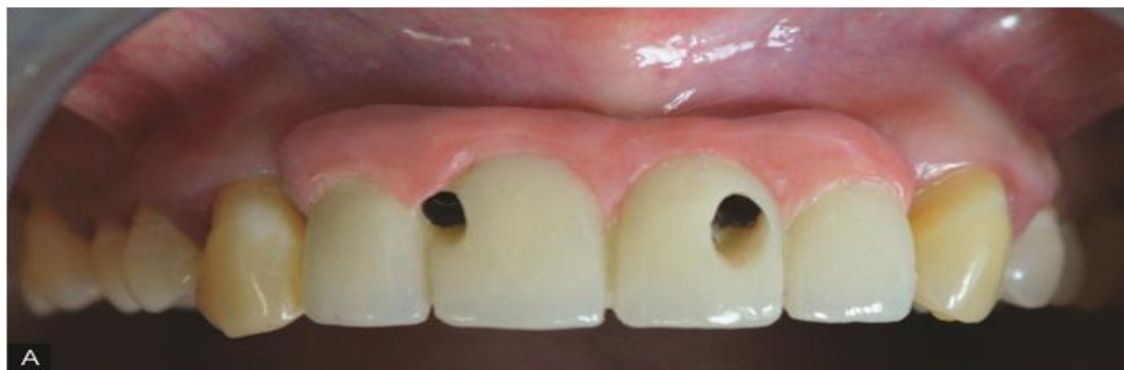**Figure 2.** a) Digital framework design in the virtual cast; b) Framework with scan body and virtual analog for position evaluation; c) Digital framework evaluation; d) virtual fitting of the framework







**Figure 3.** a) Innersurface of 3D printed DMLS framework attached with abutment; b) fitting check using implant analog; c) Indirect composite layering with labial access hole (labial view); d) Indirect composite layering with labial access hole (palatal view)



**Figure 4.** a) Innersurface of 3D printed DMLS framework attached with abutment; b) fitting check using implant analog; c) Indirect composite layering with labial access hole (labial view); d) Indirect composite layering with labial access hole (palatal view)

**Results and Discussion**

Stock abutments provide compromised support to the proximal and labial peri-implant soft tissues because they are at most cylindrical or divergent, which is different from the emergence profile of natural teeth. Using computer-aided design/computer-aided manufacturing (CAD/CAM)

technology, implant abutments can also be made. In order to minimize the risk of cement remnants deep in the sulcus, the CAD/CAM process optimizes the geometry of the abutment, including the position of the outline following the nearby natural roots and the gingival margin. The abutment's finish is managed to prevent sharp edges, and the design can account for unsatisfactory implant angulation.

When an abutment is custom designed, it is the abutment material rather than the ceramic crown that supports and interacts with the soft tissues, especially in the case of the hybrid prosthesis [12, 13]. In the case of the individual implant-supported fixed prosthesis, the configuration of the abutment gives a great emergence profile and prevents the entrapment of bacteria to enter. These include biological advantages [4]. It is less time-consuming and does not require extra finishing procedures as the whole prosthesis is a digital design with precision fit and the finish includes mechanical advantages. The prosthetic precision fit, passivity, and unique customized design provide biomechanical advantages for a high survival rate.

Excessive weight and thermal expansion during the application of the porcelain layer may interfere with precision-fit due to repeated firing cycles [14, 15]. Another choice is a hybrid prosthesis which has a more chance of acrylic debonding and breakage [16, 17]. So the best choice is indirect composite layered on a 3D printed metal substructure which addresses to a greater extent in those limitations. Hence mallo bridge framework design was chosen as it was a non-ideal placement of implant due to vertical bone loss. On the other hand, this type of prosthesis eliminates the screw access openings in the occlusal surface of the crowns and also, makes it possible to remove and repair the fractured composite without removing the whole structure. In addition, the sealing of the gingival component resembles the aesthetics of the anatomical gingival sulcus. Direct metal laser sintering is one of the 3D printing technologies that directly can create a metal component from its 3D computer model [18]. The implant abutment and hex connection was printed through this technology to eliminate all casting errors and to achieve a precise passive fit of a non-engaging abutment.

### Conclusion

Three-dimensional printing has been hailed as a game-changing innovation that will revolutionize the manufacturing industry. Newer fields of digital dentistry made the path easy and advanced. Digitalization can be done to design the internal hex in the design software and the manufacturing can be done using three-dimensional metal printing DMLS (direct metal laser sintering) technology. A different approach to esthetic rehabilitation and smile makeover by digital means and the use of advanced digitalization in implant dentistry is the introduction of a new era in the field of dentistry.

**Acknowledgments:** Authors would like to thanks krishnadevaraya college of dental science, bangalore where the case was done, also Directors of Confident Dental Laboratory Private Limited Dr. Shiva shankar for the digital support and Saveetha University for giving platform of publication.

**Conflict of interest:** None

**Financial support:** None

**Ethics statement:** None

### References

1. Maiti S, Rai N, Appanna P, Jessy P. Digital Telescopic Denture- A Viable Treatment Modality of Preventive Prosthodontics: Clinical Report. *Ann Dent Spec.* 2022;10(4):1-4. doi:10.51847/eEgUI0vYgd
2. Shahzan S, Paulraj J, Maiti S. Assessment of Anxiety Levels in Children Receiving Dental Treatment Using Rubber Dam- A Randomized Control Trial. *Ann Dent Spec.* 2022;10(4):15-21.
3. Maiti S, Ponnanna AA, Jingade RRRK, Jessy P. Esthetic Rehabilitation with Rapid Maxillary Expansion, Lefort Osteotomy, and Gingival Veneer Prosthesis: A Case Report. *Ann Dent Spec.* 2022;10(4):29-33.
4. Lerner H, Mouhyi J, Admakin O, Mangano F. Artificial intelligence in fixed implant prosthodontics: a retrospective study of 106 implant-supported monolithic zirconia crowns inserted in the posterior jaws of 90 patients. *BMC Oral Health.* 2020;20(1):80.
5. Tamimi F, Hirayama H. *Digital Restorative Dentistry: A Guide to Materials, Equipment, and Clinical Procedures.* Springer; 2020.
6. Oshida Y, Miyazaki T. *Biomaterials and Engineering for Implantology: In Medicine and Dentistry.* Walter de Gruyter GmbH & Co KG; 2022.
7. Tang Y, Yu H, Wang J, Gao M, Qiu L. Influence of crown-to-implant ratio and different prosthetic designs on the clinical conditions of short implants in posterior regions: A 4-year retrospective clinical and radiographic study. *Clin Implant Dent Relat Res.* 2020;22(1):119-27.
8. Lombardo G, Signoriello A, Marincola M, Liboni P, Bonfante EA, Nocini PF. Survival rates of ultra-short (<6 mm) compared with short locking-taper implants supporting single crowns in posterior areas: A 5-year retrospective study. *Clin Implant Dent Relat Res.* 2021;23(6):904-19.
9. Chow J, editor. *Zygomatic Implants: Optimization and Innovation.* Springer Nature; 2020.
10. Schepke U, Meijer HJ, Kerdijk W, Raghoobar GM, Cune M. Stock Versus CAD/CAM Customized Zirconia Implant Abutments - Clinical and Patient-Based Outcomes in a Randomized Controlled Clinical Trial. *Clin Implant Dent Relat Res.* 2017;19(1):74-84.
11. Perrot A. *3D Printing of Concrete: State of the Art and Challenges of the Digital Construction Revolution.* John Wiley & Sons; 2019.
12. Zafar MS, Khurshid Z. *Dental implants: materials, coatings, surface modifications and interfaces with oral tissues.* Woodhead Publishing; 2020.
13. Real-Osuna J, Almendros-Marqués N, Gay-Escoda C. Prevalence of complications after the oral rehabilitation with implant-supported hybrid

- protheses. *Med Oral Patol Oral Cir Bucal*. 2012;17(1):e116-21.
14. Piermatti J. Using CAD-CAM technology for the full-mouth, fixed, retrievable implant restoration: a clinical report. *J Oral Implantol*. 2007;33(1):23-7.
  15. Van Rooyen P. Overview of implantology: Using 3D software and CAD/CAM technology with implant placement and restoration. *Oral Health Dent Manag*. 2018;17. doi:10.4172/2247-2452-c8-086
  16. Drago C. *Implant restorations: A step-by-step guide*. John Wiley & Sons; 2020.
  17. Wilson Jr TG, Harrel S, editors. *Dental Implant Failure: A Clinical Guide to Prevention, Treatment, and Maintenance Therapy*. Springer; 2019.
  18. Ponnanna AA, Maiti S, Rai N, Jessy P. Three-dimensional-Printed Malo Bridge: Digital Fixed Prosthesis for the Partially Edentulous Maxilla. *Contemp Clin Dent*. 2021;12(4):451-3.