Original Article

SYSTEMIC BORIC ACID AND RHBMP-2-INDUCED ALVEOLAR BONE HEALING AND OSTEOGENIC ACTIVITY AFTER TOOTH EXTRACTION IN WISTAR RATS

Christian Khoswanto[1], Oki Fadhila[1], Setyabudi[2]*

[1]*Department of Oral Biology, Faculty of Dental Medicine, Airlangga University, Surabaya, Indonesia. christiankhoswanto@gmail.com*
[2]*Department of Dental Conservative, Faculty of Dental Medicine, Airlangga University, Surabaya, Indonesia.*

Received: 02 September 2026; **Revised:** 24 October 2026; **Accepted:** 28 October 2026 https://doi.org/10.51847/q0YiS5TEdA

ABSTRACT

The aim of this study was to assess the systemic use of boric acid, local use of rhBMP-2, and the combination of systemic boric acid and local rhBMP-2 for their effect on osteoblast activity and osteocalcin (OCN) expression in maxillary extraction socket in Wistar rats. The rats were divided into Control group (C), boric acid (BA) group, rhBMP-2 group and BA + rhBMP-2 group. After the extraction of first maxillary molar, BA was given at the dose of 50 mg/kg/ day. A sterile sponge was used to locally deliver rhBMP-2 at a nominal dose of 0.25 µg per sponge. The animals were assessed on Days 10 and 20. Two-way ANOVA and Tukey's post-hoc test were used for data analysis. Osteoblast numbers and OCN expression were significantly affected by treatment, time, and treatment × time interaction. Systemic boric acid enhanced the osteogenic response associated with local rhBMP-2 during extraction socket healing. Combined treatment produced the greatest osteoblast activity and OCN expression, supporting boric acid as a potential systemic adjunct to rhBMP-2-mediated alveolar bone regeneration.

Key words: Boric acid, rhBMP-2, Osteoblast, Osteocalcin, Alveolar bone regeneration, Extraction socket.

Introduction

Tooth extraction triggers a harmonized sequence of biological events that ultimately results in repair and remodeling of the extraction socket. Directly upon extraction, the socket is occupied by a blood clot that provides a provisional matrix for cellular migration. This is followed by formation of granulation tissue and a fibrovascular matrix, osteoid deposition, development of immature bone, and subsequent remodeling and maturation. Post-extraction alveolar bone healing is clinically important because dimensional alterations of the alveolar ridge may compromise subsequent implant placement and prosthetic rehabilitation. Consequently, interventions that can enhance osteogenic activity during socket healing have attracted considerable interest in regenerative dentistry [1-3].

Osteoblasts are the principal bone-forming cells and are accountable for synthesis of osteoid and several bone-associated matrix proteins. Their presence along newly formed bone surfaces provides histological evidence of active bone formation. Osteocalcin is another important osteoblast-associated protein involved in bone matrix maturation and mineralization. Assessment of osteocalcin expression can therefore provide complementary information regarding the osteogenic status of regenerating tissue [4, 5].

Bone morphogenetic protein-2 (BMP-2) is one of the most extensively investigated osteogenic growth factors. Recombinant human BMP-2 (rhBMP-2) promotes differentiation and the process of bone formation have been examined in alveolar and craniofacial regenerative applications. Local delivery of rhBMP-2 provides a concentrated osteogenic stimulus at the site requiring regeneration [6, 7]. Nevertheless, the biological response to a local osteogenic factor may also depend on the systemic environment. Boric acid is a trace element associated with skeletal metabolism and has been investigated for its potential influence on osteoblast activity and bone-associated proteins [8, 9]. Previous experimental work has reported that systemic boric acid administration can influence alveolar bone metabolism and osteoblastic activity. The 50 mg/kg/day boric acid dose used in the present study was selected based on previous experimental work in Wistar rats reporting beneficial effects on alveolar bone-related outcomes [10].

Systemic boric acid has the potential to improve the biological response to an osteogenic local stimulus like rhBMP-2. The latter provides a local regenerative signal in the extraction socket, while systemic boric acid can alter the biological environment of osteoblast activity. This study assessed the systemic administration of boric acid, topical application of rhBMP-2 and both of these therapies after the removal of the first molar in Wistar rats in terms of osteoblast number and osteocalcin expression.

Materials and Methods

Experimental design

This experimental animal study investigated alveolar socket healing following extraction of the first maxillary molar in Wistar rats. The rats were randomly assigned to four groups:

© 2026 Annals of Dental Specialty. **Open Access** – This Article is licensed under CC BY NC SA 4.0. To view a copy of this license, visit https://creativecommons.org/licenses/by-nc-sa/4.0/

- **Control (C):** tooth extraction followed by placement of an unloaded sterile sponge into the extraction socket.
- **Boric acid (BA):** tooth extraction followed by placement of an unloaded sterile sponge into the extraction socket and systemic boric acid administration.
- **rhBMP-2:** tooth extraction followed by placement of a sterile sponge loaded with 0.25 µg rhBMP-2 into the extraction socket.
- **BA + rhBMP-2:** tooth extraction followed by placement of a sterile sponge loaded with 0.25 µg rhBMP-2 into the extraction socket and systemic boric acid administration.

Two independent healing periods were investigated: Day 10 and Day 20. Animals assigned to each time point were euthanized at the designated endpoint; therefore, Day 10 and Day 20 represented independent experimental cohorts rather than repeated measurements of the same animals. Eight animals were included in each treatment group at each time point, resulting in a total of 64 animals (4 treatment groups × 8 animals × 2 time points).

Animals and housing

Wistar rats (*Rattus norvegicus*) were used as the experimental model. Rats were housed under controlled laboratory conditions and provided Laboratory feed and unrestricted access to drinking water. Rats were acclimatized before commencement of the experimental procedures. All experiments were performed under institutional guidelines for animal welfare and use, with approval from the Airlangga University animal ethics committee (No. 0713/HRECC.FODM/VII/2026).

Randomization and blinding

Rats were randomly allocated to the four experimental groups and assigned to either the Day 10 or Day 20 endpoint using a randomization procedure in IBM SPSS Statistics version 27. Before histological and immunohistochemical assessments, the specimens were coded to conceal treatment allocation. The histologist responsible for quantitative analysis was blinded to group assignments to minimize observer bias.

Boric acid administration

Boric acid (H_3BO_3; Sigma-Aldrich, St. Louis, MO, USA) was administered at 50 mg/kg body weight/day by oral gavage once daily, from the beginning of treatment until the designated sacrifice day (Day 10 or Day 20). The individual daily dosage was calculated using the following equation:

$$\text{Daily boric acid dose (mg)} = \text{body weight (kg)} \times 50 \text{ mg/kg/day} \quad (1)$$

The calculated amount was freshly dissolved in distilled water immediately before administration and administered once daily by oral gavage. The dose was adjusted according to body weight when required to maintain a constant exposure of 50 mg/kg/day.

rhBMP-2 preparation and local administration

Local administration rhBMP-2 (Cowellmedi, Korea) was supplied as a lyophilized powder. The rhBMP-2 powder was reconstituted under sterile conditions as recommended by the manufacturer and then diluted to make the working solution using sterile physiological saline. The working solution was prepared to provide a nominal dose of 0.25 µg rhBMP-2 per sponge. Immediately before implantation, a sterile sponge measuring 2.5 × 2.5 × 2.5 mm (MedPark, Korea) was loaded with the rhBMP-2 solution corresponding to a nominal dose of 0.25 µg rhBMP-2 per sponge. The rhBMP-2-loaded sponge was immediately placed into the first maxillary molar extraction socket [11].

Tooth extraction

Following induction of anesthesia by intraperitoneal injection of ketamine (80 mg/kg) combined with xylazine (10 mg/kg), the first maxillary molar was carefully luxated and extracted using modified Bein elevators and dental extraction forceps. The extraction socket was visually examined to confirm complete tooth removal and the absence of obvious residual root fragments.

Tissue collection and histological processing

The experimental endpoint was determined according to the approved institutional protocol, and the rats were euthanized by intraperitoneal of ketamine hydrochloride (300 mg/kg) combined with xylazine (30 mg/kg) as an anesthetic overdose protocol. Special care was taken when preparing the maxillary specimens. Specimens were fixed in 10% buffered formalin, decalcified in 14% EDTA at pH 7.4, processed in graded ethanol, cleared in xylene, and paraffin-embedded. The slides were cut in serial sections of 5 µm, deparaffinized and rehydrated, then stained with hematoxylin and eosin. The morphology of the extraction sockets was assessed by light microscopy and examined for the presence of newly formed bone, osteoid tissue and distribution of osteoblasts.

Osteoblast identification and quantification

Osteoblasts were identified morphologically in hematoxylin and eosin (H&E)-stained sections using the H&E Staining Kit (ab245880; Abcam, Cambridge, UK), based on their location along newly formed bone surfaces and their cuboidal or polygonal shape. Osteoblasts were manually counted in five randomly selected, non-overlapping microscopic fields per specimen at 400× magnification. The mean osteoblast count per field was calculated for each specimen.

Osteocalcin immunohistochemistry

Immunohistochemistry was used to assess the level of expression of osteocalcin. Paraffin sections were deparaffinized and rehydrated using a series of ethanol concentrations. Antigen retrieval and immunohistochemical

staining were performed following an established laboratory protocol using an anti-osteocalcin antibody (ab93876; Abcam, Cambridge, UK). The immunoreactivity was detected by the brown, 3,3′-diaminobenzidine (DAB) stain. The quantitative evaluation was carried out using standardised microscopic fields. OCN-positive cells were quantified by direct manual counting in five randomly selected, non-overlapping microscopic fields per specimen at 400× magnification. The results for each specimen were expressed as the mean number of OCN-positive cells per microscopic field at 400× magnification.

Statistical analysis

IBM SPSS Statistics was used for statistical analyses. The treatment, healing time and treatment × time interaction effects on osteoblast number and on the expression of OCN were assessed using two-way analysis of variance (ANOVA). If significant differences were found, then pairwise comparisons were made using Tukey's post hoc test. Statistical significance was established at $p < 0.05$, and effect sizes were expressed as partial eta squared (η_p^2).

Results and Discussion

Osteoblast

Histological examination demonstrated osteoblasts distributed along the surfaces of newly formed bone within the healing extraction sockets. The number of osteoblasts differed among treatment groups and increased over the healing period.

At Day 10, osteoblast numbers were 15.50 ± 0.93 in the Control group, 19.50 ± 1.20 in the BA group, 26.50 ± 1.20 in the rhBMP-2 group, and 31.63 ± 1.06 in the BA + rhBMP-2 group.

At Day 20, osteoblast numbers were 18.25 ± 0.89, 24.00 ± 1.31, 30.13 ± 1.36, and 37.63 ± 1.06 in the Control, BA, rhBMP-2, and BA + rhBMP-2 groups, respectively.

The mean osteoblast counts for all experimental groups at Days 10 and 20 are presented in **Table 1**. The comparative changes in osteoblast number across treatment groups and observation periods are illustrated in **Figure 1a**.

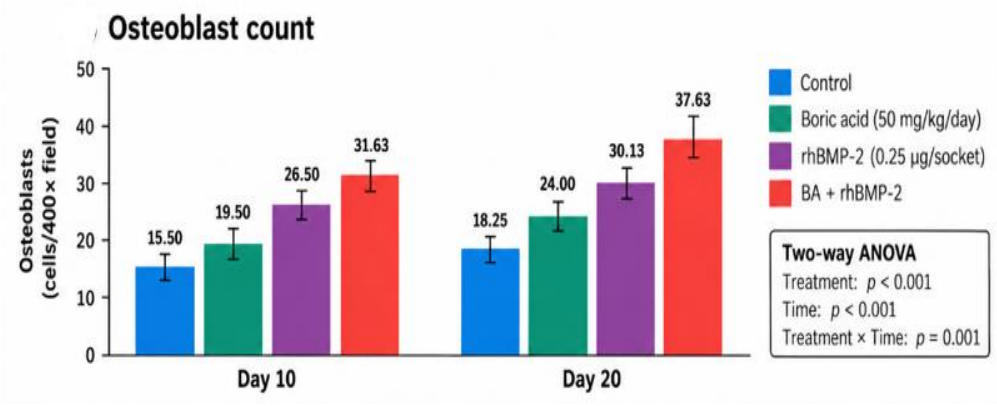

a)

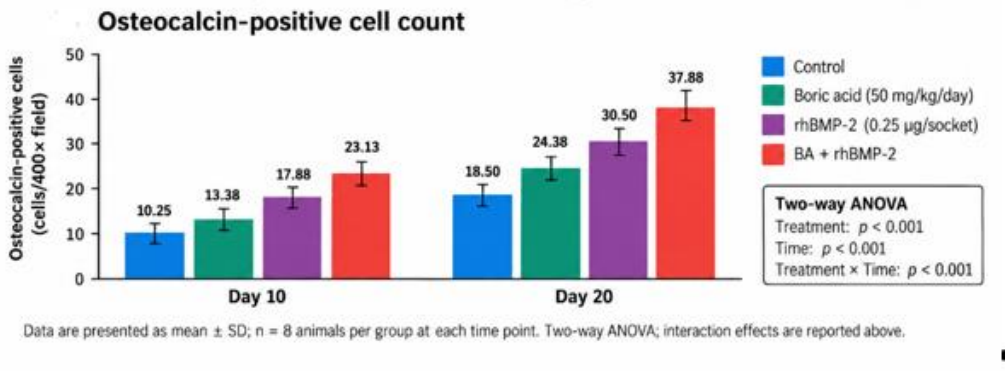

b)

Figure 1. Quantitative assessment of osteoblast counts and osteocalcin-positive cell counts in extraction sockets. (a) Mean osteoblast count per microscopic field in H&E-stained sections. (b) Mean osteocalcin-positive cell count per microscopic field in immunohistochemically stained sections. Data are presented as mean ± standard deviation, with eight animals per treatment group at each time point (Days 10 and 20). Treatment, healing time, and treatment × time interaction effects were evaluated using two-way analysis of variance (ANOVA). Statistical significance was set at $p < 0.05$. The reported p-values represent the main effects of treatment and time and their interaction.

Table 1. Mean osteoblast number in extraction sockets at Days 10 and 20 following tooth extraction in Wistar rats.

Group	Day 10	Day 20
Control	15.50 ± 0.93	18.25 ± 0.89
Boric acid (BA)	19.50 ± 1.20	24.00 ± 1.31
rhBMP-2	26.50 ± 1.20	30.13 ± 1.36
BA + rhBMP-2	31.63 ± 1.06	37.63 ± 1.06

Data presented in **Table 1** are expressed as mean ± SD (n = 8 animals per group at each time point). Treatment, healing time, and the treatment × time interaction were analyzed using two-way ANOVA, followed by Tukey's honestly significant difference (HSD) test for post hoc comparisons of the treatment main effect. The representative histological images of osteoblasts in the extraction sockets of the experimental groups at Days 10 and 20 are presented in **Figure 2**. These images illustrate the histological differences in osteoblast distribution and bone healing among the Control, BA, rhBMP-2, and BA + rhBMP-2 groups.

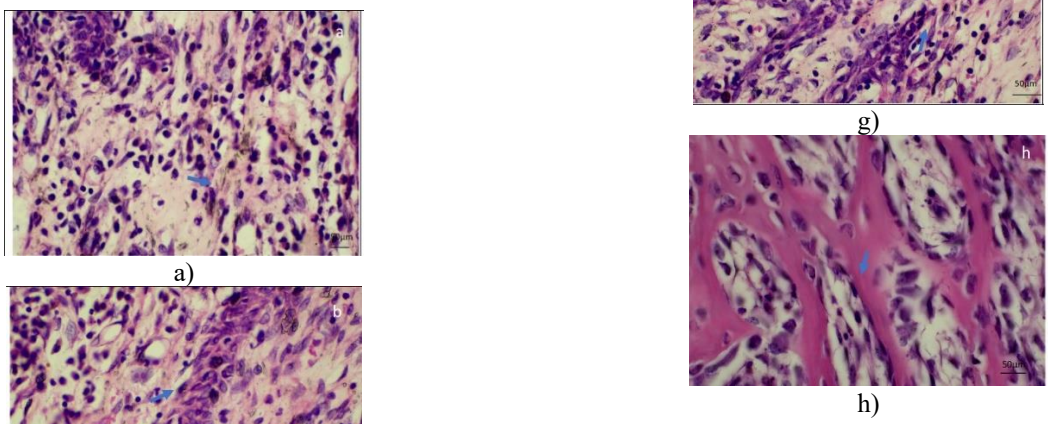

Figure 2. Histological evaluation of osteoblasts in extraction sockets. Representative H&E-stained sections from the Control (a, b), boric acid (BA) (c, d), rhBMP-2 (e, f), and combined BA + rhBMP-2 (g, h) groups at Days 10 and 20 following maxillary first molar extraction. Osteoblasts were identified morphologically by their characteristic location along newly formed bone surfaces and their cuboidal or polygonal appearance. Blue arrows indicate representative osteoblasts. Sections were examined by light microscopy at ×400 magnification.

Osteocalcin expression

Immunohistochemical analysis demonstrated OCN-positive immunoreactivity within osteoblast-associated regions and the extracellular matrix of the healing extraction socket. At Day 10, OCN expression was 10.25 ± 1.28 in the Control group, 13.38 ± 1.06 in the BA group, 17.88 ± 1.13 in the rhBMP-2 group, and 23.13 ± 0.83 in the BA + rhBMP-2 group. At Day 20, OCN expression increased to 18.50 ± 0.76, 24.38 ± 1.69, 30.50 ± 1.69, and 37.88 ± 1.25 in the Control, BA, rhBMP-2, and BA + rhBMP-2 groups, respectively.

The quantitative results of OCN expression at Days 10 and

© 2026 Annals of Dental Specialty. **Open Access** – This Article is licensed under CC BY NC SA 4.0. To view a copy of this license, visit https://creativecommons.org/licenses/by-nc-sa/4.0/

20 are summarized in **Table 2**. The corresponding comparison of OCN expression among the experimental groups is presented in **Figure 1b**.

Table 2. Mean OCN immunohistochemical expression in extraction sockets at Days 10 and 20.

Group	Day 10	Day 20
Control	10.25 ± 1.28	18.50 ± 0.76
Boric acid (BA)	13.38 ± 1.06	24.38 ± 1.69
rhBMP-2	17.88 ± 1.13	30.50 ± 1.69
BA + rhBMP-2	23.13 ± 0.83	37.88 ± 1.25

Data are expressed as mean ± SD (n = 8 animals per group at each time point). The effects of treatment, healing time, and their interaction were analyzed using two-way analysis of variance (ANOVA), followed by Tukey's HSD test for post hoc comparisons of the treatment main effect. Representative immunohistochemical images of OCN expression in the extraction sockets at Days 10 and 20 are shown in **Figure 3**. The staining patterns demonstrate differences in OCN immunoreactivity among the experimental groups, complementing the quantitative findings presented in **Table 2**.

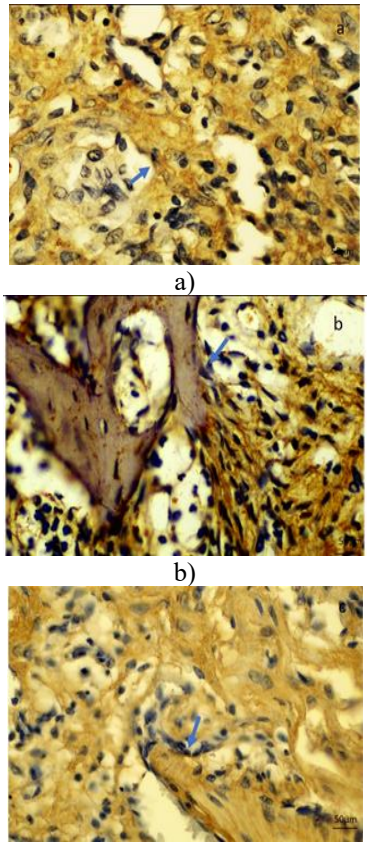

a)

b)

c)

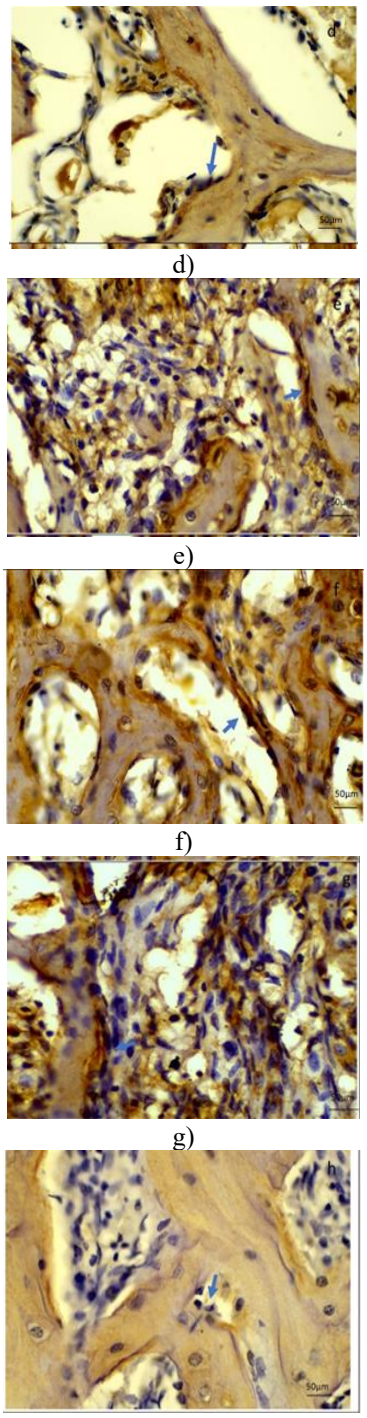

d)

e)

f)

g)

h)

Figure 3. OCN immunohistochemical staining of extraction sockets. Representative immunohistochemical images from the Control (a, b), boric acid (BA) (c, d), rhBMP-2 (e, f), and combined BA + rhBMP-2 (g, h) groups at Days 10 and 20 following maxillary first molar extraction. OCN immunoreactivity is indicated by brown staining, and blue arrows indicate representative OCN-positive cells. Sections were examined by light microscopy at ×400 magnification.

Two-way ANOVA summary

The effects of treatment, healing time, and their interaction on osteoblast number and OCN expression were evaluated using two-way ANOVA. The results are summarized in **Table 3**.

Table 3. Two-way ANOVA evaluating the effects of treatment and healing time on osteoblast number and osteocalcin expression.

Dependent variable	Source	*F*	*p* value	Partial η^2
Osteoblast number	Treatment	743.638	<0.001	0.976
	Healing time	221.101	<0.001	0.798
	Treatment × Time	5.965	0.001	0.242
Osteocalcin expression	Treatment	492.619	<0.001	0.963
	Healing time	1385.353	<0.001	0.961
	Treatment × Time	19.155	<0.001	0.506

Treatment included Control, BA, rhBMP-2, and BA + rhBMP-2 groups, while healing time included Day 10 and Day 20. *F* = *F*-statistic; *p* = probability value; partial η^2 = partial eta squared, indicating the magnitude of the effect attributable to each factor after accounting for the other factor and the interaction. Treatment × Time represents the interaction between treatment and healing time, indicating whether the effect of treatment differed between Day 10 and Day 20. A *p* value <0.05 was considered statistically significant.

As shown in **Table 3**, two-way ANOVA revealed significant main effects of treatment and healing time, as well as significant treatment × time interactions, for both osteoblast number and OCN expression. For osteoblast number, the effects of treatment ($F(3, 56) = 743.638$, $p < 0.001$, partial $\eta^2 = 0.976$), healing time ($F(1, 56) = 221.101$, $p < 0.001$, partial $\eta^2 = 0.798$), and the treatment × time interaction ($F(3, 56) = 5.965$, $p = 0.001$, partial $\eta^2 = 0.242$) were significant. For OCN expression, significant effects were observed for treatment ($F(3, 56) = 492.619$, $p < 0.001$, partial $\eta^2 = 0.963$), healing time ($F(1, 56) = 1385.353$, $p < 0.001$, partial $\eta^2 = 0.961$), and the treatment × time interaction ($F(3, 56) = 19.155$, $p < 0.001$, partial $\eta^2 = 0.506$).

The present study demonstrated that systemic boric acid supplementation enhanced the osteogenic response associated with local rhBMP-2 administration during extraction socket healing following first maxillary molar extraction in Wistar rats. Both osteoblast number and OCN expression were significantly influenced by treatment and healing time, and significant treatment × time interactions were observed for both outcomes.

The most pronounced response was observed in the combined BA + rhBMP-2 group. Osteoblast number in this group was approximately twice that of the Control group at both evaluated time points. Similarly, OCN expression was substantially higher in the combined-treatment group than in the Control group. These results indicate that systemic boric acid supplementation could benefit the biological reaction to a local rhBMP-2 stimulus during extraction socket healing.

The number of osteoblasts and the expression of OCN were higher in the rhBMP-2 group than in the Control group. The results support the known BMP-2 osteogenic property and previous experimental studies showing that the local delivery of rhBMP-2 could increase bone formation in extraction sockets [11-13]. When rhBMP-2 is administered locally, it supplies an osteogenic stimulus directly at the extraction site which can stimulate the recruitment and differentiation of osteogenic cells, and lead to the deposition of bone matrix [14, 15].

The administration of boric acid also resulted in a higher number of osteoblasts and expression of OCN than the control. The result is comparable with that of the earlier experimental work which showed osteoblastic activity after boric acid administration in rats. Boric acid may also influence cellular and nutritional pathways involved in bone metabolism that are likely to impact bone homeostasis [16, 17].

The BA + rhBMP-2 group showed the greatest osteoblast number and OCN expression at both time points. The significant treatment × time interaction for osteoblast number indicates that the magnitude of treatment-related differences varied according to healing time. The interaction was also significant for OCN expression, with a larger effect size ($\eta_p^2 = 0.506$). These findings suggest that systemic boric acid may enhance the osteogenic response associated with local rhBMP-2 administration. However, the underlying biological mechanisms were not directly investigated in this study. rhBMP-2 provides a localized osteogenic stimulus, whereas boric acid may influence the systemic biological environment supporting osteoblastic activity [18, 19].

The simultaneous elevation of osteoblast number and OCN expression provides complementary evidence of increased osteogenic activity. Osteoblast counting provides a cellular measure of bone-forming activity, whereas OCN expression provides information associated with osteoblast differentiation and bone matrix maturation. The consistent pattern observed in the BA + rhBMP-2 group therefore supports the interpretation that the combined intervention enhanced osteogenic activity during socket healing. The number of osteoblasts and OCN expression were significantly increased between Day 10 and Day 20. This temporal progress is similar to the progressive development and maturation of the extraction socket. Based on the strong time effect for OCN, there was significant temporal variation in osteocalcin expression during the healing period assessed. The improvement from Day 10 to Day 20 could be indicative of a more advanced osteogenic/matrix associated stage.

Limitations

There are several limitations to this study: First, this experiment was conducted in Wistar rats, and there are limitations to directly extrapolating to clinical settings due to differences in bone biology between rats and humans. Second, it was only Days 10 and 20 that were assessed, longer follow-up time would allow a more comprehensive assessment of the transition from early osteogenesis to mature bone formation. Third, osteoblast numbers and expression of OCN are surrogate histological and immunohistochemical outcomes, they do not measure directly the bone volume, bone mineral density, trabecular architecture, or mechanical strength. Fourth, the molecular mechanism underlying the enhanced response to combined boric acid and rhBMP-2 treatment was not investigated.

Conclusion

Systemic boric acid supplementation at 50 mg/kg/day enhanced the osteogenic response associated with local rhBMP-2 administration following first maxillary molar extraction in Wistar rats. The combined BA + rhBMP-2 treatment produced the highest osteoblast numbers and OCN expression at both Days 10 and 20. These findings support the potential use of systemic boric acid as an adjunctive approach to enhance rhBMP-2-associated alveolar bone healing. Further studies using micro-computed tomography, histomorphometric analysis, biomechanical testing, dose-response designs, and molecular investigations are warranted to validate these findings and clarify the mechanisms underlying the observed effects.

Acknowledgments: None

Conflict of interest: None

Financial support: None

Ethics statement: All procedures were conducted in accordance with institutional guidelines for the care and use of laboratory animals and were approved by Airlangga University animal ethics committee (Approval No. 0713/HRECC.FODM/VII/2026).

References

1. Udeabor SE, Heselich A, Al-Maawi S, Alqahtani AF, Sader R, Ghanaati S. Current knowledge on the healing of the extraction socket: a narrative review. Bioengineering (Basel). 2023;10(10):1145. doi:10.3390/bioengineering10101145
2. Steiner GG, Francis W, Burrell R, Kallet MP, Steiner DM, Macias R. The healing socket and socket regeneration. Compend Contin Educ Dent. 2008;29(2):114-6, 118, 120-4.
3. Nguyen TD, Nguyen HM, Nguyen TDT, Khuu LM. Optimizing Luc vi capsule integrity: a paraffin oil solution to prevent powder leakage. J Adv Pharm Educ Res. 2025;15(3):28-33. doi:10.51847/cOpzTKumWg
4. Ponzetti M, Rucci N. Osteoblast differentiation and signaling: established concepts and emerging topics. Int J Mol Sci. 2021;22(13):6651. doi:10.3390/ijms22136651
5. Zoch ML, Clemens TL, Riddle RC. New insights into the biology of osteocalcin. Bone. 2016;82:42-9. doi:10.1016/j.bone.2015.05.046
6. Willett NJ, Li MT, Uhrig BA, Boerckel JD, Huebsch N, Lundgren TL, et al. Attenuated human bone morphogenetic protein-2-mediated bone regeneration in a rat model of composite bone and muscle injury. Tissue Eng Part C Methods. 2013;19(4):316-25. doi:10.1089/ten.TEC.2012.0290
7. Freitas RM, Spin-Neto R, Marcantonio Junior E, Pereira LA, Wikesjö UM, Susin C. Alveolar ridge and maxillary sinus augmentation using rhBMP-2: a systematic review. Clin Implant Dent Relat Res. 2015;17(Suppl 1). doi:10.1111/cid.12156
8. Shalehin N, Hosoya A, Takebe H, Hasan MR, Irie K. Boric acid inhibits alveolar bone loss in rat experimental periodontitis through diminished bone resorption and enhanced osteoblast formation. J Dent Sci. 2020;15(4):437-44. doi:10.1016/j.jds.2019.09.009
9. Nielsen FH, Eckhert CD. Boron. Adv Nutr. 2020;11(2):461-2. doi:10.1093/advances/nmz110
10. Toker H, Ozdemir H, Balci Yuce H, Goze F. The effect of boron on alveolar bone loss in osteoporotic rats. J Dent Sci. 2016;11(3):331-7. doi:10.1016/j.jds.2016.03.011
11. Khoswanto C, Dewi IK. The role of rhBMP-2 in mandibular bone regeneration following tooth extraction through HIF-1α and VEGF-A expression: an immunohistochemical study. J Oral Biol Craniofac Res. 2025;15(2):359-64. doi:10.1016/j.jobcr.2025.02.001
12. Krishnan L, Priddy LB, Esancy C, Li MT, Stevens HY, Jiang X, et al. Hydrogel-based delivery of rhBMP-2 improves healing of large bone defects compared with autograft. Clin Orthop Relat Res. 2015;473(9):2885-97. doi:10.1007/s11999-015-4312-z
13. King GN, King N, Cruchley AT, Wozney JM, Hughes FJ. Recombinant human bone morphogenetic protein-2 promotes wound healing in rat periodontal fenestration defects. J Dent Res. 1997;76(8):1460-70. doi:10.1177/00220345970760080801
14. Chernysheva M, Ruchko E, Eremeev A. Optimizing rhBMP-2 therapy for bone regeneration: from safety concerns to biomaterial-guided delivery systems. Int J Mol Sci. 2025;26(21):10723. doi:10.3390/ijms262110723
15. Ghodadra N, Singh K. Recombinant human bone morphogenetic protein-2 in the treatment of bone fractures. Biologics. 2008;2(3):345-54. doi:10.2147/BTT.S3394
16. Sağlam M, Hatipoğlu M, Köseoğlu S, Esen HH, Kelebek S. Boric acid inhibits alveolar bone loss in rats by affecting RANKL and osteoprotegerin expression. J

Periodontal Res. 2014;49(4):472-9. doi:10.1111/jre.12126
17. Demirer S, Kara MI, Erciyas K, Ozdemir H, Ozer H, Ay S. Effects of boric acid on experimental periodontitis and alveolar bone loss in rats. Arch Oral Biol. 2012;57(1):60-5. doi:10.1016/j.archoralbio.2011.07.012
18. Boyne PJ, Lilly LC, Marx RE, Moy PK, Nevins M, Spagnoli DB, et al. De novo bone induction by recombinant human bone morphogenetic protein-2 (rhBMP-2) in maxillary sinus floor augmentation. J Oral Maxillofac Surg. 2005;63(12):1693-707. doi:10.1016/j.joms.2005.08.018
19. Gallardo-Williams MT, Maronpot RR, Turner CH, Johnson CS, Harris MW, Jayo MJ, et al. Effects of boric acid supplementation on bone histomorphometry, metabolism, and biomechanical properties in aged female F-344 rats. Biol Trace Elem Res. 2003;93(1-3):155-70. doi:10.1385/BTER:93:1-3:155