Original Article

THREE-DIMENSIONAL AIRWAY CHANGES FOLLOWING FACEMASK THERAPY WITH RAPID MAXILLARY EXPANSION IN PATIENTS WITH CLEFT LIP AND PALATE: A CBCT-BASED PROSPECTIVE STUDY

Shafees Koya[1], Dilshad Umar[1], Sam Mathew[1], Stanley Selva Kumar[1], Yasmeen Aziz[1]*

[1]*Department of Orthodontics and Dentofacial Orthopaedics, Yenepoya Dental College, Yenepoya (Deemed to be University), Mangalore, Karnataka, India.*
orthodil@gmail.com

Received: 12 March 2026; **Revised:** 20 July 2026; **Accepted:** 21 July 2026 https://doi.org/10.51847/UjaVe0pz9r

ABSTRACT

Cleft lip and palate patients often present with maxillary hypoplasia, transverse constriction, and reduced airway dimensions. Facemask therapy with rapid maxillary expansion is commonly used for maxillary protraction, but its airway effects require three-dimensional assessment. To evaluate pharyngeal airway, skeletal, dental, and soft tissue changes after facemask therapy with arch expansion in cleft lip and palate patients. This prospective interventional study included thirty non-syndromic cleft lip and palate patients with maxillary hypoplasia and constricted arches who underwent Hyrax-type rapid maxillary expansion with facemask therapy for six months. Pre- and post-treatment CBCT scans were used to assess total airway, nasopharyngeal and oropharyngeal dimensions, along with skeletal, dental, and soft tissue parameters. Data were compared using appropriate statistical tests. Significant improvements were observed in total airway, nasopharyngeal, and oropharyngeal measurements. Total airway showed a significant increase from pre- to post-treatment values ($z = -3.411$, $p = 0.001$). Nasopharyngeal and oropharyngeal dimensions also changed significantly ($z = -3.409$ and -2.955, respectively; $p = 0.001$). Skeletal and dental parameters, including SNA, ANB, U1-Pog, U1-SN, and maxillary length, improved after treatment. Soft tissue profile changes were noted in upper lip position and nasolabial angle. Facemask therapy combined with rapid maxillary expansion produced significant improvements in airway dimensions, maxillary skeletal position, dental relationships, and soft tissue profile in cleft lip and palate patients.

Key words: Cleft lip and palate, Facemask therapy, Rapid maxillary expansion, Hyrax, Pharyngeal airway, CBCT.

Introduction

Cleft lip and palate is one of the most common congenital craniofacial anomalies and is frequently associated with disturbances in maxillary growth, dental arch constriction, altered facial profile, and compromised airway function [1-3]. Growth restriction of the maxilla in these patients is often attributed to the combined influence of intrinsic developmental deficiency and scar tissue from early surgical repair [4-8]. As a result, many patients develop maxillary hypoplasia, anterior or posterior crossbite, and a skeletal Class III relationship, which may affect mastication, speech, facial esthetics, and respiration [9-11].

The pharyngeal airway is closely related to craniofacial morphology. In patients with cleft lip and palate, reduced nasopharyngeal and oropharyngeal dimensions may contribute to mouth breathing, altered tongue posture, speech abnormalities, and increased susceptibility to sleep-disordered breathing [12-16]. Since the airway is anatomically bordered by the jaws, cranial base, cervical spine, and surrounding soft tissues, orthopedic changes in maxillary position may influence airway patency [17]. Therefore, airway assessment has become an important component of diagnosis and treatment evaluation in cleft orthodontics.

Rapid maxillary expansion is commonly used to correct transverse maxillary deficiency, while facemask therapy is employed to protract the deficient maxilla in growing patients. The combination of maxillary expansion and protraction may loosen circummaxillary sutures, facilitate forward displacement of the maxilla, improve skeletal sagittal relationships, and enhance the soft tissue profile [18-20]. Although these orthopedic effects are well established, their influence on pharyngeal airway dimensions in cleft patients remains less clearly defined.

Cone-beam computed tomography provides a three-dimensional method for evaluating craniofacial structures and airway volume with greater spatial accuracy than conventional two-dimensional cephalometry. It enables volumetric assessment of the nasopharyngeal and oropharyngeal airway compartments and allows simultaneous evaluation of skeletal, dental, and soft tissue changes [21-24]. This study aimed to assess pre- and post-treatment changes in airway dimensions among patients with cleft lip and palate treated with facemask therapy combined with arch expansion. The study also evaluated associated skeletal, dental, and soft tissue changes to determine the broader craniofacial effects of this orthopedic treatment approach.

Materials and Methods

© 2026 Annals of Dental Specialty. **Open Access** – This Article is licensed under CC BY NC SA 4.0. To view a copy of this license, visit https://creativecommons.org/licenses/by-nc-sa/4.0/

This prospective interventional study was conducted in the Department of Orthodontics and Dentofacial Orthopaedics. The study sample consisted of 30 growing patients diagnosed with non-syndromic cleft lip and palate who presented with maxillary hypoplasia and transverse maxillary arch constriction. Patients with a history of facial trauma, previous tonsillectomy or adenoidectomy, or regular medication intake were excluded from the study. Ethical approval for this study was obtained from the Institutional Ethics Committee of Yenepoya Dental College, Yenepoya (Deemed to be University) before commencement of the study (Approval No: YEC-1/2023/146). Written informed consent was obtained from all participants or their guardians prior to participation..

The sample size was estimated based on the primary outcome variable, namely change in pharyngeal airway dimension following treatment. A pilot evaluation was initially performed on 10 patients to estimate the treatment-related change in total airway dimension. Based on the mean pre- and post-treatment difference observed in the pilot sample, the calculated effect size was large. Considering a paired study design, 5% level of significance, and 80% statistical power, the minimum required sample size was estimated to be approximately 24 participants. To compensate for possible incomplete follow-up or unusable CBCT records, the final sample size was increased to 30 patients. Considering a 5% level of significance, 80% power, and a paired pre–post study design, the minimum required sample size was estimated to be approximately 24 participants. After accounting for possible attrition, incomplete follow-up, or unusable radiographic records, a final sample size of 30 patients was considered adequate. Therefore, the inclusion of 30 patients provided sufficient statistical power to detect within-group treatment-related changes in pharyngeal airway dimensions.

All patients underwent maxillary arch expansion using a Hyrax appliance followed by facemask therapy. The Hyrax appliance was fabricated on the maxillary dental cast and banded to the premolars and molars. Expansion was performed using a standardized activation protocol according to the degree of maxillary constriction and patient tolerance. Following expansion, reverse-pull facemask therapy was initiated using elastics attached from the intraoral appliance to the facemask. Patients were instructed to wear the facemask for 12–16 hours per day for six months **(Figure 1)**.

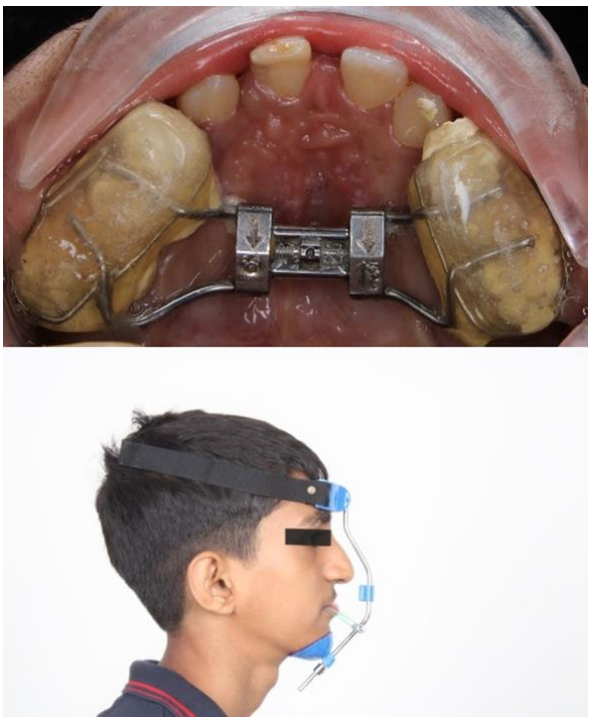

Figure 1. Facemask therapy with maxillary arch expansion used for correction of maxillary deficiency in cleft lip and palate patients

Cone-beam computed tomography scans were obtained before treatment and after six months of therapy using the Planmeca ProMax® 3D Mid CBCT unit. During image acquisition, patients were positioned with the teeth in maximum intercuspation and were instructed to remain still, avoiding head or tongue movement. The images were exported in DICOM format and analyzed using Planmeca Romexis® software.

Volumetric pharyngeal airway assessment was performed on pre- and post-treatment CBCT scans. The airway was divided into nasopharyngeal and oropharyngeal compartments using reproducible anatomical landmarks. The posterior boundary was defined by the posterior pharyngeal wall, and the inferior limit was extended to the most caudal medial projection of the third cervical vertebra. The anterior boundary was defined by a vertical reference plane passing through the intersection of the sella–nasion plane and the sagittal plane at the lowest border of the vomer. This boundary was modified where necessary to accommodate variation in posterior nasal spine position among cleft patients.

Skeletal, dental, and soft tissue parameters were also measured on the pre- and post-treatment records. The primary outcome was change in pharyngeal airway dimension, while secondary outcomes included changes in skeletal, dental, and soft tissue measurements. Data were tabulated and statistically analyzed. Data distribution was assessed using the Kolmogorov–Smirnov and Shapiro–Wilk tests. Normally distributed continuous variables were

analyzed using the paired t-test and expressed as mean ± standard deviation (SD). Non-normally distributed variables were analyzed using the Wilcoxon signed-rank test and expressed as median with interquartile range (IQR). The level of statistical significance was set at $p < 0.05$.

Results and Discussion

The study included 30 patients with cleft lip and palate who underwent facemask therapy with maxillary arch expansion. The mean age of the study participants was 10.67 ± 1.17 years. Of the total sample, 14 were males and 16 were females **(Table 1)**.

Table 1. Demographic and clinical characteristics of the study sample

Variable	Value
Total sample size	30
Mean age, years	10.67 ± 1.17
Male	14
Female	16
Study design	Pre–post CBCT evaluation
Treatment duration	6 months
Appliance protocol	Hyrax expansion with facemask therapy

Pre- and post-treatment CBCT records were evaluated for airway, skeletal, dental, and soft tissue changes. Airway parameters (nasopharyngeal airway, oropharyngeal airway, and total airway) demonstrated non-normal distribution and were analyzed using the Wilcoxon signed-rank test. Skeletal and dental parameters showing normal distribution were analyzed using the paired t-test, while non-normally distributed skeletal, dental, and soft tissue parameters were analyzed using the Wilcoxon signed-rank test. Normality of the data was assessed using the Kolmogorov–Smirnov and Shapiro–Wilk tests. Parameters showing normal distribution were analyzed using parametric tests, while skewed variables were analyzed using non-parametric tests.

Airway changes

Comparison of pre- and post-treatment airway measurements demonstrated statistically significant changes following facemask therapy with expansion. For the nasopharyngeal airway, the median value remained 3 mm before and after treatment; however, the distribution of paired measurements showed significant changes. The Wilcoxon signed-rank test demonstrated a statistically significant difference between pre- and post-treatment values ($z = -3.409$, $p = 0.001$). The median values are presented along with interquartile ranges (IQR) to describe the variability within the dataset This indicates that although the median value did not change, individual patient measurements showed consistent treatment-related variation.

The oropharyngeal airway demonstrated a statistically significant change after treatment. Although the median value remained 9 mm at both pre- and post-treatment intervals, the paired distribution showed significant variation. The Wilcoxon signed-rank test demonstrated a significant difference between treatment intervals ($z = -2.955$, $p = 0.001$), with IQR values added to demonstrate data dispersion. Despite this unchanged median, the Wilcoxon signed-rank test showed a significant difference, with $z = -2.955$ and $p = 0.001$. This suggests that facemask therapy with expansion produced measurable individual-level changes in the oropharyngeal airway **(Figure 2)**.

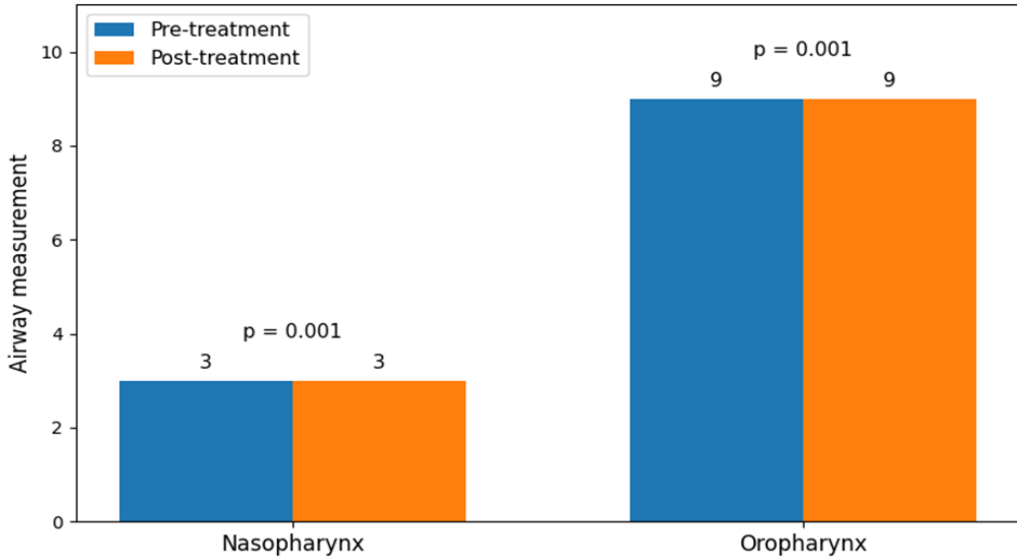

Figure 2. Pre- and post-treatment comparison of nasopharyngeal and oropharyngeal airway measurements.

Total airway measurements showed a clear post-treatment improvement. The median total airway value increased from 205 before treatment to 211 after treatment **(Figure 3)**.

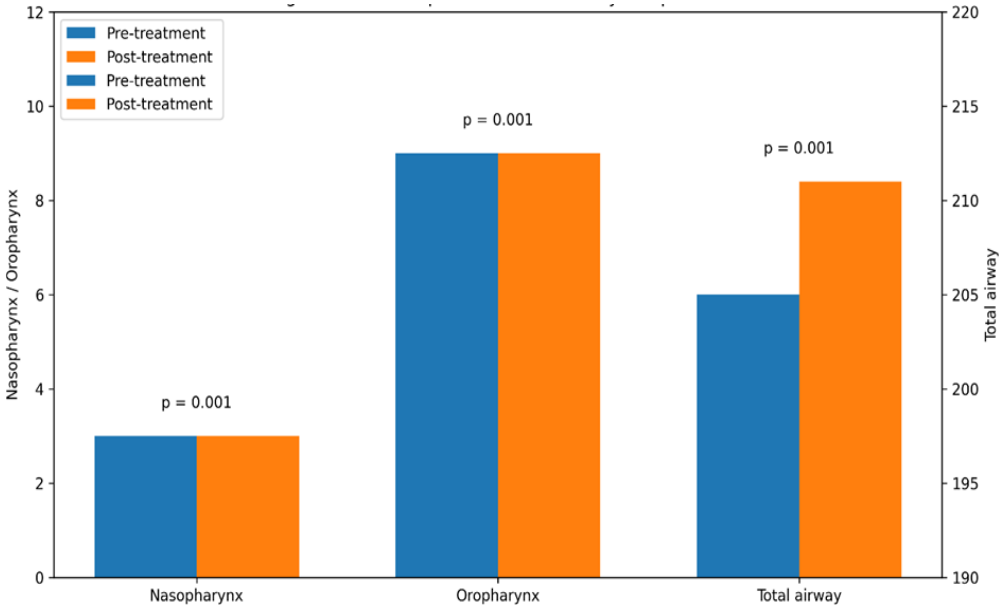

Figure 3. Pre- and post-treatment comparison of pharyngeal airway measurements.

This change was statistically significant, with a Wilcoxon z-value of -3.411 and p = 0.001 **(Figure 4)**.

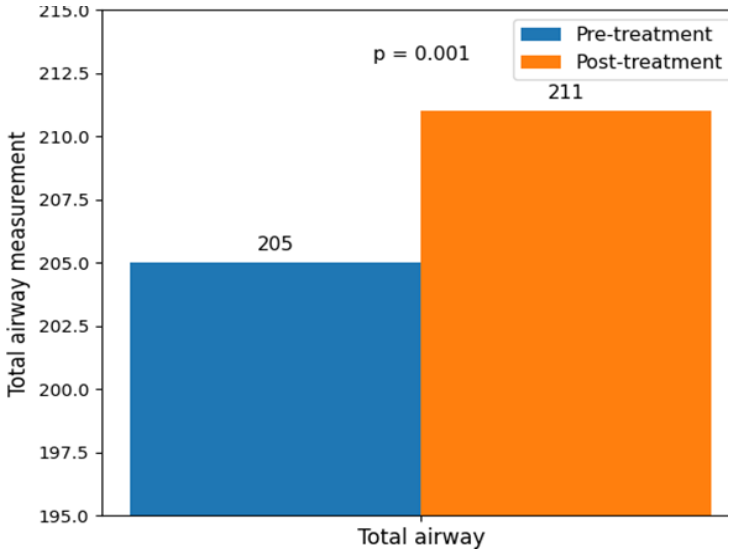

Figure 4. Pre- and post-treatment comparison of total airway measurement.

The increase in total airway measurement indicates a favorable effect of the treatment protocol on overall upper airway dimensions **(Table 2)**.

Table 2. Pre- and post-treatment airway changes

Parameter	N	Pre-treatment (IQR)	Post-treatment (IQR)	z-value	p-value
Nasopharynx, mm	30	3	3	Z = -3.409	0.001*
Oropharynx, mm	30	9	9	Z = -2.955	0.001*
Total airway	30	205	211	Z = -3.411	0.001*

Values are expressed as mean ± standard deviation (SD) for normally distributed variables and median (interquartile range, IQR) for non-normally distributed variables.

Skeletal and dental changes

Significant skeletal changes were observed following treatment. The ANB angle decreased from a pre-treatment median of 2.02° to a post-treatment median of 1.09°. This change was statistically significant, with a z-value of 3.30 and p = 0.001. The reduction in ANB angle indicates an improvement in the sagittal maxillomandibular relationship after treatment.

The SNA angle showed a significant increase after treatment. The median SNA value increased from 79° before treatment to 81° after treatment, with a z-value of 3.35 and p = 0.001. This finding indicates anterior displacement of the maxilla following facemask therapy and supports the skeletal protraction effect of the appliance protocol.

Dental measurements also showed significant post-treatment changes. The U1-Pog distance increased from 0.99 ± 0.50 mm before treatment to 2.19 ± 0.63 mm after treatment. The mean difference was 1.20 mm, and the change was statistically significant, with t = 7.72 and p = 0.001. This indicates forward positioning of the maxillary incisors relative to pogonion following therapy.

Maxillary length increased significantly after treatment. The mean maxillary length increased from 80.29 ± 1.77 mm pre-treatment to 82.86 ± 1.66 mm post-treatment, with a mean difference of 2.57 mm. This change was statistically significant, with t = 11.30 and p = 0.001. The increase in maxillary length reflects a favorable skeletal response to the combined expansion and protraction protocol.

The U1-SN angle also increased significantly after treatment. The median value increased from 82.5° before treatment to 84.5° after treatment. The Wilcoxon signed-rank test showed z = 3.32 and p = 0.001, indicating significant proclination of the maxillary incisors following treatment **(Table 3)**.

Table 3. Pre- and post-treatment skeletal and dental changes

Parameter	Pre-treatment	Post-treatment	Mean/Median difference	Test statistic	p-value
SNA°	79	81	-	Z = 3.35	0.001*
ANB °	2.02	1.09	-	Z = 3.30	0.001*
U1-Pog mm	0.99 ± 0.50	2.19 ± 0.63	1.20	t = 7.72	0.001*
U1-SN°	82.5	84.5	—	Z = 3.32	0.001*
Maxillary length mm	80.29 ± 1.77	82.86 ± 1.66	2.57	t = 11.30	0.001*

Data are presented as median (interquartile range [IQR]) for non-normally distributed variables and mean ± standard deviation (SD) for normally distributed variables. The Wilcoxon signed-rank test was used for non-normally distributed variables, and the paired t-test was used for normally distributed variables. $p < 0.05$ was considered statistically significant.

Soft tissue changes

Soft tissue parameters showed significant changes following treatment. The upper lip position relative to the E-line changed from a median of -2 mm before treatment to -6.5 mm after treatment. This change was statistically significant, with z = 3.32 and p = 0.001. The finding indicates a posterior repositioning of the upper lip relative to the esthetic reference line, suggesting an improvement in facial soft tissue balance.

The nasolabial angle showed a slight reduction after treatment, decreasing from 102.29° to 100.50°. This change suggests alteration in the relationship between the upper lip and nose following maxillary expansion and protraction. The change was reported as statistically significant and indicates measurable soft tissue adaptation after therapy.

Overall, facemask therapy combined with maxillary arch expansion produced statistically significant changes in total airway, nasopharyngeal and oropharyngeal airway measurements, skeletal maxillary position, maxillary length, incisor position, and selected soft tissue parameters. The most notable changes were observed in total airway dimension, SNA, ANB, U1-Pog, maxillary length, U1-SN, upper lip to E-line, and nasolabial angle. These findings indicate favorable short-term airway, skeletal, dental, and soft tissue responses following treatment in patients with cleft lip and palate **(Table 4)**.

Table 4. Pre- and post-treatment soft tissue changes

Parameter	Pre-treatment	Post-treatment	Test statistic	p-value
Upper lip to E-line, mm	-2	-6.5	Z = 3.32	0.001*
Nasolabial angle, °	102.29	100.50	—	Significant*

The present CBCT-based study evaluated changes in pharyngeal airway dimensions and craniofacial parameters following facemask therapy combined with maxillary arch expansion in patients with cleft lip and palate. The main finding was a statistically significant improvement in total airway, nasopharyngeal, and oropharyngeal dimensions after treatment. These airway changes were associated with favorable skeletal, dental, and soft tissue changes,

particularly in SNA, ANB, maxillary length, maxillary incisor inclination, nasolabial angle, and upper lip position. These findings suggest that orthopedic maxillary protraction in cleft patients may have functional benefits beyond sagittal skeletal correction.

Patients with cleft lip and palate frequently demonstrate maxillary hypoplasia, transverse arch deficiency, anterior crossbite, and altered pharyngeal airway morphology. MacLean *et al*. reported that children with cleft lip and/or palate have an increased risk of sleep-disordered breathing because of craniofacial restriction, altered palatal function, and reduced upper airway dimensions [15]. Similarly, Celikoglu *et al*. found that patients with unilateral cleft lip and palate had significantly smaller oropharyngeal airway volumes than non-cleft controls, emphasizing the importance of airway evaluation in this group [25]. The present findings are consistent with these observations, as the pretreatment airway dimensions reflected the compromised airway morphology often seen in cleft patients.

The significant increase in total airway dimension observed in the present study may be attributed to the combined effects of maxillary expansion and facemask therapy. Rapid maxillary expansion is known to influence the nasal cavity and circummaxillary structures, while facemask therapy produces anterior displacement of the maxilla. Tindlund *et al*. reported that orthopedic protraction in cleft patients produced improvement in the sagittal maxillomandibular relationship, mainly through anterior repositioning of the maxilla and clockwise rotation of the mandible [26]. Buschang *et al*. also observed significant protraction of the maxilla in patients with unilateral cleft lip and palate treated with maxillary expansion and protraction appliances [27]. The skeletal changes noted in the present study, particularly the increase in SNA and maxillary length, support these earlier findings.

The nasopharyngeal airway showed a statistically significant post-treatment change. This finding is clinically relevant because the nasopharynx is closely related to the maxilla, nasal cavity, and soft palate. Forward displacement of the maxilla may increase the anteroposterior space in the upper pharyngeal region and improve the relationship between the soft palate and posterior pharyngeal wall. The present result agrees with this conclusion and supports the view that maxillary protraction may positively influence the upper airway in growing cleft patients.

A significant change was also observed in the oropharyngeal airway. This finding is noteworthy because previous studies have reported variable effects of facemask therapy on the lower pharyngeal airway. Alswairki HJ *et al*. noted that although upper pharyngeal measurements improved after facemask therapy, changes in the oropharyngeal region were less consistent [28]. In contrast, the present study demonstrated a significant oropharyngeal change. This difference may be explained by variation in age, cleft morphology, treatment protocol, compliance, growth pattern, and three-dimensional segmentation methods. It is also possible that maxillary advancement improved tongue posture and soft palate orientation, indirectly affecting the oropharyngeal space.

The skeletal response observed in the present study is consistent with previous reports on maxillary protraction. Siddiqui HP *et al*. reported that extraoral traction with facemask therapy in cleft and non-cleft patients produced correction of negative overjet through a combination of anterior maxillary displacement, mandibular positional change, and incisor movement [29]. Tindlund *et al*. found that early orthopedic treatment in cleft patients improved ANB angle and corrected anterior crossbite. Williams *et al*. similarly reported that rapid maxillary expansion combined with maxillary protraction produced anterior maxillary movement and correction of Class III malocclusion in growing children [30]. The significant increase in SNA and improvement in ANB in the present study are in agreement with these findings.

The increase in maxillary length further supports the orthopedic effect of the treatment protocol. Liou *et al*. reported greater maxillary advancement when alternate expansion and constriction protocols were combined with protraction mechanics, suggesting that expansion may enhance circummaxillary suture response. Although the present study used Hyrax expansion rather than an Alt-RAMEC protocol, the principle of sutural loosening before protraction remains relevant. The significant skeletal change observed after six months indicates that facemask therapy combined with expansion can produce measurable maxillary advancement in growing cleft patients.

Dental changes were also evident after treatment. The increase in U1-SN and U1 to A-Pog suggests proclination and forward movement of the maxillary incisors. This finding is expected, as facemask therapy often produces a combination of skeletal and dentoalveolar effects. Williams *et al*. reported that maxillary protraction therapy resulted not only in forward movement of the maxilla but also in anterior movement and proclination of maxillary incisors. Similarly, Siddiqui HP *et al*. observed that correction of overjet following facemask therapy was partly due to incisor tipping. Therefore, the dental findings of the present study are consistent with the known biomechanical effects of facemask therapy.

Soft tissue changes observed in this study further demonstrate the clinical impact of maxillary protraction. The significant change in nasolabial angle and upper lip position indicates adaptation of the facial soft tissue profile following skeletal advancement. Palikaraki G *et al*. reported significant improvement in soft tissue profile in patients with unilateral complete cleft lip and palate treated with reverse headgear, with reduction in facial concavity and

improvement in lip relationship [31]. The present study supports these findings, suggesting that facemask therapy can enhance facial profile in cleft patients by improving midfacial support.

The use of CBCT is an important strength of the present study. Two-dimensional cephalometry has traditionally been used to evaluate airway and craniofacial changes, but it cannot accurately represent volumetric airway changes. Xu *et al*. emphasized the value of CBCT in assessing three-dimensional pharyngeal airway morphology in cleft patients [32]. Celikoglu *et al*. also used CBCT to compare airway volumes in cleft and non-cleft individuals and demonstrated its usefulness in detecting regional airway differences [32]. In the present study, CBCT enabled separate assessment of nasopharyngeal, oropharyngeal, and total airway changes, providing a more comprehensive evaluation than conventional lateral cephalograms.

Despite these findings, certain limitations must be considered. The sample size was limited, although adequate to detect the observed within-group treatment effect. Despite these findings, certain limitations should be considered. The absence of an untreated control group represents an important limitation, as the observed changes may include contributions from both treatment effects and normal craniofacial growth during the observation period. Therefore, the results should be interpreted as short-term changes associated with facemask therapy combined with maxillary expansion rather than definitive treatment effects alone. Future studies incorporating age-matched untreated control groups or alternative comparative designs are required to further validate the specific contribution of the intervention to airway and craniofacial changes. Individual variation in cleft type, surgical history, scar tissue, airway anatomy, and facemask compliance may also have influenced treatment response. Furthermore, the study evaluated short-term changes after six months, and long-term follow-up is required to assess the stability of airway and skeletal improvements.

Within these limitations, the present study suggests that facemask therapy combined with maxillary expansion produces favorable short-term changes in airway dimensions, skeletal relationship, dental position, and soft tissue profile in patients with cleft lip and palate. The findings are in agreement with previous studies by Tindlund *et al*., Buschang *et al*., Chen *et al*., Celikoglu *et al*., while also adding CBCT-based evidence on airway response in cleft patients. Early orthopedic intervention in growing cleft patients may therefore be considered not only for correction of maxillary deficiency and crossbite, but also for its potential contribution to improved upper airway morphology.

Conclusion

Facemask therapy combined with maxillary arch expansion was associated with significant short-term improvements in pharyngeal airway dimensions in patients with cleft lip and palate. However, interpretation should consider the absence of an untreated control group and the potential influence of growth-related changes. The increase in total airway, nasopharyngeal, and oropharyngeal measurements suggests that orthopedic advancement of the maxilla may positively influence upper airway morphology in this patient group.The treatment also resulted in favorable skeletal and dental changes, including improvement in maxillary position, sagittal jaw relationship, maxillary length, and upper incisor inclination. Soft tissue adaptations were observed in the nasolabial angle and upper lip position, indicating improvement in facial profile following maxillary protraction.

Early facemask therapy with expansion may be beneficial not only for correction of maxillary deficiency and Class III tendency in cleft patients, but also for enhancing upper airway dimensions. Larger controlled studies with long-term follow-up are required to confirm the stability and clinical significance of these changes.

Acknowledgments: The authors would like to express their sincere gratitude to the institution, faculty members, guides, and all individuals who provided support, guidance, and encouragement throughout the completion of this work.

Conflict of interest: None

Financial support: None

Ethics statement: None

References

1. Paradowska-Stolarz A, Mikulewicz M, Duś-Ilnicka I. Current concepts and challenges in the treatment of cleft lip and palate patients—a comprehensive review. J Pers Med. 2022;12(12):2089.
2. Vyas T, Gupta P, Kumar S, Gupta R, Gupta T, Singh HP. Cleft of lip and palate: a review. J Family Med Prim Care. 2020;9(6):2621-5.
3. Farronato G, Cannalire P, Martinelli G, Tubertini I, Giannini L, Galbiati G, et al. Cleft lip and/or palate. Minerva Stomatol. 2014;63(4):111-26.
4. Friede H. Growth sites and growth mechanisms at risk in cleft lip and palate. Acta Odontol Scand. 1998;56(6):346-51.
5. Yang J, Tang Z, Shan Z, Leung YY. Maxillary deficiency: treatments and applications for adolescents. Appl Sci. 2025;15(6):3256.
6. Capote R, Preston K, Kapadia H. Craniofacial growth and development: a primer for the facial trauma surgeon. Oral Maxillofac Surg Clin North Am. 2023;35(4):501-13.
7. Corthouts P, Boels F, Van de Casteele E, Nadjmi N. Effects of various surgical protocols on maxillofacial

growth in patients with unilateral cleft lip and palate: a systematic review. Plast Aesthet Res. 2020;7.
8. Roy AA, Rtshiladze MA, Stevens K, Phillips J. Orthognathic surgery for patients with cleft lip and palate. Clin Plast Surg. 2019;46(2):157-71.
9. Rashid A, Jahangir U, Akram ME, Aamir N, Ansar Z, Akram E, et al. Impact of dental anomalies on function and aesthetics in cleft lip and palate patients. Link Med J. 2025:e38-.
10. Schechter J, Shetye PR. Orthodontic treatment of patients with cleft lip and palate from birth through maturity. Semin Orthod. 2024.
11. Long RE Jr, Semb G, Shaw WC. Orthodontic treatment of the patient with complete clefts of lip, alveolus, and palate: lessons of the past 60 years. Cleft Palate Craniofac J. 2000;37(6):1-3.
12. Kim KA, Kim SJ, Yoon A. Craniofacial anatomical determinants of pediatric sleep-disordered breathing: a comprehensive review. J Prosthodont. 2025;34(Suppl 1):26-34.
13. Brennan LC, Kirkham FJ, Gavlak JC. Sleep-disordered breathing and comorbidities: role of the upper airway and craniofacial skeleton. Nat Sci Sleep. 2020:907-36.
14. Shaz A, Umar D, Shetty N, Shetty S, Husain A, Koya S. Analysis of skeletal and airway changes following anterior maxillary distraction in cleft patients: a CBCT study. Iran J Orthod. 2025;20(1):1-11. doi:10.32592/ijorth.20.1.1200
15. MacLean JE, Hayward P, Fitzgerald DA, Waters K. Cleft lip and/or palate and breathing during sleep. Sleep Med Rev. 2009;13(5):345-54.
16. Tan HL, Kheirandish-Gozal L, Abel F, Gozal D. Craniofacial syndromes and sleep-related breathing disorders. Sleep Med Rev. 2016;27:74-88.
17. Kang YJ, Toh ST, Chiba S, Lin CCH, Park CS. Airway anatomy and surgical management in obstructive sleep apnea. Clin Exp Otorhinolaryngol [Internet]. 2026 Aug 31 [cited 2026 Sep 30];19(3):211-23.
18. Bazargani F, Feldmann I, Bondemark L. Three-dimensional analysis of effects of rapid maxillary expansion on facial sutures and bones: a systematic review. Angle Orthod. 2013;83(6):1074-82.
19. Gautam R, Deshmukh S, Rahalkar J, Chakravarty S. Skeletally anchored maxillary expansion—a current consensus. J Indian Orthod Soc. 2026:03015742251405639.
20. Shahroudi AS, Pourcheraghi M, Mirhashemi A, Dizna FA. Application of skeletal anchorage devices in growth modification treatments: a literature review. Int J Multiphysics. 2024;18(4).
21. Eslami E, Katz ES, Baghdady M, Abramovitch K, Masoud MI. Are three-dimensional airway evaluations obtained through computed and cone-beam computed tomography scans predictable from lateral cephalograms? A systematic review of evidence. Angle Orthod. 2017;87(1):159-67.
22. Scarfe WC, Azevedo B, Toghyani S, Farman AG. Cone beam computed tomographic imaging in orthodontics. Aust Dent J. 2017;62:33-50.
23. Chan HJ, Woods M, Stella D. Three-dimensional computed craniofacial tomography (3D-CT): potential uses and limitations. Aust Orthod J. 2007;23(1):55-64.
24. Steegman R, Hogeveen F, Schoeman A, Ren Y. Cone beam computed tomography volumetric airway changes after orthognathic surgery: a systematic review. Int J Oral Maxillofac Surg. 2023;52(1):60-71.
25. Celikoglu M, Buyuk SK, Sekerci AE, Ucar FI, Cantekin K. Three-dimensional evaluation of the pharyngeal airway volumes in patients affected by unilateral cleft lip and palate. Am J Orthod Dentofacial Orthop. 2014;145(6):780-6.
26. Tindlund RS. Skeletal response to maxillary protraction in patients with cleft lip and palate before age 10 years. Cleft Palate Craniofac J. 1994;31(4):295-308.
27. Buschang PH, Porter C, Genecov E, Genecov D, Sayler KE. Face mask therapy of preadolescents with unilateral cleft lip and palate. Angle Orthod. 1994;64(2):145-50.
28. Alswairki HJ, Alam MK, Rahman SA, Alsuwailem R, Alanazi SH. Upper airway changes in diverse orthodontic looms: a systematic review and meta-analysis. Appl Sci. 2022;12(2):916.
29. Siddiqui HP, Kuijpers-Jagtman AM, Sennimalai K, Meazzini MC, Selvaraj M, Machawal J. Effects of maxillary protraction techniques on maxillofacial, dental, and soft tissue outcomes in patients with non-syndromic unilateral cleft lip and palate: a systematic review and meta-analysis. Orthod Craniofac Res. 2025;28(6):885-906.
30. Williams MD, Sarver DM, Sadowsky PL, Bradley E. Combined rapid maxillary expansion and protraction facemask in the treatment of Class III malocclusions in growing children: a prospective long-term study. Semin Orthod. 1997;3(4):265-74.
31. Palikaraki G, Makrygiannakis MA, Zafeiriadis AA, Benetou V, Sanoudos M, Bitsanis I, et al. The effect of facemask in patients with unilateral cleft lip and palate: a systematic review and meta-analysis. Eur J Orthod. 2021;43(1):69-79.
32. Xu Y, Zhao S, Shi J, Wang Y, Shi B, Zheng Q, et al. 3-dimensional computed tomographic analysis of the pharynx in adult patients with unrepaired isolated cleft palate. J Oral Maxillofac Surg. 2013;71(8):1424-34.