

# DIGITAL TELESCOPIC DENTURE- A VIABLE TREATMENT MODALITY OF PREVENTIVE PROSTHODONTICS: CLINICAL REPORT

Subhabrata Maiti<sup>1\*</sup>, Nitesh Rai<sup>2</sup>, Ponnanna Appanna<sup>2</sup>, Jessy P<sup>3</sup>

<sup>1</sup>Department of Prosthodontics, Saveetha Dental College and Hospitals, Saveetha Institute of Medical and Technical Sciences, Saveetha University, Chennai -77, Tamil Nadu, India. drsubhprosth@gmail.com

<sup>2</sup>Department of Prosthodontics, Krishnadevaraya College of Dental Science and Hospital, Bangalore, Karnataka, India.

<sup>3</sup>Department of Pedodontics, Saveetha Dental College and Hospitals, Saveetha Institute of Medical and Technical Sciences, Saveetha University, Chennai -77, Tamil Nadu, India.

<https://doi.org/10.51847/eEgU10vYgd>

## ABSTRACT

A telescopic denture is considered a good alternative to the conventional removable dentures as they provide better retention, stability, support, stable occlusion, decrease in the forward sliding of the prosthesis, and better control of the mandibular movements because of the proprioception feedback which increases the chewing efficiency. Well, fabricated prosthesis with good clinical and laboratory expertise and maintained with excellent care can be a successful one. The fabrication technique using advanced digital software will eliminate manual error and can make a fast technology-developed digital prosthesis. The goal of this article was to describe the importance of saving the natural remaining teeth and the fabrication of digital telescopic dentures using subtractive milling and additive 3D printing (DMLS) technology and the application of dissimilar material for a friction fit, as an alternative to the conventional prosthesis.

**Key words:** Telescopic denture, Digital dentistry, Over denture, CAD CAM, Digital denture, Innovation.

## Introduction

The telescopic overdenture is a logical method to use in preventive prosthodontics as it plays an important role in the preservation of alveolar bone and the periodontal sensory mechanisms that guide and monitor gnatho dynamic functions [1]. The unique principle of friction fit only when they are completely seated by using a “wedging effect” made the prosthesis with high expectations [2]. This type of restoration in patients with terminal dentition allows for reducing destructive rotational and horizontal occlusal forces by directing them more axially. The quality of the prosthesis is increasing and the time taken for fabrication is decreasing day by day as we are in the era of digital dentistry. Proper handling of 3D design software and manufacturing technology (3D printing /DMLS, Milling) can reduce manual error, the demand for highly experienced technicians, and the wastage of material.

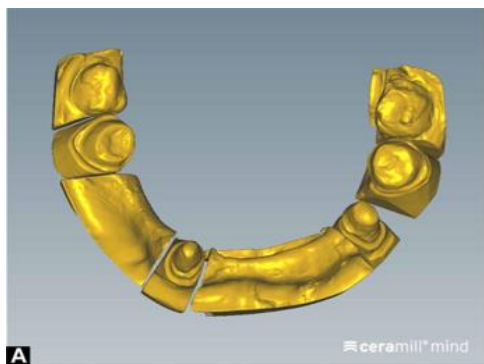## Case report

A 45-year-old female patient was reported to the hospital in Bangalore, with the chief complaint of difficulty in chewing, speech, and poor esthetics. The preliminary examination revealed that the teeth missing in the mandibular arch were 31,32,34,35,36,41,42,43,45,46 with a dentulous maxillary arch with previous existing metal-ceramic crowns. The edentulous span had a narrow knife edge ridge. A diagnostic cast was prepared and articulated following bite registration after intraoral examination and radiographic investigation. Considering the density and the width of the available bone


through CBCT (cone beam computed tomography), an implant-supported prosthesis was eliminated as a treatment option for the patient. Also the patient was reluctant to undergo any surgical procedure hence telescopic denture was chosen as a favorable treatment of choice. Diagnostic mounting revealed a class II malocclusion with unilateral crossbite with reduced vertical dimension. To establish a telescopic denture prosthesis vertical dimension of around 3mm more was needed and it was assessed by measuring extraoral anatomical landmarks (outer canthus to modulus and base of the nose to base of the chin) and facial expression during rest and occlusion. After oral prophylaxis of abutment teeth, an interim treatment acrylic partial denture was given to the patient to restore the vertical dimension at 1mm progressively each week taking the reference point of natural opposing dentition. After six weeks, the patient was very comfortable as her complete stomatognathic system was accustomed to the 3mm established vertical dimension.

Tooth preparation was done for digitally planned milled zirconia primary copings on 33,37,44 and 47. Single stage Putty relining technique using additional silicon (3M ESPE), and an initial master model was prepared for laboratory scanning, and through digital wax-up and designing, the primary coping was obtained virtually in 3D CAD software (**Figure 1**). Primary Zirconia copings, planned in CAD software were fabricated on the four abutment teeth and were made parallel to each other with two-degree tapering in order to create a single path of insertion. The copings were tried along with their relationship to each other using a fit checker

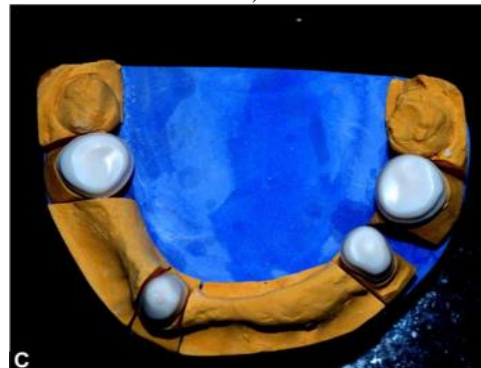
(GC) and radiograph (RVG). Once the accuracy was confirmed, the primary zirconia copings were temporarily stabilized using non-Eugenol cement (GC) and an over impression was made (monophase DENTSPLY) in a special tray and a second master model was obtained. This model served to be used for scanning for fabrication of the cast partial superstructure. The model along with primary coping was scanned to make the master cast for secondary coping and framework. Secondary coping along with extension( for the attachment with framework) was designed in the 3D designing software (**Figure 2**). The framework was designed virtually in the software and fabricated digitally using CAD-CAM (computer-aided design and computer-aided machining); DMLS (Direct Metal Laser sintering) technology for framework and the 3D milling technology for secondary coping in order to achieve satisfactory friction lock retention. Secondary coping and the framework was welded after proper fit Checking in the patient mouth. With the help of a metal framework the jaw relation was done in a restored vertical dimension, teeth were selected, and indirect composite resin was layered on secondary metal copings attached to the framework. In the next appointment, a try-in was done to verify prosthetic fit, esthetics, phonetics, and occlusal interferences. Acrylization was done and the labial surface of the prosthesis was layered with indirect gingival composite to maintain a pink and white esthetic score (**Figure 3**). Final prosthesis along with the primary coping was placed in the patient's mouth using Glass ionomer cement (GC) for the cementation of the primary coping. Post insertion 24 hours, the patient was recalled and excess cement was removed and proper instruction and follow-up was explained. Patient quality of life was improved a lot which was assessed by using questionnaire-based quality of life scale and that was the real success of the clinician.



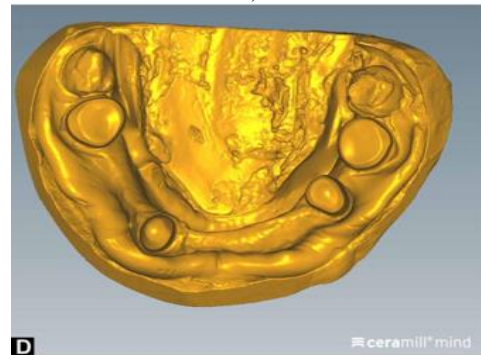
a)



b)

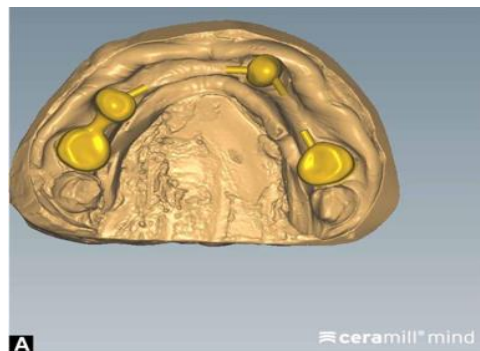


c)

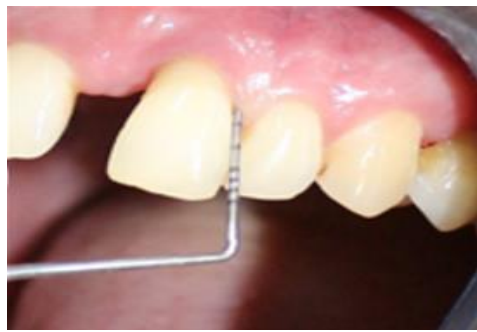

d)

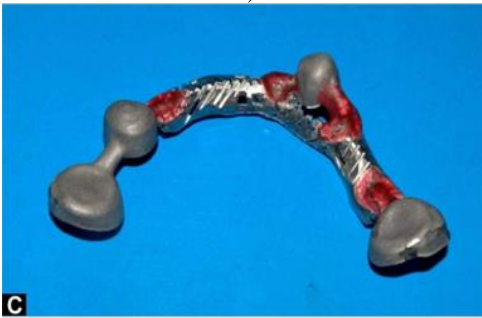**Figure 1.** a) Virtual model after laboratory scanning, b) Design of primary coping in 3D design software, c) Zirconia primary coping, d) Scanned cast after over impression along with zirconia coping a virtual cast for secondary coping and framework



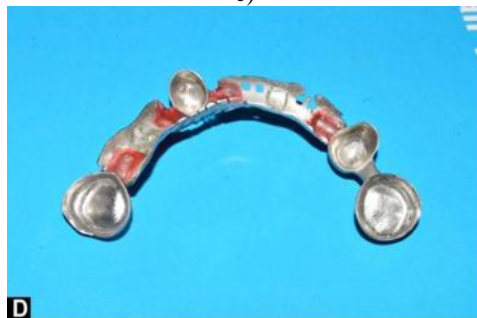a)



b)

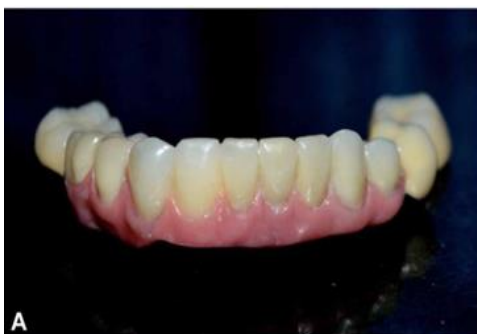

c)

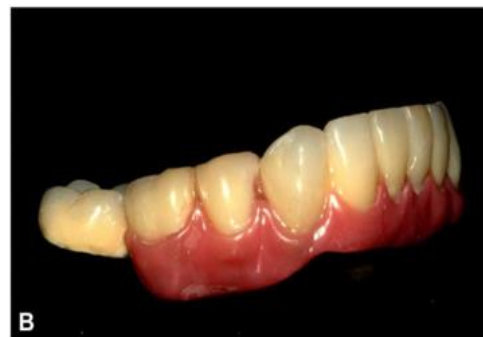

d)

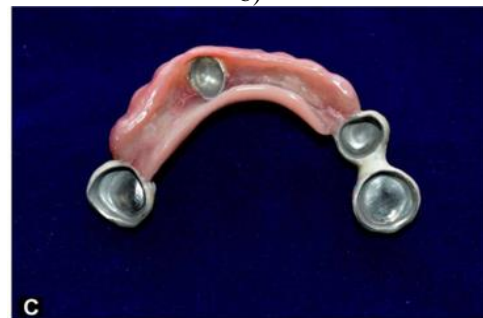**Figure 2.** a) secondary coping design with extension, b) cross section view of secondary coping on primary coping, c) DMLS metal framework and secondary coping (outer surface), d) Metal framework and secondary coping (inner surface)



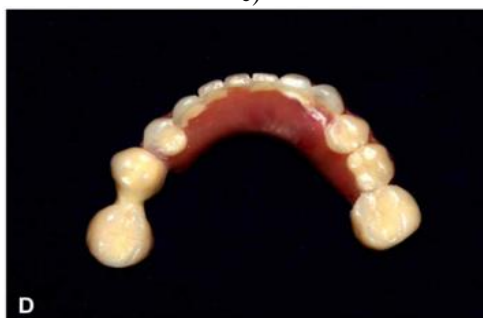a)



b)



c)



d)

**Figure 3.** Final prosthesis after layering with indirect composite, a) Frontal view, b) Lateral view, c) Intaglio surface, d) polished surface (occlusal view)

### Results and Discussion

In this case, due to knife edge ridge and low bone density extensive bone grafting for an implant-supported prosthesis was necessary, hence considering the duration and surgical morbidity it was not the treatment of choice. The telescopic denture was averted, because of their high-quality retentive and stabilizing properties, rigid splinting action, and superior distribution of stresses, also the advantages of telescopic dentures are, axial load on the tooth as they stimulate periodontal tissues and alveolar bone [3].

Çelik Güven *et al.* [4] analyzed wear of CrCo more when compared with zirconia when used as primary coping. Schwindling *et al.* [5] has done a randomized clinical trial where he investigated the clinical outcome of Zirconia as primary coping which was found to have a favorable survival rate and good outcomes. Also, Schwindling *et al.* [6] evaluated the effect of this type of Zirconia primary

coping on Oral Health-Related Quality of Life (OHRQoL) which were found to be improved as Zirconia do not outperform CoCr (cobalt chrome) alloy crowns regarding patient satisfaction tooth-like color. The indirect composite was layered in this case as it satisfies almost all qualities required for an anterior restorative material on metal, especially in implant malocclusion, telescopic denture, etc for shear bond strength, color stability, longevity, and also to avoid firing temperature which in turn alters the precision fit of the prosthesis [7-9].

Digitalization of the telescopic denture made this case highly precise with the help of digital surveying, virtual undercut Blockout, and accuracy of digital parallelism in CAD software. The use of a surveyor with a milling machine was eliminated by digital means, digital surveying and path of insertion was a major advantage of this case. The tilting of the tooth was easily managed by using single primary crowns which were assessed by the software for parallelism. Robotic primary crown design was selected which was having anatomical morphology with a defined finish line. After over impression of primary copings, the master cast was scanned and a minimum digital blockout was done to make the virtual duplicated cast.

### Conclusion

Elimination of manual errors through digitalization has changed the prosthesis outcome to an extraordinary level. The combination of zirconia milling and 3D printing of the metal results in prosthetic reconstruction of high quality, good fit, and patient satisfaction. The combination of modern technology and advanced material made the treatment outcome highly successful.

**Acknowledgments:** None

**Conflict of interest:** None

**Financial support:** None

**Ethics statement:** None

### References

1. Yalisove IL. Crown and sleeve-coping retainers for removable partial prosthesis. *J Prosthet Dent.* 1966;16(6):1069-85.
2. Wenz HJ, Lehmann KM. A telescopic crown concept for the restoration of the partially edentulous arch: the Marburg double crown system. *Int J Prosthodont.* 1998;11(6):541-50.
3. Langer Y, Langer A. Tooth-supported telescopic prostheses in compromised dentitions: a clinical report. *J Prosthet Dent.* 2000;84(2):129-32.
4. Çelik Güven M, Tuna M, Bozdağ E, Öztürk GN, Bayraktar G. Comparison of retention forces with various fabrication methods and materials in double crowns. *J Adv Prosthodont.* 2017;9(4):308-14.
5. Schwindling FS, Lehmann F, Terebesi S, Corcodel N, Zenthöfer A, Rammelsberg P, et al. Electroplated telescopic retainers with zirconia primary crowns: 3-year results from a randomized clinical trial. *Clin Oral Investig.* 2017;21(9):2653-60.
6. Schwindling FS, Deisenhofer UK, Séché AC, Lehmann F, Rammelsberg P, Stober T. Randomized trial investigating zirconia electroplated telescopic retainers: quality of life outcomes. *Clin Oral Investig.* 2017;21(4):1157-63.
7. Jones RM, Moore BK, Goodacre CJ, Munoz-Viveros CA. Microleakage and shear bond strength of resin and porcelain veneers bonded to cast alloys. *J Prosthet Dent.* 1991;65(2):221-8.
8. Jones RM, Goodacre CJ, Moore BK, Dykema RW. A comparison of the physical properties of four prosthetic veneering materials. *J Prosthet Dent.* 1989;61(1):38-44.
9. Ponnanna AA, Maiti S, Rai N, Jessy P. Three-dimensional-Printed Malo Bridge: Digital Fixed Prosthesis for the Partially Edentulous Maxilla. *Contemp Clin Dent.* 2021;12(4):451-3.