

# THE MORPHOLOGICAL DIFFERENCE BETWEEN MAXILLARY POSTERIOR TEETH IN SAUDI POPULATION

Ahmed Elhejazi<sup>1\*</sup>, Abdulrahman Ahmed Alanazi<sup>2</sup>, Khalid Alanazi<sup>2</sup>, Fahad Alqahtani<sup>2</sup>, Yousef Mohammed Shabi<sup>3</sup>, Abdulmajeed Ali Alqahtani<sup>4</sup>

<sup>1</sup> Department of Restorative Dental Sciences, College of Dentistry, King Saud University, Saudi Arabia, Riyadh. [aelhejazi@ksu.edu.sa](mailto:aelhejazi@ksu.edu.sa)

<sup>2</sup> College of Dentistry, King Saud University, Saudi Arabia, Riyadh.

<sup>3</sup> PSMC, Saudi Arabia, Riyadh.

<sup>4</sup> College of Dentistry, King Saud University, Saudi Arabia, Riyadh.

<https://doi.org/10.51847/YjFFWgFeI>

## ABSTRACT

We can avoid many complications before endodontic treatment by knowing the variation between maxillary right and left premolars and molars regarding canals, roots length, and roots numbers. The data collected and were compared between right and left maxillary premolar and molar teeth by using CBCT. All the maxillary first and second molars had three roots. The average root length of maxillary second right molar (meso buccal) was 13.19 mm, (Disto buccal) was 12.22 mm, and (palatal) was 13.13 mm. The average root length of maxillary second left molar MB was 13.12 mm, DB was 12.17 mm, and P was 13.90 mm. The average root length of the maxillary first right molar MB was 13.27 mm, DB was 12.37 mm, and P was 13.98 mm. The average root length of maxillary first left molar MB was 13.28 mm, DB was 12.43 mm, and P was 14.03 mm. There is no significant difference in length roots, root numbers, and canals number between the maxillary right and left premolars and molars.

**Key words:** Morphological Differences, Saudi Population, Comparing, CBCT, Root length, Canals number.

## Introduction

Recognizing the root canal anatomy and morphology is necessary for successful endodontic treatment for several reasons [1-3]. There are many variations in maxillary molars regarding canals number and configuration, knowing these variations will increase the success rate of the treatment [4]. One of the most important methods to examine these distinctions is radiograph interpretation [5]. Therefore, CBCT can be powerful endodontic diagnosis tool in teeth morphology assessment [6]. In the Saudi population, the plurality of upper second molars had 3 root canals while others had 4 root canals. Using CBCT, there are several studies regarding the number of roots and root canal configuration of upper second molars, but there is a lack of research on the similarity between right and left molars and premolars [7]. Using CBCT, a study on a Polish population showed all the right and left maxillary first molars had three roots. The majority of maxillary second molars had three roots [8]. A similar study in the Indian population found 3 separate roots in both the first and second molars [9]. In the Korean population, most of the first maxillary molars have 3 separate roots [10]. A study on the Chinese population about a second mesiobuccal canal shows that all maxillary first molars had 3 roots [11]. A study on the Thai population showed a second mesiobuccal canal in maxillary molars [12]. Research done in Saudi Population showed two roots and two-canal in maxillary first premolars [13]. A study on 100 samples Nepalese population about measurement and the average length of Maxillary First Premolar is shorter than the already established data [14]. Using CBCT, a study on the Saudi population showed the majority of upper first premolars' teeth had two roots while the upper second

premolars' teeth had one root [15].

## Materials and Methods

100 digitized CBCT scans depicting the maxillary arch Randomly selected from the Radiology Department, College of Dentistry, King Saud University (2016 to October 2020) was collected with consent that states, "Any images, radiographs, or test results obtained during treatment may be used for research and academic purposes, however, no personal information will be revealed". The Examiner was one dental intern by reading sagittal section for measuring length and number of Buccal roots (**Figures 1 and 2**), and an axial section for canals number (**Figure 4**) and a coronal section for measuring length and number of Palatal root (**Figure 3**) using the Planmeca Romexis Viewer software. The number and length of root canals of maxillary premolars and first and second molars were examined and compared to the other side of maxillary premolars and first and second molars. excluding criteria: any patient with missing teeth, pediatric patient, CBCT with unclear diagnostic images, teeth anomalies, and pathology such: (root resorption, open apex, dilaceration, etc.). including criteria: completed roots development. The root length was measured from the cementoenamel junction to the root apex. The data collected and were analyzed using SPSS software version 22.

## Results and Discussion

100 CBCT images of premolars molars and molars from 100 Saudi patients, in which 45% were female and 55% were male, were analyzed. Maxillary first and second molar The

maxillary first and second molars #16 #26 #17 #27 had (100%) three roots despite right or left. However, regarding maxillary second molars, 12% had four canals and 88% had three canals. Regarding maxillary first right molar #16, 25% had four canals and 75% had three canals. Regarding maxillary first left molar #26, 29% had four canals and 71% had three canals (**Table 1**). Length of roots of molars The average root length of maxillary second right molar #17 MB (meso buccal) was 13.19 mm (1.48), that of DB (Disto buccal) was 12.22 mm (1.34), and palatal was 13.13 mm (1.42). The average root length of maxillary second left molar #27 MB was 13.12 mm (1.42), DB was 12.17 mm (1.48), and P (palatal) was 13.90 mm (1.44). The average root length of the maxillary first right molar #16 MB was 13.27 mm (1.46), DB was 12.37 mm (1.32), and P was 13.98 mm (1.39). The average root length of maxillary first left molar #26 MB was 13.28 mm (1.37), DB was 12.43 mm (1.44), and P was 14.03 mm (1.39). Please check **Table 1**.

**Maxillary Premolars** Regarding the number of roots, for the maxillary second premolars #15, #25, 7% had 2 roots and 93% had 1 root. Regarding the maxillary first premolars #14 and #24, 39% had 2 roots and 61% had 1 root. Regarding the numbers of canals, for maxillary first right premolar #14, 83% had had two canals and 17% had 1 canal. Regarding maxillary first left premolar #24, 84% had two canals and 16% had 1 canal. Regarding maxillary second right premolar #15, 45% had two canals and 55% had 1 canal. Regarding maxillary second left premolar #25, 40% had two canals and 60% had 1 canal. Root length of premolars The average root length of maxillary first right premolar #14 was B(buccal) 14.27 mm (1.51) and P (Palatal) was 13.30 mm (1.47). The average root length of maxillary first left premolar #24 B was 14.08 mm (1.51) and P was 13.42 mm (1.50). The average root length of maxillary second right premolar #15 B was 14.57 (1.46) mm and P was 14.64 mm (0.84). The average root length of maxillary second left premolar #25 B was 14.52 mm (1.39) and P was 14.36 mm (0.75). Please check **Table 2**. There was no significant difference in the number of roots of the maxillary first and second molars #16 #26 #17 #27 ( $P > 0.05$ ). There was no significant difference in the number of roots of the maxillary first premolar #14 and #24; 39% had 2 roots and 61% had 1 root. Regarding #15 and #25, 7% had 2 roots and 93% had 1 root. There was no significant difference (at  $P < 0.05$ ) in the number of roots of the maxillary second premolar. There was no significant difference between the average length of MB root of #17 (13.19mm) and #27 (13.12mm) respectively. There was no significant difference between the average length of DB root of #17 (12.22mm) and #27 (12.17mm) respectively. There was no significant difference between the average length of P root of #17 (13.13mm) and #27 (13.90mm) respectively. There was no significant difference between the average length of MB root of #16 (13.27mm) and #26 (13.28mm) respectively. There was no significant difference between the average length of DB root of #16 (12.37mm) and #26 (12.43mm) respectively. There was no significant difference between the average length of P root of #16 (13.98mm) and #26 (14.03mm) respectively.

There was no significant difference between the average length of B root of #15 (14.57mm) and #25 (14.52mm) respectively. There was no significant difference between the average length of P root of #15 (14.64mm) and #25 (14.36mm) respectively. There was no significant difference between the average length of B root of #14 (14.27mm) and #24 (14.08mm) respectively. There was no significant difference between the average length of P root of #14 (13.30mm) and #24 (13.42mm) respectively.

In our study, we found that 88% of maxillary second molar has 3 root canals and 12% has 4 root canals. It was found in Hadi M. Alamri *et al.*, 74.4% maxillary second molar has 3 root canals and 19.4% has 4 root canals [7]. Our results show that the first molar had three roots (100%), which is consistent with Katarzyna Olczak *et al.* Our study also shows that the upper second molar had (100%) three roots, while in Katarzyna Olczak *et al.*, it was seen that the majority showed maxillary second molars with three roots (91.8%), 5.8% had two roots and 2.4% had one root. Our results showed a great inconsistency to Katarzyna Olczak *et al.* regarding the canals' number of maxillary first molars, as 59.5% had four root canals and 40.5% had three root canals. The upper second molar showed a similarity to the results in Katarzyna Olczak *et al.*, where 70% had three root canals. Whereas in other maxillary second molars, 23.2% had four canals [8]. Prasanna Neelakantan *et al.*'s study showed a similar number of roots to our results for both the first (96.8%) and second molars (93.1%), which had had 3 roots [9]. Kim Y, Lee S J, Woo J *et al.* In the Korean population for 97.91%, the first maxillary molars have 3 separate roots. In the Korean population, bilateral symmetry of the MB roots was found in 88.10% of the first molars and 82.07% of the second molars. In our study, we found bilateral symmetry in 84% of the first molars and 100% of the second molars [10]. In our study, we found that 29% of maxillary first molars had second mesiobuccal. Zhang *et al.*'s study on a Chinese population found that a second mesiobuccal canal was found in 52% of the patients, and all maxillary first molars had 3 roots [12]. Alavi *et al.*'s study on the Thai population shows that the mesiobuccal roots of the first (65%) and second (55%) molars had two canals [13]. In our study, we found that for #14, 17% had one canal, for #24, 16% had one canal, for #14, 83% had two canals, and for #24, 84% had two canals. These results can be compared with a study done on the Saudi population, which shows that 8.9% had one canal and 89.8% had two canals [14]. In our study, we found that regarding the root of maxillary first premolar, single root forms for 61% whereas double root forms for 39%, and the mean root length was 14.27 mm ( $\pm 1.5$ ) in buccal root and 13.30mm ( $\pm 1.5$ ) in the palatal root. In a study done on root length of maxillary first premolar in the Nepalese population, it was found that 58% have a single root whereas 20% have double root, and the mean root length was found to be 12.76 mm ( $\pm 1.65$ ) [14]. [15]. In our study showed the root number of maxillary first premolar does not consistent with Alqedairi A, *et al.*'s study which is the most teeth had two roots (75.1%), while our

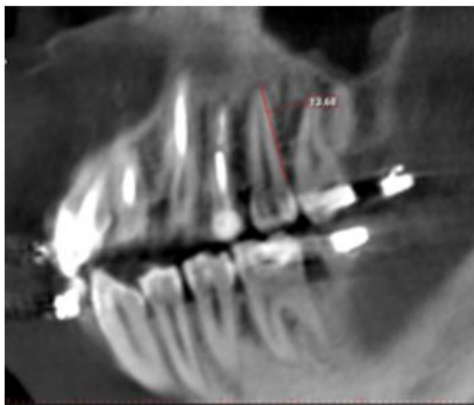
results showed similarity in maxillary second premolars which is (85.2%) single-rooted [15].

**Table 1.** maxillary comparing between right and left molars

	#17			#27			#16			#26		
Root number	3Roots (100%)			3Roots (100%)			3Roots (100%)			3Roots (100%)		
Canal number	4 canals (12%)	3 canals (88%)		4 canals (12%)	3 canals (88%)		4 canals (25%)	3 canals (75%)		4 canals (29%)	3 canals (71%)	
Average root length	<b>MB</b>	<b>DB</b>	<b>P</b>	<b>MB</b>	<b>DB</b>	<b>P</b>	<b>MB</b>	<b>DB</b>	<b>P</b>	<b>MB</b>	<b>DB</b>	<b>P</b>
	13.19	12.22	13.13	13.12	12.17	13.90	13.27	12.37	13.98	13.28	12.43	14.03

**Table 2.** maxillary comparing between right and left premolars

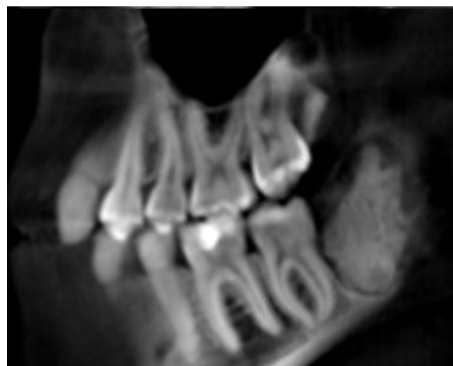	#15		#25		#14		#24	
Root number	2roots (7%)	1 root (93%)	2roots (7%)	1root (93%)	2roots (93%)	1root (61%)	2roots (93%)	1 root (61%)
Canal number	2 canals (45%)	1 canal (55%)	2 canals (40%)	1 canal (60%)	2 canals (83%)	1 canals (17%)	2 canals (84%)	1 canal (16%)
Avreag Root length	<b>B</b>	<b>P</b>	<b>B</b>	<b>P</b>	<b>B</b>	<b>P</b>	<b>B</b>	<b>P</b>
	14.57 (100%)	16.64 (7%)	14.52 (100%)	14.36 (7%)	14.27 (100%)	13.30 (39%)	14.08 (100%)	13.24 (39%)



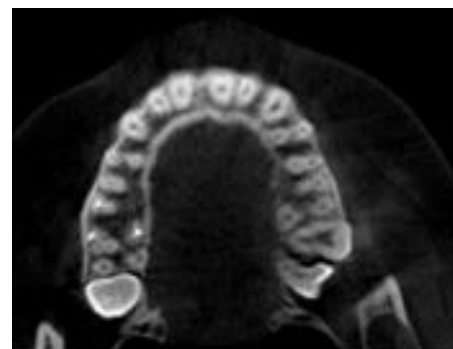
**Figure 1.** Root length of the left second premolar



**Figure 3.** Palatal root length of the maxillary right second molar



**Figure 2.** Root length of maxillary left first molar



**Figure 4.** Canals number of left side premolars

**Conclusion**

There was no significant difference in the number of roots and roots length of the left and right maxillary molars and

premolars in the Saudi sub-population within the study's limitations.

**Acknowledgments:** The authors give many thanks to the College of Dentistry Research Center, King Saud University, for supporting and conducting this project (CDRC no. IR 0373, IRB Research Project no. E-20-5402).

**Conflict of interest:** None

**Financial support:** None

**Ethics statement:** None

## References

1. Ng YL, Aung TH, Alavi A, Gulabivala K. Root and canal morphology of Burmese maxillary molars. *Int Endod J.* 2001;34(8):620-30.
2. Hamed MT, Mously HA. Investigating Economic and Clinical Implications of Tooth Implant Supported Prosthesis among Patients and Practitioners. *Int J Pharm Res Allied Sci.* 2019;8(4):116-21.
3. Asgari I, Soltani S, Sadeghi SM. Effects of Iron Products on Decay, Tooth Microhardness, and Dental Discoloration: A Systematic Review. *Arch Pharm Pract.* 2020;11(1):60-82.
4. Badole GP, Bahadure RN, Warhadpande MM, Kubde R. A rare root canal configuration of maxillary second molar: a case report. *Case Rep Dent.* 2012;2012:767582. doi: 10.1155/2012/767582.
5. Eskoz N, Weine FS. Canal configuration of the mesiobuccal root of the maxillary second molar. *J Endod.* 1995;21(1):38-42.
6. Patel S, Durack C, Abella F, Shemesh H, Roig M, Lemberg K. Cone beam computed tomography in endodontics—a review. *Int Endod J.* 2015;48(1):3-15.
7. Alamri HM, Mirza MB, Riyahi AM, Alharbi F, Aljarbou F. Root canal morphology of maxillary second molars in a Saudi sub-population: A cone beam computed tomography study. *Saudi Dent J.* 2020;32(5):250-4.
8. Olczak K, Pawlicka H. The morphology of maxillary first and second molars analyzed by cone-beam computed tomography in a polish population. *BMC Med Imaging.* 2017;17(1):68.
9. Neelakantan P, Subbarao C, Ahuja R, Subbarao CV, Gutmann JL. Cone-beam computed tomography study of root and canal morphology of maxillary first and second molars in an Indian population. *J Endod.* 2010;36(10):1622-7.
10. Kim Y, Lee SJ, Woo J. Morphology of maxillary first and second molars analyzed by cone-beam computed tomography in a Korean population: variations in the number of roots and canals and the incidence of fusion. *J Endod.* 2012;38(8):1063-8.
11. Zhang R, Yang H, Yu X, Wang H, Hu T, Dummer PM. Use of CBCT to identify the morphology of maxillary permanent molar teeth in a Chinese subpopulation. *Int Endod J.* 2011;44(2):162-9.
12. Alavi AM, Opananon A, Ng YL, Gulabivala K. Root and canal morphology of Thai maxillary molars. *Int Endod J.* 2002;35(5):478-85.
13. Atieh MA. Root and canal morphology of maxillary first premolars in a Saudi population. *J Contemp Dent Pract.* 2008;9(1):46-53.
14. Dashrath K, Nisha A, Subodh S. Root Morphology and Tooth Length of Maxillary First Premolar in Nepalese Population Kafle Dashrath, Acharya Nisha and Sthapit Subodh. 2015;5:8.
15. Alqedairi A, Alfawaz H, Al-Dahman Y, Alnassar F, Al-Jebaly A, Alsubait S. Cone-beam computed tomographic evaluation of root canal morphology of maxillary premolars in a Saudi population. *BioMed Res Int.* 2018;2018:8170620.